



Involvement of Adenomyosis in Refractory Abnormal Uterine Bleeding-Ovulatory Dysfunction: A Case Series

Gui T¹, Deng S^{1*}, He Y² and Xue H²

¹Department of Obstetrics and Gynecology, Peking Union Medical College Hospital, Chinese Academy of Medical Sciences, National Clinical Research Center for Obstetrical and Gynecological Diseases, Beijing, China

²Department of Radiology, Peking Union Medical College Hospital, Chinese Academy of Medical Sciences, Beijing, China

Abstract

Objective: To report six cases of refractory AUB-Ovulatory Dysfunction (AUB-O) diagnosed with adenomyosis and to emphasize the clinical significance of adenomyosis in AUB.

Methods: This was a retrospective study conducted at the Peking Union Medical College Hospital. Between September 2016 and July 2018, six patients with refractory AUB-O were admitted. Refractory AUB was defined as insensitivity to hormone therapy after exclusion of endometrial malignancy. Ultrasound, curettage, and pelvic Magnetic Resonance Imaging (MRI) were performed.

Results: According to MRI, the six patients with AUB-O were classified into either asymmetrical internal adenomyosis or symmetrical internal adenomyosis. In the first group, a diagnosis of adenomyosis was made by ultrasonic images of thickened uterine walls with palisade echoes. MRI further revealed alveolate foci oppressing the endometrium and protruding into the uterine cavity ("Swiss cheese" signs). In the second group, ultrasound and pathological examination did not provide positive findings after hysteroscopy, while MRI presented diffuse thickening of the junctional zone over 50% of the thickness of the myometrium, and the diagnosis of adenomyosis was then established. In these cases, GnRHa was the only guaranteed drug to control acute vaginal bleeding.

Conclusion: When routine medications are ineffective in the treatment of AUB-O, adenomyosis is most likely the underlying reason, even for patients without dysmenorrhea. Given that adenomyosis has different subtypes, MRI is an optimal method to make a diagnosis and to guide individual treatment, especially for cases in the early stages.

Keywords: Refractory; Abnormal uterine bleeding; Ovulation dysfunction; Adenomyosis; Ultrasound; MRI

Introduction

Abnormal Uterine Bleeding (AUB) in non-pregnant women of reproductive age is the acute or chronic variation from the normal menstrual cycle, including changes in volume, regularity, duration, and/or frequency of bleeding [1-4]. AUB affects 9% to 14% of women of reproductive age [3]. The PALM-COEIN classification system proposed by the International Federation of Gynecology and Obstetrics (FIGO) in 2011 is universally accepted to help clinicians and investigators in the evaluation, diagnosis, and management of AUB in non-pregnant women of reproductive age [1,5]. Structural causes include Polyp (AUB-P), Adenomyosis (AUB-A), Leiomyoma (AUB-L), and Malignancy (AUB-M) [6,7].

Adenomyosis a gynecologic condition characterized by the abnormal presence of endometrial tissue within the myometrium and is a structural cause of AUB [1,2,8]. Patients with adenomyosis often present with Heavy Menstrual Bleeding (HMB) and dysmenorrhea. Sammour et al. [9] reported that menorrhagia and dysmenorrhea were found in 63% and 40% of patients with adenomyosis, respectively. Nevertheless, in the presence of coexisting lesion such as uterine fibroids and/or polyps, the causal effect of adenomyosis in AUB is difficult to prove. Nevertheless, the conservative pharmacological therapy for AUB-A is usually similar to that for AUB-O [10].

Treatments aim at managing symptoms and preserving or improving fertility. After preliminary assessment, the first-line treatment for patients with AUB caused by ovulation dysfunction (AUB-O)

OPEN ACCESS

*Correspondence:

Deng S, Department of Obstetrics and Gynecology, Peking Union Medical College Hospital, Chinese Academy of Medical Sciences, National Clinical Research Center for Obstetrical and Gynecological Diseases, Beijing, China,

E-mail: ds_dengshan@163.com

Received Date: 22 Mar 2021

Accepted Date: 15 Apr 2021

Published Date: 30 Apr 2021

Citation:

Gui T, Deng S, He Y, Xue H. Involvement of Adenomyosis in Refractory Abnormal Uterine Bleeding-Ovulatory Dysfunction: A Case Series. Clin Surg. 2021; 6: 3154.

Copyright © 2021 Deng S. This is an open access article distributed under the Creative Commons Attribution License, which permits unrestricted use, distribution, and reproduction in any medium, provided the original work is properly cited.

Table 1: Clinical information of 6 patients with refractory AUB.

Group	No.	Age	Years of AUB-O	Hb (g/l)	Medical treatment	Ultrasound	MRI	Surgery
Group 1- asymmetrical intrinsic adenomyosis	1	41	6	50	Menstruation was regular during medication with COCs or progestins, but period still lasted for 7-14 days with HMB. Even with LNG-IUS, monthly bleeding like normal menstruation continued till 6 months. Fortunately, anemia has improved.	thickening of uterine walls (1.7/3.9 cm), and thickening of endometrium 2.3 cm	Thickening of junctional zone 1.2 cm, thickening of posterior uterine wall, Swiss Cheese Sign	D&C (-)
	2	34	4	51	Multiple-dose COCs could control the irregular vaginal bleeding, but breakthrough bleeding recurred when the drug dose reduced to one pill per day. Now the patient is receiving the treatment of GnRHa.	thickening of uterine walls (2.3/2.4 cm)	thickening of junctional zone, partially protruding into the uterine cavity, Swiss Cheese sign possibly	D&C (-)
	3	39	0.5	78	GnRHa is the only guaranteed drug to control her vaginal bleeding COCs and Norplant were both ineffective. LNG-IUS shed out along with persistent heavy bleeding for the first time. Hysteroscopic lesion resection. followed by second insertion of LNG-IUS achieved preliminary effect, uterine bleeding stopped by six months later	thickening of uterine walls (1.4/4.2 cm)	thickening of junctional zone	D&C (-) Hys: partial resection of AM
Group 2- symmetrical intrinsic adenomyosis	4	41	1	80	COCs and norethindrone (15 mg/d) could not control the irregular bleeding, until the use of GnRHa for 2 cycles. Now the patient is treated by the LNG-IUS.	thickening of endometrium 1.7 cm with echo heterogeneity	thickening of junctional zone over 1/2 myometrium	D&C (-) Hys: polypoid hyperplasia
	5	53	1	65	Medroxyprogesterone (40 mg/d) could not control the irregular vaginal bleeding. A laparoscopic hysterectomy was performed after hemostasis with GnRHa.	thickening of endometrium 1.1 cm to 1.5 cm with echo heterogeneity, and intra-uterine occupation 3 cm x 2 cm	thickening of junctional zone about 3cm	D&C (-) LH after clarification of AM
	6	49	1	88	Medroxyprogesterone (40 mg/d) could not control the irregular vaginal bleeding. Now the patient is receiving the treatment of GnRHa.	thickening of endometrium 2.5 cm with echo heterogeneity, and intra-uterine occupation 1.2 cm x 0.8 cm	thickening of junctional zone and signal heterogeneity of myometrium	D&C (-)

is multi-dose oral contraceptives or high-dose progestogens [11-13]. Non-hormonal therapy, suitable for women who wish to conceive or avoid hormonal side effects, includes anti-fibrinolytics and non-steroidal anti-inflammatory drugs and can reduce menstrual blood by up to 50% [8]. Oral or injection progestogens/progestins may be used to stop acute heavy bleeding, to manage irregular bleeding, or to control the timing of the onset of menstruation, although side effects may limit longer term use [8]. The Levonorgestrel releasing Intrauterine System (LNG-IUS) has been reported to be more effective than other first-line medical options in reducing the impact of heavy menstrual bleeding on quality of life [8]. Gonadotrophin Releasing Hormone analogs (GnRHa) are known to induce amenorrhea in up to 90% of women, but side effects may significantly affect the quality of life, and clinical use is usually limited to 6 months. Surgical intervention is indicated when the pharmacological therapy is unsatisfactory [14,15]. Hysteroscopy and histopathological diagnosis are necessary to exclude structural causes [6,7]. In fact, there are occasional cases of refractory AUB to medical treatments. Unexplained AUB may be persistent after Dilation and Curettage (D&C). It is therefore imperative to further explore the underlying reason, since adenomyosis as an underlying causing factor may be underestimated or even ignored.

Therefore, the aim of the present study was to review and analyze the medical history of six patients with AUB-O, whose common characteristic was resistance to medical treatment of adequate dose. Aside ultrasound and hysteroscopic evaluation or D&C, we performed pelvic Magnetic Resonance Imaging (MRI) in order to explore for pathological clues.

Materials and Methods

Study design

This was a retrospective study conducted at the Peking Union Medical College Hospital (PUMCH). The study was approved by the ethics committee of PUMCH. Since all data were de identified, written informed consent was not necessary due to the retrospective nature of the study.

Patients

Between September 2016 and July 2018, six patients with refractory AUB-O were admitted to the Department of Obstetrics and Gynecology of PUMCH. The patients all presented a combination of unpredictable timing of bleeding and variable amount of blood flow that resulted in HMB and anemia, with an average hemoglobin level of 70 g/l, ranging from 45 g/l to 109 g/l. Refractory AUB was defined as insensitivity to hormone therapy after exclusion of endometrial malignancy [2,8].

Data collection

Patient data, including age of onset, chief complaint, clinical features, imaging findings, treatment modality, and clinical outcome, were collected from the medical records and clinical database (Table 1).

Ultrasound

Transvaginal ultrasound was performed using color Doppler ultrasound diagnosis systems and a 5 MHz to 9 MHz transvaginal probe (iU22, Philips, Best, The Netherlands; Logiq 9, GE Healthcare, Waukesha, WI, USA) by experienced ultrasound radiologists.

Ultrasound characteristics, including the size of the uterus, the thickness of the endometrium, anterior and posterior walls, and whether there were cystic spaces or heterogeneous zones in the myometrium, were detected in the sagittal and transverse planes. MRI was performed by radiologists.

Magnetic resonance imaging

Who were experienced in gynecology and using 3T scanners (Sigma, GE Healthcare, Waukesha, WI, USA; Ingenia 3.0T CX; Philips, Best, the Netherlands). As per routine practice, 4-mm slices with 1-mm spacing were acquired in the sagittal, coronal, and axial planes relative to the orientation of the body using T2-weighted fast (turbo) spin echo sequences (TR/TE, 3500 to 4000 ms/90 ms, echo train length 16) in all three planes. Phase array pelvic coils were used for data acquisition. The examination was completed in 20 min. Junctional zone thickness >12 mm and high-signal spots seen in the myometrium indicated adenomyosis [16-18].

Classification method

The MRI classification of adenomyosis suggested by Bazot was used for reference [19]. This classification is based on the morphology and location of adenomyosis; the two subtypes are mainly internal adenomyosis and external adenomyosis. According to MRI, the six patients were all diagnosed with internal adenomyosis. They were further classified into two groups: Asymmetrical internal adenomyosis and symmetrical internal adenomyosis.

Statistical analysis

Only descriptive statistics were used.

Results

According to the imaging characteristics of MRI, the six patients were classified into two groups: Asymmetrical internal adenomyosis group and symmetrical internal adenomyosis group.

In the first group, the three patients were complaining of an irregular menstrual cycle and HMB. They all received medical treatment with oral contraceptives and progestins in the early stage. The common characteristic was resistance to single-dose COCs. Only a multidose strategy (≥ 3 tablets each day) could control the bleeding temporarily, but irregular bleeding recurred once the drugs were reduced to a single dose. GnRH α was prescribed to all three patients because of moderate-to-severe anemia due to refractory bleeding. Ultrasound in all three patients suggested adenomyosis given the image of myometrial wall thickness with palisade echoes, but the initial diagnosis was not adenomyosis. Patients #1 (Figure 1a, 1e) and #2 (Figure 1b, 1f) had the “Swiss-cheese sign”, indicating the presence of a large area of endometrium folded inward. Even after insertion of the levonorgestrel intrauterine system (LNG-IUS, Mirena), periodic bleeding resembling normal menstruation lasted for nearly one year in patient #1. Given her reluctance to have her uterus removed, she was satisfied with the current situation. Specifically, patient #3 tried to use the LNG-IUS and Norplant implantation, but the LNG-IUS eventually shed out with persistent heavy bleeding, and the Norplant implantation also failed to stop the uterine bleeding. The patient’s condition of adenomyosis was well-known according to her medical history, since multiple ultrasound examination indicated echo heterogeneity of the myometrium as well as thickening of both the anterior and posterior walls of uterus (1.4 cm and 4.2 cm, respectively). In addition, recent MRI imaging revealed for the first time that the junctional zone of the uterus was obscure, and that an

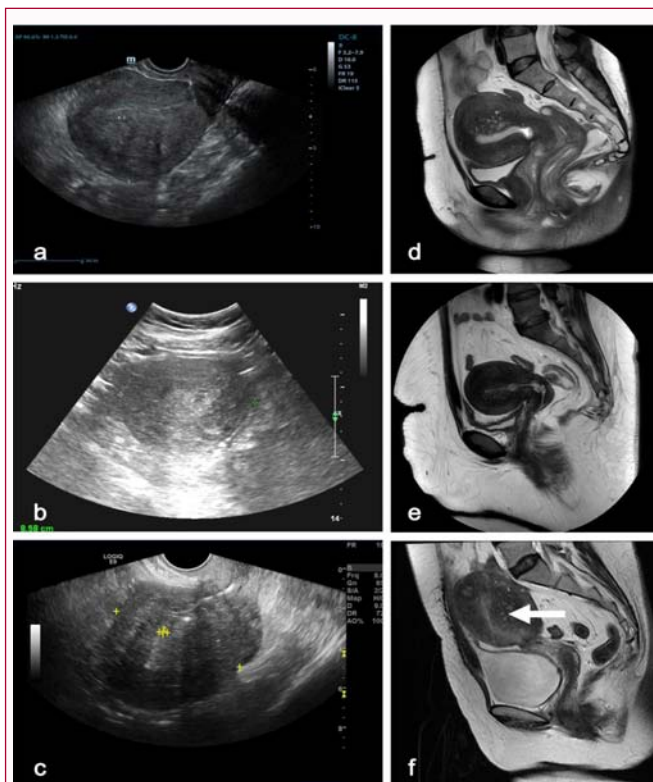


Figure 1: Ultrasound and MRI images for asymmetrical intrinsic adenomyosis in refractory abnormal uterine bleeding.

(a-c) Ultrasound images from three patients (#1-3) suggesting enlargement of the uterus at different degrees, thickening of the uterine wall, and echo heterogeneity of the myometrium layer. Sagittal T2-weighted MRI images providing more detailed information. (d) Patient #1: Thickening of the junctional zone in the posterior wall of the uterus, with an alveolate focus protruding into the cavity. (e) Patients #2: Thickening of both the anterior and posterior walls of the uterus, with alveolate foci pressing on the endometrium layer. (f) Patient #3: A focus-like adenomyoma in the posterior wall of the uterus causing deformity of the uterine cavity. The white arrows indicate the “Swiss cheese” sign.

adenomyoma protruded from the posterior wall of the uterus into the uterine cavity (Figure 1c, 1g). LNG-IUS was successfully placed after hysteroscopic resection of the protruding lesion in the uterine cavity. Although the location of the IUS later declined to the lower part of the uterine cavity, the bleeding symptoms have been controlled up to now. The drawback was that irregular spotting has been ongoing for up to a year. We classified this type as “asymmetrical internal adenomyosis” according to the infiltration degree in myometrium in the anterior, posterior, or lateral walls of the uterus.

In the second group, the three patients also complained of an irregular menstrual cycle and HMB and took multidose oral contraceptives or progestins. Nonetheless, AUB could not be effectively controlled until GnRH α or LNG-IUS was used. The common ultrasound feature was thickening of the endometrium, but no positive pathological findings were observed even after D&C assisted by hysteroscope. Additional MRI showed thickening of the junctional zone over 50% of the myometrium layer, indicating that adenomyosis played a role in causing the persistent vaginal bleeding. It is worth mentioning that patient #5 finally received hysterectomy because she was 53 years old, which was different from the other two patients (Figure 2). Hysterectomy was performed and gross pathological examination confirmed the diagnosis of adenomyosis

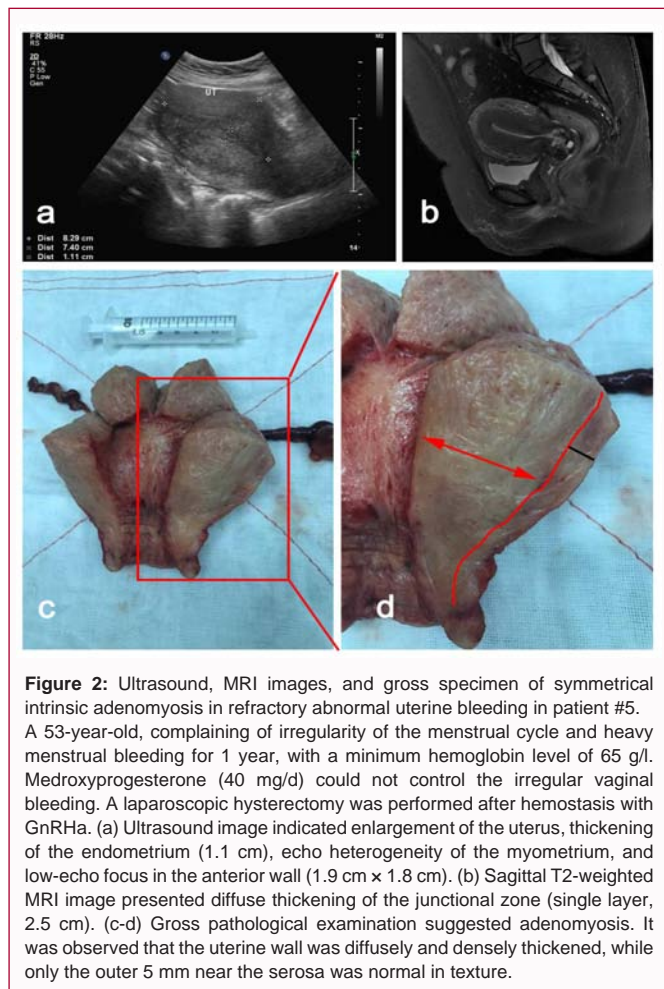


Figure 2: Ultrasound, MRI images, and gross specimen of symmetrical intrinsic adenomyosis in refractory abnormal uterine bleeding in patient #5. A 53-year-old, complaining of irregularity of the menstrual cycle and heavy menstrual bleeding for 1 year, with a minimum hemoglobin level of 65 g/l. Medroxyprogesterone (40 mg/d) could not control the irregular vaginal bleeding. A laparoscopic hysterectomy was performed after hemostasis with GnRH α . (a) Ultrasound image indicated enlargement of the uterus, thickening of the endometrium (1.1 cm), echo heterogeneity of the myometrium, and low-echo focus in the anterior wall (1.9 cm \times 1.8 cm). (b) Sagittal T2-weighted MRI image presented diffuse thickening of the junctional zone (single layer, 2.5 cm). (c-d) Gross pathological examination suggested adenomyosis. It was observed that the uterine wall was diffusely and densely thickened, while only the outer 5 mm near the serosa was normal in texture.

with diffuse and dense thickening of the myometrium. We classified this type as “symmetrical internal adenomyosis” according to the infiltration degree in myometrium in the anterior, posterior, or lateral walls of the uterus.

Discussion

Some patients with AUB are refractory to medical treatment. Adenomyosis could be involved in those cases. Therefore, the aim of the present study was to report six cases of refractory AUB-O diagnosed with adenomyosis and to emphasize the clinical significance of adenomyosis in AUB. The results suggest that routine medications are ineffective in the treatment of AUB-O. Adenomyosis is most likely the underlying reason, even for patients without dysmenorrhea. Given that adenomyosis has different subtypes, MRI is an optimal method to make a diagnosis and guide individual treatment, especially for cases in the early stages.

It is well-known that dysmenorrhea is the main clinical feature of adenomyosis. Nevertheless, the role of adenomyosis in AUB with no pain is usually neglected or underestimated. According to our experience, dysmenorrhea is not an indispensable “signature symptom” of adenomyosis, and adenomyosis is an important contributor to AUB refractory to routine medications. The complex pathogenesis and manifestation of adenomyosis make it one of the most difficult AUB types to diagnose and treat according to the FIGO PALM-COEN system [1]. The incidence of adenomyosis as an isolated pathology is not clear. Approximately 30% patients with

adenomyosis are asymptomatic, and the incidence of dysmenorrhea has been reported to be 50% to 93.4% [11,17,20,21]. Meanwhile, in the absence of concomitant pathology, adenomyosis could cause AUB in 27% to 65% of patients [11,17,20,21]. For patients with HMB that is significant enough to cause anemia, adenomyosis should be given particular attention, especially in nulliparous women [9].

Adenomyosis varies widely in the extent and location of its invasion within the uterus [20,22]. Although noninvasive diagnosis methods such as transvaginal ultrasound and MRI are recognized as being highly accurate, histological examination remains the gold standard for diagnosis [23]. Nevertheless, noninvasive imaging techniques such as TVUS and MRI can both be used to strongly suggest the diagnosis of adenomyosis, guide treatment options, and monitor the responses to treatment [21,24]. By virtue of its ability to objectively differentiate between different types of soft tissue, MRI provides slightly better diagnostic capability compared to TVUS [19,25]. Our experience confirmed that MRI could provide more specific details about important parameters to be included in the classification system of adenomyosis, such as the affected area (inner or outer myometrium), localization (anterior or posterior or fundus), pattern (diffuse or focal), type (muscular or cystic), and volume or size, in the form of objective images from different angles, especially for the symmetrical internal subtype [25]. This is very helpful in making clinical decisions of management.

There has been a call for a classification system for adenomyosis to assist clinicians in making a diagnosis and for planning management [16]. While there are several proposed classification systems, none have been universally adopted. This is problematic at both clinical and research levels. Comprehensively, there are mainly two forms of adenomyosis: diffuse and focal [17,26-29]. For the diffuse type, extensive disease with endometrial mucosa includes glands and stroma scattered throughout the uterine muscular layer. For the focal type, also named adenomyoma, a hypertrophic and distorted endometrium is found in the myometrium with a circumscribed mass. Unusual types of adenomyosis include adenomyotic polyp, adenomyotic cyst, and Swiss cheese appearance of adenomyosis [18]. In recent years, the classification strategy based on MRI features (internal, external and intramural adenomyosis subtypes), which was first proposed by Kishi et al. in 2012 [27], has received increasing attention. The classification system further refined by Bazot et al. has the greatest potential to help make a therapeutic strategy and reflect the pathogenesis of adenomyosis [19,25]. Internal adenomyosis develops in direct connection to the thickened junctional zone and healthy myometrium is preserved outside the adenomyosis. External adenomyosis is located in the outer shell of the uterus, the junctional zone is kept intact without aberrancy, and healthy muscular structures are preserved in between the adenomyosis and the junctional zone. Among them, internal adenomyosis comprised focal or multifocal, superficial asymmetric or symmetric, and diffuse asymmetric or symmetric subtypes. Our initial clinical impression was that the internal subtype presented more severe bleeding, while the external subtype presented more serious dysmenorrhea. In addition, focal, superficial and symmetric lesions, namely, internal adenomyosis of an early stage are not easily detected by transvaginal ultrasound.

In our second series, adenomyosis was neglected mostly because the patients did not complain of dysmenorrhea, although ultrasound suggested thickening of the endometrium, but MRI examination provided more information. For mild internal adenomyosis (focal or superficial lesion), ultrasound is presumed to be less sensitive than

MRI. In terms of ultrasound features of adenomyosis, asymmetrical myometrial thickening, myometrial cysts, linear striations, and hyperechoic islands are common signs. Nevertheless, the “irregular and thickened endometrial-myometrial junction zone” on either 2D or 3D imaging, which corresponds to the junction zone in MRI, seems to be less reliable and inevitably depends on the performance of the MRI system as well as on the experience of the physicians, though a new scoring system for uterine adenomyosis was published recently [30]. For adenomyosis, where the uterine volume is not significantly enlarged and only the superficial muscle layer is involved, ultrasound tends to miss the diagnosis of adenomyosis.

For three other patients, although the ultrasound examinations provided a diagnosis of adenomyosis given the thickening of both anterior and posterior walls of the uterus with palisade echoes, MRI helped in clarifying the classification as internal adenomyosis with characteristic features of “Swiss cheese” and submucosal adenomyoma, respectively. This imaging information is very helpful for analyzing the cause of drug resistance and formulating the subsequent treatment plan.

In view of the above analysis, transvaginal ultrasound is the first-line imaging technique currently used for the noninvasive diagnosis of adenomyosis. Although adenomyosis may be successfully managed in many patients, some patients still have symptoms. Therefore, MRI may be needed for proper patient management.

For patients with refractory AUB due to adenomyosis and without fertility requirements, hysterectomy is the most cost-effective treatment, as shown with patient #5 and #6 in the present study [4,31]. For patients unwilling to lose their uterus, GnRHa followed by LNG-IUS insertion may be the most promising strategy [32,33]. Meanwhile, physicians have to foresee the possibility of prolonged breakthrough bleeding during IUS on-site, as demonstrated by patient's #1-4 in the present study. If the lesions invade the uterine cavity, appropriate hysteroscopic surgery may improve the prognosis of IUS therapy, which was shown in patient #3 [34]. On the other hand, there is still a lack of experience regarding patients with fertility requirements. Nevertheless, MRI is essential to make an early diagnosis and classification. On the other hand, for simultaneous AUB-O, conscious and comprehensive interventions, including lifestyle and body weight control combined with drug therapy, have the potential to ultimately improve reproductive prognosis.

This study has limitations. As a retrospective analysis on a series of very specific patients, this study was limited by a small sample size. In addition, available data were limited to those available in the charts. Nevertheless, the whole process of clinical treatment and follow-up allowed us to accumulate more experience, which we think should be shared with our colleagues. These cases could be the beginning of a study that investigates how MRI plays a role in the diagnosis and sub-classification of adenomyosis in AUB, and how this can aid in treatment decision-making and improve outcomes.

Conclusion

The present study suggests that when routine medical treatment is ineffective in the treatment of AUB-O and that endometrial malignancy is excluded, adenomyosis is most likely the underlying cause of AUB, even for patients who do not complain of dysmenorrhea. Given that adenomyosis has different phenotypes, transvaginal ultrasound is the first-line imaging technique, but MRI can facilitate clinical decision making in patients with early stage or atypical cases.

Author Contributions

Gui T: data curation, formal analysis, investigation, methodology, writing-original draft preparation; Deng S: conceptualization, investigation, methodology, project administration, supervision; He Y: data curation, resources; Xue H: data curation, resources.

References

- Munro MG, Critchley HO, Broder MS; FIGO Working group on menstrual disorders. FIGO classification system (PALM-COEN) for causes of abnormal uterine bleeding in nonpregnant women of reproductive age. *Int J Gynaecol Obstet.* 2011;113(1):3-13.
- Singh S, Best C, Dunn S, Leyland N, Wolfman WL. No. 292-abnormal uterine bleeding in pre-menopausal women. *J Obstet Gynaecol Can.* 2018;40(5):e391-415.
- Sweet MG, Schmidt-Dalton TA, Weiss PM. Evaluation and management of abnormal uterine bleeding in premenopausal women. *Am Fam Physician.* 2012;85(1):35-43.
- American College of Obstetricians and Gynecologists. ACOG committee opinion no. 557: Management of acute abnormal uterine bleeding in nonpregnant reproductive-aged women. *Obstet Gynecol.* 2013;121(4):891-6.
- Munro MG, Critchley HO, Fraser IS. The FIGO classification of causes of abnormal uterine bleeding in the reproductive years. *Fertil Steril.* 2011;95(7):2204-8.
- Garcia-Solares J, Donnez J, Donnez O, Dolmans MM. Pathogenesis of uterine adenomyosis: Invagination or metaplasia? *Fertil Steril.* 2018;109(3):371-9.
- Cheong Y, Cameron IT, Critchley HOD. Abnormal uterine bleeding. *Br Med Bull.* 2017;123(1):103-14.
- Practice bulletin no. 136: Management of abnormal uterine bleeding associated with ovulatory dysfunction. *Obstet Gynecol.* 2013;122(1):176-85.
- Sammour A, Pirwany I, Usubutun A, Arseneau J, Tulandi T. Correlations between extent and spread of adenomyosis and clinical symptoms. *Gynecol Obstet Invest.* 2002;54(4):213-6.
- Pontis A, D'Alterio MN, Pirarba S, Angelis C, Tinella R, Angioni S. Adenomyosis: A systematic review of medical treatment. *Gynecol Endocrinol.* 2016;32(9):696-700.
- Vannuccini S, Luisi S, Tosti C, Sorbi F, Petraglia F. Role of medical therapy in the management of uterine adenomyosis. *Fertil Steril.* 2018;109(3):398-405.
- Bradley LD, Gueye NA. The medical management of abnormal uterine bleeding in reproductive-aged women. *Am J Obstet Gynecol.* 2016;214(1):31-44.
- Uhm S, Perriera L. Hormonal contraception as treatment for heavy menstrual bleeding: A systematic review. *Clin Obstet Gynecol.* 2014;57(4):694-717.
- Osada H. Uterine adenomyosis and adenomyoma: The surgical approach. *Fertil Steril.* 2018;109(3):406-17.
- Benetti-Pinto CL, Rosa ESA, Yela DA, Junior JMS. Abnormal uterine bleeding. *Rev Bras Ginecol Obstet.* 2017;39(7):358-68.
- Gordts S, Brosens JJ, Fusi L, Benagiano G, Brosens I. Uterine adenomyosis: A need for uniform terminology and consensus classification. *Reprod Biomed Online.* 2008;17(2):244-8.
- Benagiano G, Habiba M, Brosens I. The pathophysiology of uterine adenomyosis: an update. *Fertil Steril.* 2012;98(3):572-9.
- Agostinho L, Cruz R, Osorio F, Alves J, Setubal A, Guerra A. MRI for adenomyosis: A pictorial review. *Insights Imaging.* 2017;8(6):549-56.

19. Bazot M, Darai E. Role of transvaginal sonography and magnetic resonance imaging in the diagnosis of uterine adenomyosis. *Fertil Steril*. 2018;109(3):389-97.
20. Abbott JA. Adenomyosis and Abnormal Uterine Bleeding (AUB-A)- Pathogenesis, diagnosis, and management. *Best Pract Res Clin Obstet Gynaecol*. 2017;40:68-81.
21. Dueholm M, Lundorf E, Hansen ES, Sorensen JS, Lodertoug S, Olesen F. Magnetic resonance imaging and transvaginal ultrasonography for the diagnosis of adenomyosis. *Fertil Steril*. 2001;76(3):588-94.
22. Vercellini P, Vigano P, Somigliana E, Daguati R, Abbiati A, Fedele L. Adenomyosis: Epidemiological factors. *Best Pract Res Clin Obstet Gynaecol*. 2006;20(4):465-77.
23. Andres MP, Borrelli GM, Ribeiro J, Baracat EC, Abrao MS, Kho RM. Transvaginal ultrasound for the diagnosis of adenomyosis: Systematic review and meta-analysis. *J Minim Invasive Gynecol*. 2018;25(2):257-64.
24. Champaneria R, Abedin P, Daniels J, Balogun M, Khan KS. Ultrasound scan and magnetic resonance imaging for the diagnosis of adenomyosis: Systematic review comparing test accuracy. *Acta Obstet Gynecol Scand*. 2010;89(11):1374-84.
25. Gordts S, Grimbizis G, Campo R. Symptoms and classification of uterine adenomyosis, including the place of hysteroscopy in diagnosis. *Fertil Steril*. 2018;109(3):380-8.
26. Grimbizis GF, Mikos T, Tarlatzis B. Uterus-sparing operative treatment for adenomyosis. *Fertil Steril*. 2014;101(2):472-87.
27. Kishi Y, Suginami H, Kuramori R, Yabuta M, Suginami R, Taniguchi F. Four subtypes of adenomyosis assessed by magnetic resonance imaging and their specification. *Am J Obstet Gynecol*. 2012;207(2):114.e1-7.
28. Hulka CA, Hall DA, McCarthy K, Simeone J. Sonographic findings in patients with adenomyosis: Can sonography assist in predicting extent of disease? *AJR Am J Roentgenol*. 2002;179(2):379-83.
29. Siegler AM, Camilien L. Adenomyosis. *J Reprod Med*. 1994;39(11):841-53.
30. Lazzeri L, Morosetti G, Centini G, Monti G, Zupi E, Piccione E, et al. A sonographic classification of adenomyosis: Interobserver reproducibility in the evaluation of type and degree of the myometrial involvement. *Fertil Steril*. 2018;110(6):1154-61.e3.
31. Pepas L, Deguara C, Davis C. Update on the surgical management of adenomyosis. *Curr Opin Obstet Gynecol*. 2012;24(4):259-64.
32. Gupta J, Kai J, Middleton L, Pattison H, Gray R, Daniels J. Levonorgestrel intrauterine system versus medical therapy for menorrhagia. *N Engl J Med*. 2013;368(2):128-37.
33. Zhang P, Song K, Li L, Yukuwa K, Kong B. Efficacy of combined levonorgestrel-releasing intrauterine system with gonadotropin-releasing hormone analog for the treatment of adenomyosis. *Med Princ Pract*. 2013;22(5):480-3.
34. Gordts S, Campo R, Brosens I. Hysteroscopic diagnosis and excision of myometrial cystic adenomyosis. *Gynecol Surg*. 2014;11(4):273-8.