



## Intraoperative use of Indocyanine Green to Confirm Perfusion of Remnant Tissue in Cortical-Sparing Retroperitoneoscopic Adrenalectomy

Long KL\*, Graham PH, Grubbs EG, Lee JE and Perrier ND

Department of Surgical Endocrinology, University of Texas MD Anderson Cancer Center, USA

### Abstract

A 53-year old male was diagnosed with bilateral pheochromocytomas after abdominal imaging revealed bilateral adrenal masses. Elevated serum catecholamines confirmed a pheochromocytoma, MIBG scan identified bilateral isotope uptake and genetic testing revealed a TMEM 127 mutation. Antihypertensive catecholamine-blocking medication was initiated. Given the desire to retain adequate cortical function, selective resection with a left total adrenalectomy and a cortical-sparing right sided adrenalectomy was planned via a retroperitoneoscopic approach. Intraoperatively, fluorescent indocyanine green was utilized to confirm perfusion to the right-sided adrenal remnant prior to proceeding with a left-sided total resection. This case exemplifies a method of intraoperative confirmation of cortex perfusion that enhances laparoscopic cortical-sparing adrenalectomy.

**Keywords:** Adrenal; Retroperitoneoscopic; Indocyanine green; Cortical-Sparing

### Introduction

Posterior retroperitoneoscopic adrenalectomy (PRA) has emerged as a safe and effective treatment modality for surgical resection of adrenal tumors, and in many scenarios, may represent the preferred approach. In cases where bilateral adrenal masses require intervention, PRA offers the ability to access both adrenal glands without a cumbersome and time-consuming change in position while retaining the patient-derived benefits of minimally invasive surgery [1]. Certain genetic syndromes predispose patients to the development of bilateral tumors. In TMEM 127 mutations, patients frequently present with multifocal, bilateral tumors necessitating surgical resection [2]. In these cases, a cortical-sparing approach is of utmost value to prevent post-operative adrenal insufficiency.

Indocyanine green (ICG), a water-soluble dye initially used in near-infrared photography, has been utilized in multiple surgical procedures to facilitate tissue identification and subsequent dissection. ICG has been employed to localize the adrenal gland, a highly vascular organ, and to aid in tumor removal for attempted cortical-sparing procedures [3-6]. While it has been useful in delineating the tumor boundaries for resection, reserving the administration of ICG until after tumor removal to examine perfusion to the cortical remnant has not been described. We describe a novel technique to assess perfusion of adrenal cortical remnant tissue using indocyanine green infusion after removal of bilateral pheochromocytomas.

### Case Presentation

A 53-year old previously healthy avid marathon runner was evaluated in the emergency department of a regional hospital with abdominal pain, syncope, irritability and severe hypertension. Abdominal computed tomography revealed bilateral adrenal nodularity, including a large left-sided mass measuring approximately 5 centimeters as well as 2 distinct subcentimeter right-sided nodules (Figure 1). Elevated serum catecholamines confirmed pheochromocytoma. Metaiodobenzylguanidine (MIBG) scan identified bilateral isotope uptake and genetic testing revealed a TMEM 127 mutation. Antihypertensive catecholamine-blocking medication with both alpha- and beta-blockers was initiated in preparation for surgical resection and continued until the patient demonstrated mild orthostatic hypotension.

Given the desire to retain adequate cortical function, selective resection with a left total adrenalectomy and a cortical-sparing right-sided adrenalectomy was planned via a

### OPEN ACCESS

#### \*Correspondence:

Kristin L. Long, Department of Surgical Endocrinology, University of Texas MD Anderson Cancer Center, Unit 1484 PO Box 301402, Houston TX 77230, USA, Tel: 713-745-0599; Fax: 713-563-5727; E-mail: kleighl@yahoo.com

**Received Date:** 12 Jul 2016

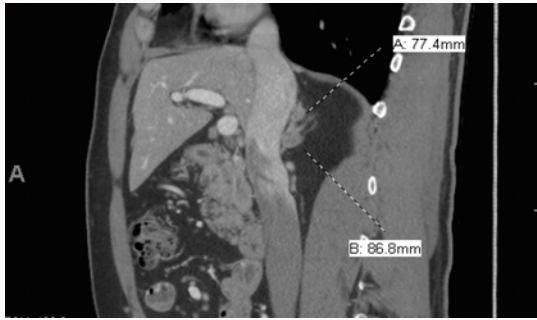
**Accepted Date:** 16 Aug 2016

**Published Date:** 14 Sep 2016

#### Citation:

Long KL, Graham PH, Grubbs EG, Lee JE, Perrier ND. Intraoperative use of Indocyanine Green to Confirm Perfusion of Remnant Tissue in Cortical-Sparing Retroperitoneoscopic Adrenalectomy. *Clin Surg*. 2016; 1: 1111.

**Copyright** © 2016 Long KL. This is an open access article distributed under the Creative Commons Attribution License, which permits unrestricted use, distribution, and reproduction in any medium, provided the original work is properly cited.



**Figure 1:** Computed Tomography demonstrating 2 distinct sub-centimeter nodules in the right adrenal gland.

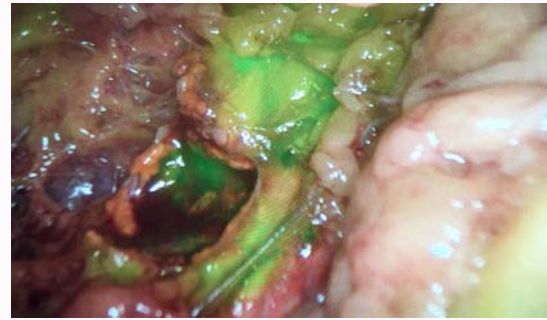
retroperitoneoscopic approach. The right-sided adrenal gland was approached first, and after enucleation of the two small tumors, 5 milliliters of indocyanine green was injected intravenously. After approximately 1 minute, a laparoscopic infrared camera (Novadaq Pinpoint<sup>™</sup>, Bonita Springs, Florida) was placed into a trocar and a bright green hue was identified in the remaining adrenal tissue (Figure 2). Once perfusion to the right-sided adrenal remnant was confirmed, a left-sided total resection was performed via retroperitoneoscopic approach.

The patient tolerated the procedure well and was discharged home on postoperative day 1 with no steroid supplementation. A cosyntropin stimulation test was performed with resulting cortisol levels in the normal range. Post-operatively, he developed intermittent symptoms of nausea, cramping, numbness and profound malaise. These symptoms were ultimately felt to be linked to cigar smoking, which appeared to produce an acute mineralocorticoid insufficiency not identified by standard post-operative cortisol stimulation testing [7]. A short course of fludrocortisone dosing resolved his symptoms. He has since returned to normal activity, including distance running and defensive trial work with no further side effects or medication requirements.

## Discussion

Use of ICG to effectively assess perfusion has been validated in several surgical procedures, including gastrointestinal anastomoses [8]. Likewise, ICG-confirmed perfusion has been demonstrated to predict post-operative function in parathyroid glands after thyroid surgery [9]. To our knowledge, this is the first report of using ICG in such a manner for adrenal surgery.

This case exemplifies a method of intraoperative confirmation of cortex perfusion that enhances minimally invasive cortical-sparing adrenalectomy. The bright green hue of cortical remnant minimized concern for adrenal insufficiency. This, in turn, may help guide surgeons in proceeding with total adrenalectomy on the contralateral side if necessary. Increased confidence in the viability of the adrenal remnant may also facilitate withholding routine steroid hormone supplementation post-operatively. Although the green hue confirmed cortex preservation, perfusion itself does not directly ensure adequate post-operative adrenal function. We feel this novel technique will be



**Figure 2:** Intraoperative imaging demonstrating bright green perfusion of remnant adrenal tissue after resection of small pheochromocytoma.

particularly valuable for patients with bilateral adrenal nodules, as well as those with genetic predispositions to developing multifocal tumors, as is seen in the TMEM127 mutation. Working towards the ultimate goal of minimizing post-surgical adrenal insufficiency, further studies are needed to delineate the relationship between intraoperative tissue perfusion and post-operative adrenal function.

## References

- Dickson PV, Alex GC, Grubbs EG, Ayala-Ramirez M, Jimenez C, Evans DB, et al. Posterior retroperitoneoscopic adrenalectomy is a safe and effective alternative to transabdominal laparoscopic adrenalectomy for pheochromocytoma. *Surgery*. 2011; 150: 452-458.
- Toledo SP, Lourenço DM Jr, Sekiya T, Lucon AM, Baena ME, Castro CC, et al. Penetrance and clinical features of pheochromocytoma in a six-generation family carrying a germline TMEM127 mutation. *J Clin Endocrinol Meta*. 2015; 100: E308-E318.
- Sound S, Okoh AK, Bucak E, Yigitbas H, Dural C, Berber E. Intraoperative tumor localization and tissue distinction during robotic adrenalectomy using indocyanine green fluorescence imaging: a feasibility study. *Surg Endosc*. 2016; 30: 657-662.
- DeLong JC, Chakedis JM, Hosseini A, Kelly KJ, Horgan S, Bouvet M. Indocyanine Green fluorescence-guided laparoscopic adrenalectomy. *J Surg Onc*. 2015; 112: 650-653.
- Manny TB, Pompeo AS, Hemal AK. Robotic partial adrenalectomy using indocyanine green dye with near-infrared imaging: the initial clinical experience. *Urology*. 2013; 82: 738-742.
- Dip FD, Roy M, Perrins S, Ganga RR, Lo Menzo E, Szomstein S, et al. Technical description and feasibility of laparoscopic adrenal contouring using fluorescence imaging. *Surg Endosc*. 2015; 29: 569-574.
- Armario A. Activation of the hypothalamic-pituitary-adrenal axis by addictive drugs: different pathways, common outcome. *Trends Pharmacol Sci*. 2010; 31: 318-325.
- Degett TH, Andersen HS, Gogenur I. Indocyanine green fluorescence angiography for intraoperative assessment of gastrointestinal anastomotic perfusion: a systematic review of clinical trials. *Langenbecks Arch Surg*. 2016.
- Fortuny JV, Belfontali V, Sadowski SM, Karenovics W, Guigard S, Triponez F. Parathyroid gland angiography with indocyanine green fluorescence to predict parathyroid function after thyroid surgery. *Br J Surg*. 2016; 103: 537-543.