



Internal Hernia Repair as an Emergency after Primary and Revisional Bariatric Surgery: Results from a High-Volume Referral Center

Rodolfo J Oviedo^{1,2,3,4*}

¹Department of General Surgery, Texas Bariatric Specialists, USA

²Metropolitan Methodist Hospital, USA

³Southwest General Hospital, USA

⁴South Texas Surgical Institute, USA

Abstract

Background: Reduction and closure of internal hernia has become a frequent emergency bariatric procedure at high-volume centers to treat complications after primary and revisional bariatric surgery.

Methods: A retrospective chart review with IRB approval was conducted on 61 emergency bariatric surgery cases performed by a single surgeon at an accredited MBSAQIP high-volume bariatric center and community hospital from August 2018 to February 2020. A subgroup analysis of 34 internal hernia repairs after a prior primary or revisional bariatric operation was conducted with measurement of primary outcomes (30-day morbidity and mortality) and secondary outcomes (concomitant adhesiolysis and small bowel resection, length of stay, recurrence and need for re-operation, among others).

Results: All patients (n=34) underwent an emergency repair of internal hernia after prior primary or revised Roux en Y gastric bypass (91.2%) and classic duodenal switch (8.8%). Most of them were female (85.3%), and the mean age was 49.3 ± 12.9 years. Almost all surgeries (97.1%) started laparoscopically, with a rate of conversion to open of 14.7%. There was no mortality, and the 30-day morbidity was 29.4%. The mean follow-up duration was 5.8 ± 5.4 months, and the median ASA class was 3. Adhesiolysis was performed in 76.5% of cases, while the rate of concomitant small bowel resection was 8.8%. A subsequent repair of internal hernia was performed in 26.5% of cases. Among the gastric bypass internal hernias, the most common configuration was retrocolic-retrogastric (61.8%), with a jejunojejunostomy mesenteric defect being the most common site of herniation (55.9%). A CT abdomen/pelvis was obtained in 100% of cases to make a definitive diagnosis, and all patients were taken to operating room within 4 hours of presentation.

Conclusion: Emergency repair of internal hernia can be safely performed at a high-volume center and community hospital environment with the laparoscopic approach and with no mortality, although the 30-day morbidity can be significant. A prior Roux en Y gastric bypass is the most common indication, with the retrocolic-retrogastric anatomy and the jejunojejunostomy mesenteric defect as the most frequent configuration and site, respectively.

Keywords: Internal hernia; Bariatric surgery; Community hospital; Emergency; Complications

Introduction

Metabolic and bariatric surgery is the super-specialty devoted to the eradication and control of obesity-related co-morbidities while achieving reliable weight loss to improve quality of life [1,2]. In particular, the Roux en-Y gastric bypass is recognized as its gold standard, but it is associated with early and late complications including development of internal herniation at any of its created mesenteric defects. The most common presentation is abdominal pain, particularly in the left upper quadrant, with a Computerized Tomography (CT) abdomen/pelvis scan as the most useful diagnostic modality [3,4]. The adoption of mesenteric defect closure during the index procedure has led to a decrease in the incidence of internal hernias and should be regarded as good practice [5].

With respect of the nature of internal herniation after all types of bariatric procedures, the most

OPEN ACCESS

***Correspondence:**

Rodolfo J Oviedo, Department of General Surgery, Texas Bariatric Specialists, Metropolitan Methodist Hospital, Southwest General Hospital, South Texas Surgical Institute, 14603 Huebner Rd, Building 2, San Antonio, TX 78230, USA,
E-mail: rodolfo.j.oviedo@gmail.com

Received Date: 27 May 2020

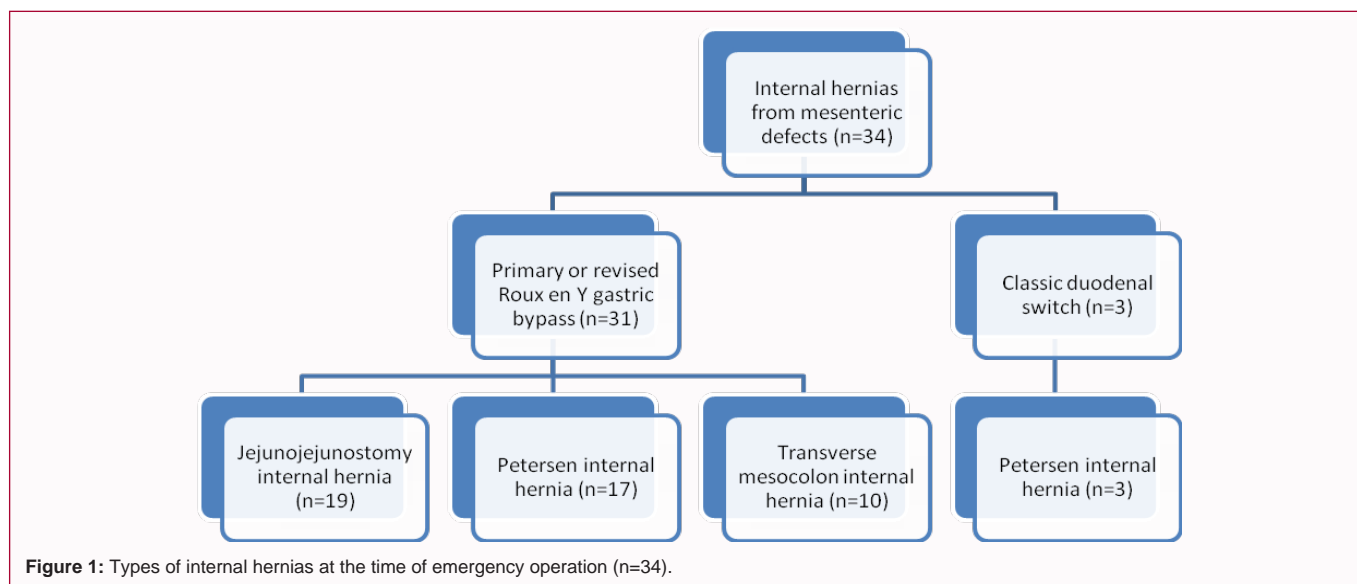
Accepted Date: 02 Jul 2020

Published Date: 13 Jul 2020

Citation:

Oviedo RJ. Internal Hernia Repair as an Emergency after Primary and Revisional Bariatric Surgery: Results from a High-Volume Referral Center. *Clin Surg.* 2020; 5: 2861.

Copyright © 2020 Rodolfo J Oviedo. This is an open access article distributed under the Creative Commons Attribution License, which permits unrestricted use, distribution, and reproduction in any medium, provided the original work is properly cited.



common etiology is the presence of unclosed or re-opened mesenteric defects after a combined restrictive and malabsorptive operation such as the Roux en Y gastric bypass or the biliopancreatic diversion with duodenal switch. Although adhesive disease may also be associated with these defects or be the only reason for a small bowel obstruction, it is recommended that all mesenteric defects be closed to prevent this complication [6-9].

Bariatric surgery emergencies should be handled by surgeons and hospitals accustomed to and experienced with these challenging clinical scenarios, since both patient and team factors play a role in the subsequent presence or absence of complications [10]. What is crucial is the development of diagnostic and treatment algorithms at each bariatric program and hospital that functions as a referral center for bariatric emergencies, with internal hernias occurring as early and late complications after primary and revisional surgery [11]. The utilization of bioabsorbable material similar to mesh has been advocated by some groups at the time of primary bariatric operations to prevent development of internal hernias, but in reality they may also occur after revisional surgery, sometimes with a higher incidence compared to primary surgery [12]. In fact, one of the indications for revisional bariatric surgery is the presence of internal herniation with chronic abdominal pain leading to suboptimal weight management after a primary procedure [13].

Methods

With IRB approval from the Ethics Committee at a 495-bed acute care community hospital serving approximately 500,000 patients per year at the Shenandoah Valley of Virginia in the United States, a retrospective chart review was conducted. The retrospective review included 61 bariatric surgery emergencies from August 2018 to February 2020. Of those, this study presents the outcomes corresponding to 34 adult patients who had previously undergone a primary or revisional bariatric operation, both locally and at other programs. All emergency surgeries were performed by the author, a fellowship-trained metabolic and bariatric surgeon previously affiliated with such hospital and its MBSAQIP-accredited metabolic and bariatric program. An analysis of primary outcomes (30-day morbidity and mortality) in addition to secondary outcomes (need for adhesiolysis and small bowel resection, length of stay, recurrence

and need for re-operation, among others) was done.

Inclusion criteria

- Prior primary bariatric operation (laparoscopic and open)
- Prior revisional bariatric operation (laparoscopic and open)
- Ages 18 to 65 years
- Emergency (non-elective) presentation

Surgical technique

- Upon establishing pneumoperitoneum and inserting the ports, or after making a midline laparotomy incision from the beginning, a thorough evaluation of the bariatric anatomy was conducted while expediting the reduction of the small bowel volvulus (if present) before attempting to close the internal hernia defect with permanent suture in a running fashion.

- Adhesiolysis was performed most of the times before internal hernia closure, but ideally after having reduced the small bowel and the volvulus (if present) to prevent further ischemia and necrosis.

- If a small bowel resection was necessary, it was done while creating an anastomosis with the linear-stapled technique immediately after that. If a Braun enteroenterostomy was required to bypass an anastomotic stricture, it was performed with the linear-stapled technique, too, without having to resect the bowel.

- If the internal hernia was not caused by a re-opened or an open mesenteric defect that was not previously closed, then it was caused by adhesive bands. In that case, all adhesive bands were lysed with scissors while maintaining the same principles of safe reduction of the small bowel and volvulus to prevent ischemia and necrosis or the need for a resection.

- In most cases, an upper gastrointestinal endoscopy was performed, and a surgical drain was not necessary.

Figure 1 describes the patients' types of internal hernias while taking their prior procedure, configuration, and mesenteric site into account.

Results

All of the patients underwent a rapid evaluation in the emergency department based on established diagnostic algorithms developed in conjunction with the Metabolic and Bariatric Surgery Division of the Department of Surgery. A CT scan abdomen/pelvis was obtained in all cases for a definitive diagnosis and was combined with clinical suspicion in scenarios where no obvious volvulus was observed. Some of the signs of internal herniation observed were a mesenteric “swirl” sign, small bowel edema at the classic mesenteric defect sites, and ascites. All surgeries were performed within 4 h of presentation to the emergency department, most of them within 2 h, and especially at night or early morning hours.

Most surgeries started with the laparoscopic approach (97.1%), but the rate of conversion to open was 14.7%. Only 2.9% of the operations were performed open from the beginning based on surgical decision-making upon presentation. While a small bowel resection was only necessary in 8.8% of cases, adhesiolysis was performed in 76.5%. In all instances, a prior combined restrictive and malabsorptive procedure had been performed before emergency presentation: 91.2% primary or revised Roux en-Y gastric bypass, and 8.8% biliopancreatic diversion with classic duodenal switch.

Most patients were female (85.3%), as is expected based on typical patient populations after primary or revisional bariatric surgery. The mean age was 49.3 ± 12.9 years, and the median ASA class was 3. The mean follow-up duration was 5.8 ± 5.4 months. While internal hernias from mesenteric defects were found on most patients, one patient (2.9%) had associated intussusception of the distal ileum which contributed to the small bowel obstruction on presentation. On the other hand, three patients (8.8%) had associated strictures at the jejunojejunostomy after a prior Roux en-Y gastric bypass, for which a Braun enteroenterostomy as an intestinal bypass was performed in one (2.9%) to avoid a small bowel resection.

The demographic data along with pre-operative co-morbidities and risk factors are presented in Table 1.

With respect to primary outcomes, there was no mortality. On the other hand, the 30-day morbidity was 29.4% corresponding to ten patients who developed complications. However, complications beyond 30 days were also recorded and measured as secondary outcomes. This included a 5.9% rate of enterocutaneous fistula formation corresponding to two patients who presented with a frozen abdomen as a result of prior multiple abdominal surgeries. One of these patients had actually undergone a prior Roux en-Y gastric bypass reversal, but due to her complex anatomy this challenging case was managed by the Metabolic and Bariatric Surgery service from the beginning although there was no longer a gastric bypass anatomy. Both incidences of enterocutaneous fistulae occurred due to extremely difficult and extensive adhesiolysis in the setting of a frozen abdomen, but with conservative and comprehensive measures including total parenteral nutrition, skin protection barriers, antibiotics when indicated, and quantification of daily fistula output, both resolved in less than 3 months.

Other complications included 8.8% intra-abdominal abscess, 8.8% readmissions, 17.6% emergency department visits, 2.9% deep venous thrombosis without pulmonary embolism, 2.9% post-operative pneumonia, and 11.8% acute kidney injury.

The mean length of stay was 4.6 ± 8.0 days. The hospitalization

Table 1: Patient demographics and pre-operative co-morbidities (n=34).

Age (mean)	49.3 ± 12.9 years
Sex (female, male)	29 (85.3%), 5 (14.7%)
ASA class (median)	3
Pre-op BMI (mean)	30.6 ± 5.3 kg/m ²
Pre-op albumin (mean)	3.7 ± 0.6 gm/dL
Pre-op type 2 diabetes	7 (20.6%)
Pre-op hypertension	6 (17.6%)
Pre-op dyslipidemia	10 (29.4%)
Pre-op GERD	10 (55.6%)
Pre-op OSA	10 (29.4%)
Pre-op CKD/ESRD	1 (2.9%)
Pre-op CAD	3 (8.8%)
Tobacco use	11 (32.3%)

ASA: American Society of Anesthesiologists classification, Pre-op: Pre-operative, BMI: Body Mass Index, GERD: Gastroesophageal Reflux Disease, OSA: Obstructive Sleep Apnea, CKD: Chronic Kidney Disease, ESRD: End Stage Renal Disease, CAD: Coronary Artery Disease

Table 2: Primary and secondary outcomes (n=34).

Mortality	0 (0%)
30-day morbidity	10 (29.4%)
Conversion to open	5 (14.7%)
Length of stay (mean)	4.6 ± 8.0 days
EBL (mean)	25.0 ± 18.7 mL
Blood transfusions	3 (8.8%)
Intraoperative time (mean)	74.1 ± 37.9 minutes
Superficial SSI	4 (11.8%)
Pneumonia	1 (2.9%)
DVT without PE	1 (2.9%)
AKI	4 (11.8%)
Intra-abdominal abscess	3 (8.8%)
Enterocutaneous fistula	2 (5.9%)
Readmissions	3 (8.8%)
ED visits	6 (17.6%)
Need for re-operation for recurrent or new internal hernia	9 (26.5%)

EBL: Estimated Blood Loss, SSI: Surgical Site Infection, OR: Operating Room, DVT: Deep Venous Thrombosis, PE: Pulmonary Embolus, ED: Emergency Department

for patients who underwent an emergency laparoscopic repair was optimized with the Enhanced Recovery After Surgery (ERAS) protocol and pathway instituted in the hospital as part of the center's guidelines. The rate of blood transfusion was 8.8%, and the estimated blood loss intra-operatively was 25 ± 18.7 mL. Table 2 illustrates the primary outcomes and the most important secondary outcomes measured.

Discussion

This retrospective chart review of 34 emergency internal hernia repairs at a high-volume referral center accredited by the MBSAQIP (Metabolic and Bariatric Surgery Accreditation and Quality Improvement Program) illustrates the challenges encountered during the clinical management of complications after primary and revisional bariatric surgery. In this subgroup analysis from the 61 bariatric surgery emergency patients who were subjected to

retrospective review, the presence of a mesenteric defect internal hernia after primary or revised Roux en-Y gastric bypass and classic duodenal switch is associated with high morbidity. While there was no mortality to report, this study supports the concept that the management of bariatric surgery complications and emergencies, even when performed at high-volume referral centers, may be associated with significant complication rates and high recurrence rates that justify the implementation of an evidence-based diagnostic and treatment algorithm. Such protocol begins in the emergency department, continues in the operating room, and is applied to the crucial post-operative period when complications may still arise and where attention to detail is of paramount importance.

In this retrospective review subgroup analysis several lessons were learned. Firstly, no matter how advanced the surgeon's skills and the surgical team's level of expertise may be, the pre-operative conditions and co-morbidities in addition to risk factors such as age, ASA class, and a prior combined restrictive and malabsorptive procedure played a role in the development of post-operative complications. While there was no mortality and the rate of conversion to open accounted for a minority of cases, these are highly-demanding and technically advanced operations. Not only do they require the repair of mesenteric defects, but they also involve reduction of the small bowel and possible volvulus associated with internal herniation while avoiding perforation and the need for resection.

As can be seen, the rate of re-operation for a recurrent or a new internal hernia is high (26.5%). The use of permanent sutures with bites incorporating visceral peritoneum and not only mesenteric fat is essential to prevent future herniation. Attention to the mesenteric blood supply while avoiding injuring its vessels is fundamental to prevent future complications such as bowel necrosis, intra-abdominal abscess, or enterocutaneous fistula. Among the Roux en-Y gastric bypass internal hernias, specifically, both for prior primary or revisional cases, the most common configuration was retrocolic-retrogastric (61.8%), followed by antecolic-antegastric (17.6%) and retrocolic-antegastric (5.9%). The most common site of herniation was the jejunojejunostomy mesenteric defect (55.9%), followed by Petersen space (50.0%) and the transverse mesocolon defect (29.4%). This is important since it correlates with the literature by pointing out that the retrocolic-retrogastric anatomy is associated with higher rates of internal herniation, with the jejunojejunostomy defect in this case being slightly higher than the Petersen space.

On the other hand, while the rate of intra-abdominal abscess is relatively low (8.8%), the incidence of serious complications such as enterocutaneous fistula formation is not negligible (5.9%) and is associated with the presence of a frozen, almost inoperable abdomen due to multiple prior abdominal surgeries with complications. Attention to the principles and surgical tenets required for management of enterocutaneous fistulae is crucial and an essential part of the bariatric surgeon's armamentarium. A multi-disciplinary team approach involves the surgeon, infectious disease specialist, hospitalist, dietitians, pharmacists, nurses, enterostomal/wound care specialists, and other professionals.

Another important lesson learned is that bariatric surgery emergencies involving internal hernias can range from the least complex lysis of adhesive bands and closure of mesenteric defects without a volvulus, to the extremely complex. The latter cases can be technically demanding and include the reduction of a small bowel volvulus, a formal resection of the jejunojejunostomy with

reconstruction of its trifurcation intestinal limbs, or creation of a Braun enteroenterostomy as an intestinal bypass for a stricture. At all times, the use of permanent suture material while protecting the mesenteric blood supply are required.

This subgroup analysis study has several limitations, beginning with its moderate number of patients (n=34). However, even with this patient population size it is possible to make some important observations and learn from the outcomes while comparing them to the literature. It would be ideal to conduct a retrospective review of this particular patient population on a larger sample size, but it is not possible at this time since the author has moved on to another practice and hospital environment where future projects like this one will be conducted on a larger scale. In addition, the fact that this is a retrospective, rather than a prospective cohort of patients is a limitation. Implementation of a randomized controlled trial would not be very practical in this emergency scenario, but it would not be impossible with some imagination and creativity. For instance, a possible clinical trial may consist of the randomization of patients who do not present with signs of bowel ischemia to undergo an immediate repair at night versus a repair the next morning. Alternatively, a randomized controlled trial may look at the diagnosis and decision to operate with and without the use of a CT scan. Finally, the fact that this is a single-center study based on the experience by one surgeon is a limitation, although it also offers the uniformity and systematic advantages that arise when a standard protocol and the same technique are applied to care for surgical patients. The follow-up should be longer, too, but for the same reasons explained before it is not possible to extend it under the circumstances. However, a follow-up that is longer than 1 year is ideal to make more solid observations in this patient population.

Academic and community hospitals and programs alike should be equipped to handle the challenges posed by internal hernias after primary and revisional bariatric surgery. Not only is the center's ability to deal with complications of paramount importance. In addition, its resources and capabilities such as imaging technology, surgical and endoscopic instrumentation, and network of consultants and experts (including hospitalists, infectious disease specialists, intensivists and interventional radiologists) are fundamental. Moreover, the surgeon's experience (ideally with fellowship training or its equivalent) and the surgical team's level of expertise are essential. Both should be nurtured, cultivated and perfected to optimize patient outcomes and safety above all things.

Conclusion

Repair of internal herniation as an emergency after primary and revisional bariatric surgery is feasible in the community hospital environment with no mortality if performed at a high-volume referral center. A quarter of cases require a re-operation, but it is possible to perform most of these surgeries with the laparoscopic approach. The most common indication is a prior Roux en-Y gastric bypass, with the retrocolic-retrogastric anatomy and the jejunojejunostomy mesenteric defect as the most common configuration and site of herniation, respectively.

References

1. Chang SH, Carolyn RTS, Jihyun S, Esteban VJ, Christopher JE, Graham CA. Bariatric surgery: An updated systematic review and meta-analysis, 2003-2012. *JAMA Surg.* 2014;149(3):275-87.
2. Oviedo Barrera RJ. Metabolic and bariatric surgery: Evolution, techniques,

- and management. In: Neri V, editor. *Gastrointestinal Surgery - New Technical Proposals*. London, UK. Intech; 2018:1-26.
3. Tartamella F, Ziccarelli A, Cecchini S, Ferro M, Riccò M, Baldini E, et al. Abdominal pain and internal hernias after Roux-en-Y gastric bypass: are we dealing with the tip of an iceberg? *Acta Biomed*. 2019;90(2):251-8.
 4. Nimeri AA, Maasher A, Al Shaban T, Salim E, Gamaleldin MM. Internal hernia following laparoscopic Roux-en-Y gastric bypass: Prevention and tips for intra-operative management. *Obes Surg*. 2016;26(9):2255-6.
 5. Kristensen SD, Floyd AK, Naver L, Jess P. Does the closure of mesenteric defects during laparoscopic gastric bypass surgery cause complications? *Surg Obes Relat Dis*. 2015;11(2):459-64.
 6. Dou L, Yang H, Wang C, Tang H, Li D. Adhesive and non-adhesive internal hernia: Clinical relevance and multi-detector CT images. *Sci Rep*. 2019;9(1):12847.
 7. Chowbey P, Bajjal M, Kantharia NS, Khullar R, Sharma A, Soni V. Mesenteric defect closure decreases the incidence of internal hernias following laparoscopic Roux-en-Y gastric bypass: A retrospective cohort study. *Obes Surg*. 2016;26(9):2029-34.
 8. Aghajani E, Nergaard BJ, Leifson BG, Hedenbro J, Gislason H. The mesenteric defects in laparoscopic Roux-en-Y gastric bypass: 5 years follow-up of non-closure versus closure using the stapler technique. *Surg Endosc*. 2017;31(9):3743-8.
 9. Brolin RE, Kella VN. Impact of complete mesenteric closure on small bowel obstruction and internal mesenteric hernia after laparoscopic Roux-en-Y gastric bypass. *Surg Obes Relat Dis*. 2013;9(6):850-4.
 10. Hussain A, El-Hasani S. Bariatric emergencies: Current evidence and strategies of management. *World J Emerg Surg*. 2013;8(1):58.
 11. Hamdan K, Somers S, Chand M. Management of late postoperative complications of bariatric surgery. *Br J Surg*. 2011;98(10):1345-55.
 12. Love MW, Roosbeh M, Allyson LH, Eric SB, Ihab S, Joseph AE, et al. Use of bioabsorbable tissue reinforcement reduces incidence of internal hernia in Roux-en-Y gastric bypass patients. *Am Surg*. 2018;84(11):1756-61.
 13. Qiu J, Lundberg PW, Birriel TJ, Claros L, Stoltzfus J, El Chaar M. Revisional bariatric surgery for weight regain and refractory complications in a single MBSAQIP accredited center: What are we dealing with? *Obes Surg*. 2018;28(9):2789-5.