



## Interpleural Ruptured Hydatid Cyst of Liver Presented as Pleural Effusion with Multiple Daughter Cysts

Aghajanzadeh M\*, Hemati H, Delshad MSE and Samidost P

Department of Thoracic and General Surgery, Razi Hospital, Guilan University of Medical Sciences, Rasht, Iran

### Clinical Image

Hydatid disease still remains an important health problem in Iran. Although it can be found in any part throughout the body, it is more common in the liver (75%) and lung (25%). Intrapleural rupture of Pulmonary Hydatid Cyst (PHC) is a rare but dangerous complication.

A 54-year-old woman patient admitted to emergency service with right side chest pain and dyspnea on physical examination. The respiration rate was 22/min and breath sounds were diminished on the right lung. In her past medical show two times right subcostal incision for operation of liver hydatid cysts on chest radiography revealed pleural effusion on right pleural space, and on chest tomographic examination, pleural effusion with the collapse of right inferior lung was observed and in the effusion multiple air space was presented (Figure 1 and 2). Thoracentesis was performed and chest-tube was inserted. Low glucose and pH and high (WBC=1,000) and lactate dehydrogenase level of pleural fluid were suggesting its empyema nature. At the 5<sup>th</sup> day, chest radiograph indicated inadequate expansion of the right lung. Patient underwent to the right posterolateral thoracotomy due to persistent of collapse of lung. Multiple lesion, laminated membrane and daughter cysts resembling to hydatid cyst (Figure 3 and 4). After evacuation all fluid with daughter cysts and laminated membrane, decortication was done, in current of procedure a fistulae between liver, diaphragm and pleural space was presented. Perinotomy was performed and cyst of liver was evacuated and a folttcather was put in the remenant cavity of liver. He was transferred to intensive care unit for 2 days. Albendazole therapy was initiated after an uneventful post-operative course, patient was discharged.

### OPEN ACCESS

#### \*Correspondence:

Manouchehr Aghajanzadeh,  
Department of General Thoracic  
Surgery, Guilan University of Medical  
Sciences, Rasht, Iran, Tel: +98  
9111311711;  
E-mail: maghajanzadeh2003@yahoo.  
com

Received Date: 05 Feb 2018

Accepted Date: 07 Mar 2018

Published Date: 20 Mar 2018

#### Citation:

Aghajanzadeh M, Hemati H, Delshad MSE, Samidost P. Interpleural Ruptured Hydatid Cyst of Liver Presented as Pleural Effusion with Multiple Daughter Cysts. *Clin Surg.* 2018; 3: 1940.

**Copyright** © 2018 Aghajanzadeh M. This is an open access article distributed under the Creative Commons Attribution License, which permits unrestricted use, distribution, and reproduction in any medium, provided the original work is properly cited.

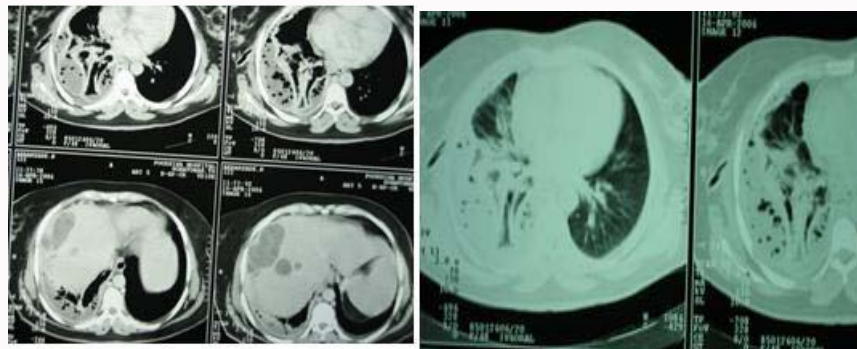


Figure 1 and 2: CT scan of chest showing pleural effusion with multiple air space lesion on the effusion, collapse of right lower lobe and chest-tube.

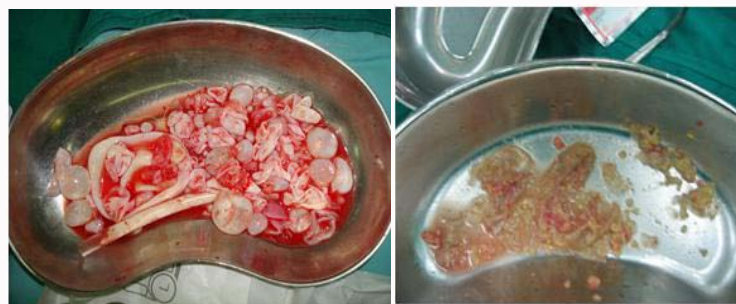

Figure 3 and 4: Showing resected specimen: Multiple of daughter cysts and laminated membrane.