



Integrated Septal Extension

Tiago Lyrio*

Department of Plastic Surgery, Instituto Ivo Pitanguy, Nascimento Silva, Brazil

Letter to the Editor

Dear editor of the Aesthetic Plastic Surgery Journal, one of the most laborious Rhinoplasty issues has been nasal tip projection and rotation control [1].

Nasal tip projection and its maintenance are considered a critical key to the suit result. The tip projection lies in some support elements such as medial crura length, domal approaches, columellar strut, and caudal septal extension [2-6].

The Septal Extension Graft (SEG) introduced by Byrd et al. [7]. In 1997, and its three variations, is a successful method for treating tip [1,8-10]. Moreover, with the refinements proposed by Toriumi D [11,12], and Davis R [13], it has gained worldwide popularity for its versatility and consistency. Two options for SEG fixation are available concerning the caudal septum: Overlapping placement using retention sutures or end-to-end placement using sutures in eight and to the septal dorsum above, through two cartilage expanders ("spreader grafting") for direct articulation with caudal L-Strut septal cartilage (tongue-in-groove) providing a very stable attachment. [14-16].

The author has proposed modifications to the SEG shape to address some of the issues presented by this technique [11,17,18]. Since 2019, the author has employed a new design SEG (Figure 1) in an appropriate fixation, to all structural open Rhinoplasty with the graft placed in a cephalic-caudal and anterior-posterior plane, to avoid rotation and maintenance of the tip position. A precise nasolabial angle, projection of the tip, and the infratip lobule definition seem to be obtained by the customized design of the graft. This integrated SEG (Figure 1) aim to reach an appropriated tip rotation and projection, avoiding tip deviation in a long-term result. The author believes that obtained better esthetic results, mainly at the supratip point, after using the integrated SEG due to the design of the angle pre-defined by the graft. An SEG is best performed with septal cartilage due

OPEN ACCESS

*Correspondence:

Tiago Lyrio, Department of Plastic Surgery, Instituto Ivo Pitanguy, Nascimento Silva, 309 - Ipanema, Rio de Janeiro-RJ, 22421-020, Brazil, Tel: 0055 21 982705949; E-mail: tiagolyrio@hotmail.com

Received Date: 08 Feb 2021

Accepted Date: 08 Mar 2021

Published Date: 26 Mar 2021

Citation:

Lyrio T. Integrated Septal Extension. Clin Surg. 2021; 6: 3112

Copyright © 2021 Tiago Lyrio. This is an open access article distributed under the Creative Commons Attribution License, which permits unrestricted use, distribution, and reproduction in any medium, provided the original work is properly cited.

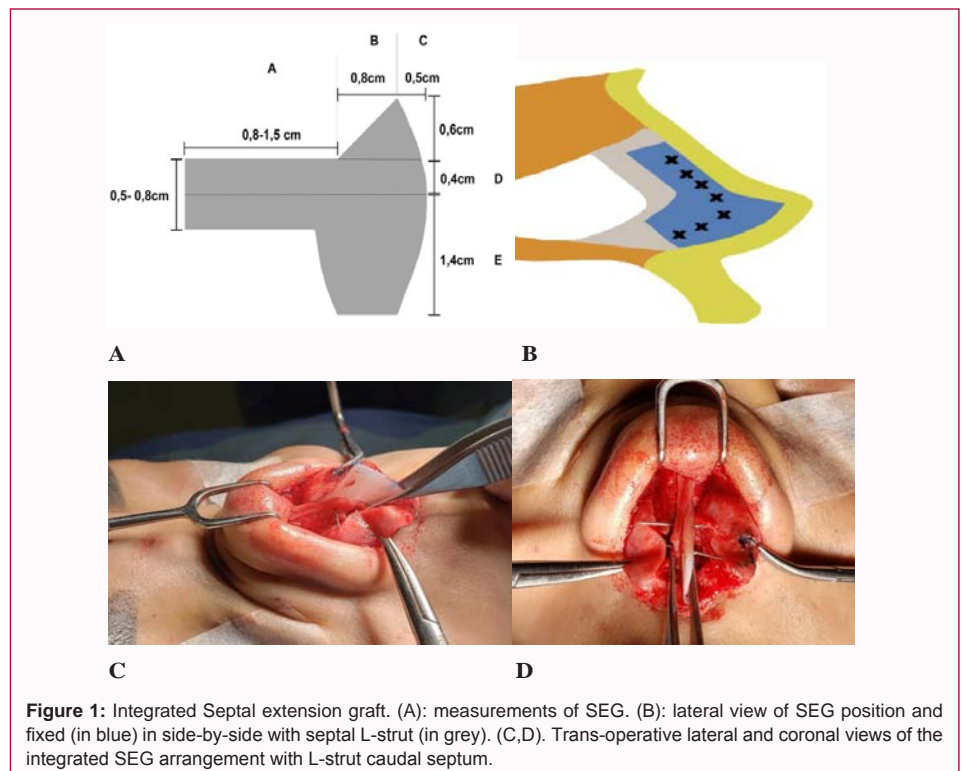


Figure 1: Integrated Septal extension graft. (A): measurements of SEG. (B): lateral view of SEG position and fixed (in blue) in side-by-side with septal L-strut (in grey). (C,D). Trans-operative lateral and coronal views of the integrated SEG arrangement with L-strut caudal septum.

to its size, flexibility, and resistance to longitudinal compression and shape deformation. The integrated SEG of the septal cartilage provides structural support for the central part of the nasal tip without the volume or instability associated with many other treatment strategies. It can be used to expand scarred or non-compliant nasal skin while preventing unwanted tip rotation due to high closure tension and/or post-operative contracture.

This newly designed SEG and its fixation has shown a promising approach to the nasal tip, achieving suitable and reproducible results, mainly in cases where tip projection and rotation are mandatory as well as to deviated caudal septum. This new SEG design plays an essential role in the surgical armamentarium of modern Rhinoplasty.

References

1. Sawh-Martinez R, Perkins K, Madari S, Steinbacher DM. Control of nasal tip position: Quantitative assessment of columellar strut versus caudal septal extension graft. *Plast Reconstr Surg.* 2019;144(5):772e-80e.
2. Pavri S, Zhu VZ, Steinbacher DM. Postoperative edema resolution following rhinoplasty: A three-dimensional morphometric assessment. *Plast Reconstr Surg.* 2016;138(6):973e-9e.
3. Rohrich RJ, Gunter JP, Deuber MA, Adams WP Jr. The deviated nose: Optimizing results using a simplified classification and algorithmic approach. *Plast Reconstr Surg.* 2002;110(6):1509-23.
4. American Society of Plastic Surgery. Plastic surgery statistics report. ASPS National Clearinghouse of Plastic Surgery Procedural Statistics. 2014.
5. Rohrich RJ, Hollier LH Jr, Janis JE, Kim J. Rhinoplasty with advancing age. *Plast Reconstr Surg.* 2004;114(7):1936-44.
6. Quatela VC, Pearson JM. Management of the aging nose. *Facial Plast Surg.* 2009;25(4):215-21.
7. Byrd HS, Andochick S, Copit S, Walton KG. Septal extension grafts: A method of controlling tip projection shape. *Plast Reconstr Surg.* 1997;100(4):999-1010.
8. Ha R, Byrd H. Septal extension grafts revisited: 6-year experience in controlling nasal tip projection and shape. *Plast Reconstr Surg.* 2003;112(7):1929-35.
9. Atighechi S, Sajadinejad B, Baradaranfar M, Dadgarnia M, Shahbazian H. Caudal extension graft versus columellar strut with plumping graft for acute nasolabial angle correction in rhinoplasty surgery. *Eur Arch Otorhinolaryngol.* 2015;272(7):1673-7.
10. Kim JH, Song JW, Park SW, Oh WS, Lee JH. Effective septal extension graft for asian rhinoplasty. *Arch Plast Surg.* 2014;41(1):3-11.
11. Toriumi DM. Caudal septal extension graft for correction of the retracted columella. *Oper Tech Otolaryngol Head Neck Surg.* 1995;6(4):311-18.
12. Toriumi DM, Checcone MA. New concepts in nasal tip contouring. *Facial Plast Surg Clin North Am.* 2009;17(1):55-90.
13. Davis R. Lateral crural tensioning for refinement of the wide and underprojected nasal tip: Rethinking the lateral crural steal. *Facial Plast Surg Clin North Am.* 2015;23(1):23-53.
14. Guyuron B, Varghai A. Lengthening the nose with a tongue-and-groove technique. *Plast Reconstr Surg.* 2003;111(4):1533-9.
15. Han Se, Han K, Choi J, Yun Tb. Modified direct-type septal extension grafts their stability and usefulness in Asian Rhinoplasty. *Ann Plast Surg.* 2017;78(3):243-8.
16. Lee Sh, Lee Hb, Kang ET. Nasal elongation with septal half extension graft: Modification of conventional septal extension graft using minimal septal cartilage. *Aesthetic Plast Surg.* 2018;42(6):1648-54.
17. Toriumi DM. New concepts in nasal tip contouring. *Arch Facial Plast Sur.* 2006;8(3):156-85.
18. Naficy S, Baker SR. Lengthening the short nose. *Arch Otolaryngol Head Neck Surg.* 1998;124(7):809-13.