



## Integrated Orthodontic-Surgical Management of Cleft lip and Palate Patients

Manisha Kamal Kukreja<sup>1\*</sup> and Virender Singh<sup>2</sup>

<sup>1</sup>Department of Orthodontics, PGIDS, UHS, India

<sup>2</sup>Department of Oral Surgery, PGIDS, UHS, India

### Clinical Image

Cleft lip and palate requires holistic interdisciplinary treatment approach. Reconstruction of alveolar cleft is an important part of rehabilitation of cleft palate patients. Secondary alveolar bone grafting is well accepted and preferred treatment modality which requires pre operative orthodontic maxillary alignment, expansion and stabilization and thereafter bone grafting of the alveolar cleft by the oral surgeon. Successful bone graft reconstruction of the alveolar cleft can result in positive outcomes for the patient.

Bone grafting has become a common procedure in the treatment of cleft lip and palate patients. According to its time of occurrence, the bone graft may be considered as primary, secondary, or tertiary (late). When performed during early childhood, at the same time as the primary repair surgeries, bone graft is called primary. Bone grafting is called secondary when performed later, at the end of the mixed dentition. A secondary bone graft is performed preferably before the eruption of the permanent canine in order to provide adequate periodontal support for the eruption and preservation of the teeth adjacent to the cleft. Grafted cancellous bone fills in the residual alveolar

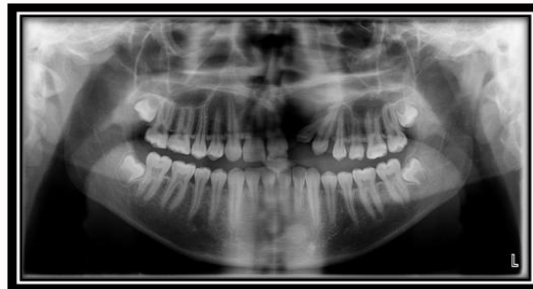

Figure 1: OPG of the patient showing maxillary alveolar cleft between left central and lateral incisors.

### OPEN ACCESS

#### \*Correspondence:

Manisha Kamal Kukreja, Department of Orthodontics, PGIDS, UHS, Rohtak, Haryana, India,

E-mail: mk3pgids@gmail.com

Received Date: 11 Feb 2019

Accepted Date: 15 Mar 2019

Published Date: 20 Mar 2019

#### Citation:

Kukreja MK, Singh V. Integrated Orthodontic-Surgical Management of Cleft lip and Palate Patients. Clin Surg. 2019; 4: 2370.

**Copyright** © 2019 Manisha Kamal Kukreja. This is an open access article distributed under the Creative Commons Attribution License, which permits unrestricted use, distribution, and reproduction in any medium, provided the original work is properly cited.

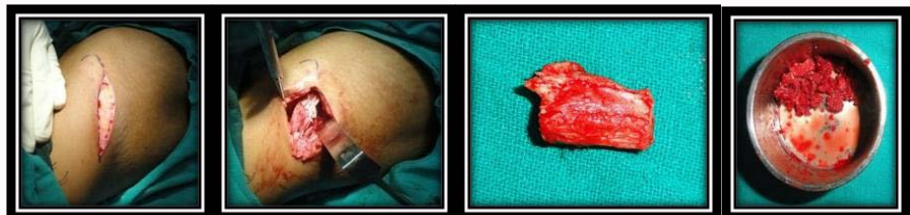


Figure 2: Harvesting Graft from donor site (Iliac crest).

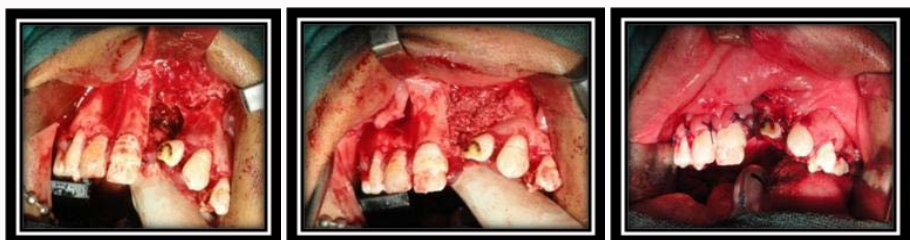

Figure 3: Bone grafting to recipient site.

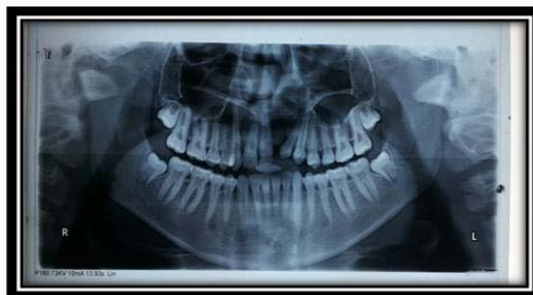

Figure 4: OPG showing filled alveolar defect.

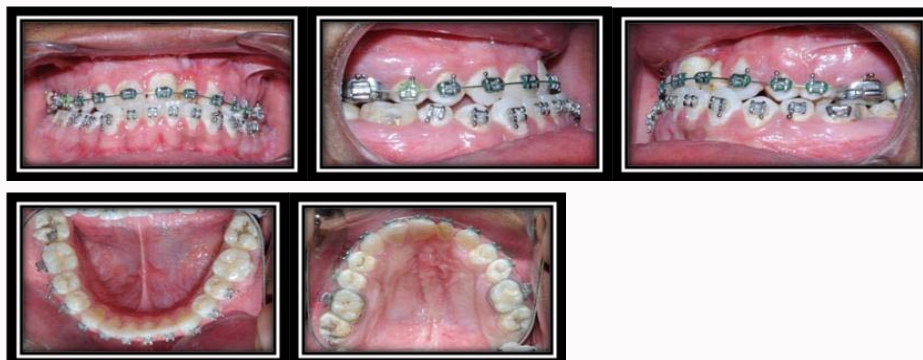

Figure 5: Intra-oral photographs showing pre-surgical decomposition of both arches.

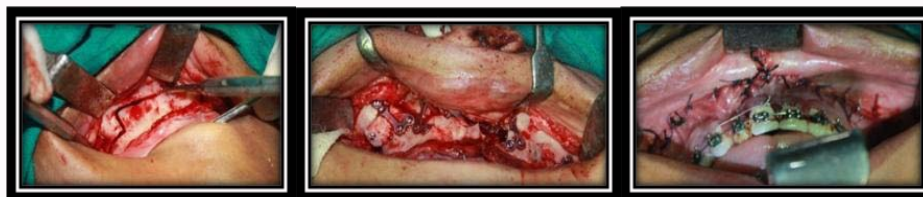

Figure 6: Intra-operative photographs showing Lefort 1 osteotomy with 4 mm maxillary advancement.

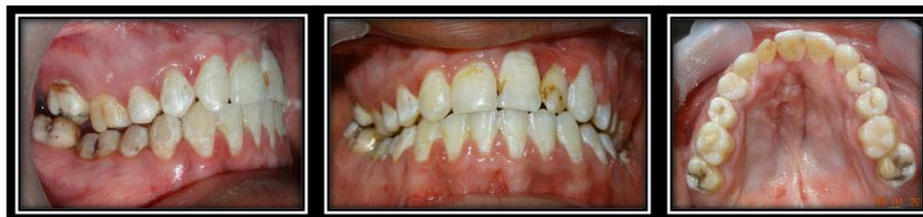

Figure 7: Post treatment occlusion.

cleft and is anatomically joined to the adjacent bone, becoming indistinguishable in radiographic images after an average period of 3 months [1].

From an orthodontic point of view, the most important benefit of secondary bone grafting is that the newly grafted bone acts as the alveolar bone, allowing for spontaneous migration of the adjacent canine toward the alveolar ridge. During the pre-bone graft orthodontic treatment, the upper dental arch is prepared for the graft and the permanent incisors are aligned whenever necessary. It involves predominantly transverse mechanics with the use of orthodontic or, preferably, orthopedic expansion during the mixed dentition in order to reposition the palatal segments. Three months

after the bone graft procedure, and depending on the radiographic image of the area, orthodontic treatment is restarted to correct the position of the permanent teeth. This phase involves movement of the teeth through the grafted area.

The benefits of secondary bone grafting into the alveolar clefts in patients with cleft lip and palate are manifold. Two of the most important benefits are:-

- Consistent method for stabilizing the maxillary segments and minimizing relapse.
- Providing bone support for tooth eruption, orthodontic movement and implant insertion.

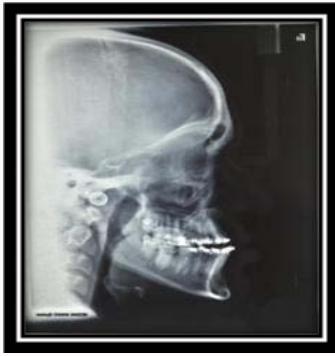

Figure 8: Pre treatment ceph.

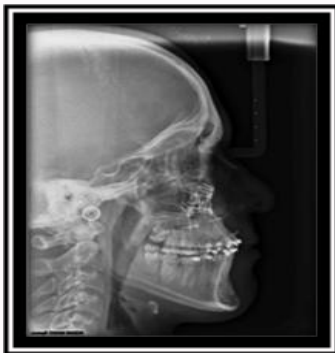

Figure 9: Post treatment ceph.

## Report of a Case (Secondary Alveolar Bone Grafting)

A 17-year-old patient reported to the Department of Orthodontics and Dento-facial Orthopedics with unilateral left repaired cleft lip and palate. Alveolar cleft remaining between left central incisor and lateral incisor. The radiographic feature of the patient depicted alveolar cleft between maxillary left central and lateral incisors (Figure 1).

After maxillary arch expansion by semi fixed Quad helix appliance, alveolar bone grafting was planned:-

- To provide a bony bridge to the cleft in the alveolus area.
- Alignment of lateral incisor and canine through cancellous bone.
- Orthodontic closure of cleft space will be possible therefore minimizing the need for prosthodontic rehabilitation.
- For stabilization of maxillary segments required especially during the orthognathic surgery.

The risks and benefits of this procedure were explained to the patient. Grafting procedure include preparation of recipient site, harvesting bone graft from iliac crest region (donor site) (Figure 2) and grafting the bone to the recipient site (Figure 3).

After healing period of 6 months filled alveolar defect can be seen radiographically (Figure 4).

This was followed by alignment of maxillary teeth and space closure in the bone graft area that is between left central and lateral incisors. The patient had skeletal class III malocclusion on account of retrognathic maxilla. Pre-surgical orthodontics for decomposition was done in both arches (Figure 5) followed by Lefort 1 osteotomy and 4 mm maxillary advancement to correct Class III Relationship (Figure 6). Post-surgical orthodontics included finishing and detailing with settling of occlusion [2]. One month after the surgery 0.19 × 0.25" stainless steel arch wires were placed with intermaxillary elastics in the posterior area to assist in the settlement of occlusion. After 22 months of treatment and once the objectives were achieved, it was decided to remove the appliance. At the end a skeletal class I relationship with molar in class 11 was achieved with favorable inclinations of upper and lower incisors.

## References

1. Shaw WC, Dahl E, Asher-McDade C, Brattström V, Mars M, McWilliam J, et al. Six center international study of treatment outcome in patients with cleft of lip and palate. *Cleft Palate Craniofac J.* 1992;29(5):413-8.
2. Chanchareonsook N, Whitehill TL, Samman N. Speech outcome and velopharyngeal function in cleft palate: comparison of Le Fort I maxillary osteotomy and distraction osteogenesis--early results. *Cleft Palate Craniofac J.* 2007;44(1):23-32.