



Innominate Versus Axillary Artery Cannulation for Aortic Surgery

Nikolaos G Baikoussis*, Stylianos Gaitanakis, Anna Dalipi-Triantafillou, Charilaos Kantsos, Vasileios Lozos and Konstaninos Triantafillou

Department of Cardiac Surgery, Ippokrateio General Hospital of Athens, Greece

Clinical Image

In this present paper we would like to compare the innominate artery cannulation with the axillary artery cannulation during surgery of the aorta for acute and chronic diseases. As we previously published [1], the innominate artery cannulation presents many advantages versus axillary artery cannulation. The innominate cannulation may be done in direct and in indirect fashion. We usually prefer the direct innominate cannulation during surgery for chronic aortic diseases as chronic aortic dissection, aortic aneurysms etc taken in consideration that the vessel wall is stable and consistent. In acute aortic syndrome; as in acute aortic dissection and in cases of intramural hematoma, we always perform the indirect innominate cannulation with the anastomoses of a synthetic graft of 8 mm of diameter. In patients with acute aortic dissection the diseases may be extended in carotids and innominate artery. In this condition the direct cannulation will be catastrophic. During the past years, the axillary cannulation was our vessel of choice for aortic surgery [2]. The arterial cannulation is a very interesting issue and the correct cannulation site has to be studied well preoperatively. The innominate artery cannulation according to the international bibliography is becoming very popular [1-5]. Other than the most common approach of the axillary arterial cannulation for aortic aneurysms and aortic dissections, Banbury and Cosgrove were the first to report the use of the innominate artery as a solution to the challenge of arterial cannulation with the interposition of an anastomosed graft [3]; the so-called indirect innominate cannulation. The main advantages of this technique are: firstly, the absence of a 2nd incision in the subclavian area. Secondly, it provides a higher flow rate without the need for higher pressure, because the innominate artery is larger than the axillary artery [1]. In addition, it enables blood pressure monitoring via the right radial artery during antegrade cerebral perfusion. Moreover, it avoids the brachial plexus injuries associated with axillary artery cannulation. This is a frequent and serious complication in axillary artery cannulation and has to be avoided. We would like to add some interesting advantages of the innominate artery cannulation like avoidance of injury of the subclavian vein and also avoidance of fluid collection (seroma) after axillary artery cannulation as in past has described [1,6]. Furthermore, the surgeon is able to perform the sternotomy before patient heparinization and additionally avoidance of arm ischemia other than the better cosmetic results. As previously mentioned, in our institution, we usually perform direct cannulation in elective patients with aneurysm of the ascending aorta, while we usually perform indirect cannulation in cases with acute aortic dissection with fragile vessel wall. In this, second condition we avoid the direct cannulation because of the risk to dissect the artery in proximity of its origin from the aortic arch. So, with the innominate artery partially clamped an 8-mm polytetrafluoroethylene or Dacron graft was anastomosed to that vessel in

OPEN ACCESS

*Correspondence:

Nikolaos G Baikoussis, Department of Cardiac Surgery, Ippokrateio General Hospital of Athens, 114 Vasilissis Sofias Avenue, Athens, Greece, Tel: 00306974201838; E-mail: nikolaos.baikoussis@gmail.com

Received Date: 08 Jul 2019

Accepted Date: 15 Aug 2019

Published Date: 21 Aug 2019

Citation:

Baikoussis NG, Gaitanakis S, Dalipi-Triantafillou A, Kantsos C, Lozos V, Triantafillou K. Innominate Versus Axillary Artery Cannulation for Aortic Surgery. Clin Surg. 2019; 4: 2554.

Copyright © 2019 Nikolaos G Baikoussis. This is an open access article distributed under the Creative Commons Attribution License, which permits unrestricted use, distribution, and reproduction in any medium, provided the original work is properly cited.

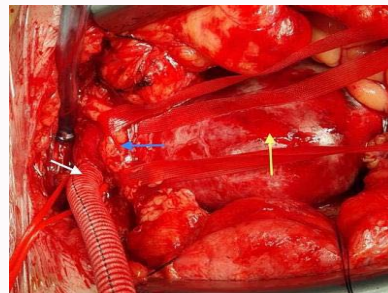


Figure 1: Innominate artery cannulation. An 8 mm graft is anastomosed to the artery for the arterial line cannulation (white arrow). The Innominate vein is preserved and taken in tapes (blue arrow). The dissected ascending aorta is seen (red arrow).

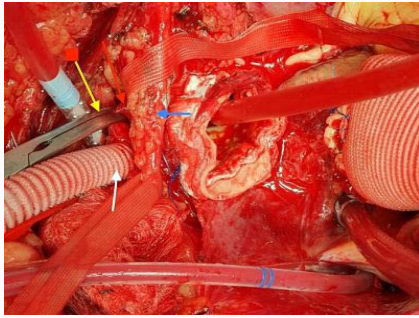


Figure 2: Innominate artery cannulation. An 8 mm graft is anastomosed to the artery for the arterial line cannulation (white arrow). The distal anastomosis is to be performed. The Innominate vein is preserved and taken in tapes (blue arrow). The innominate artery is clamped (yellow arrow).

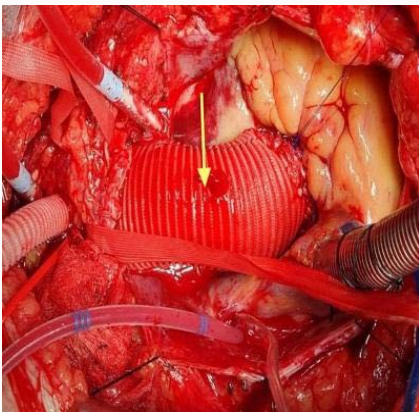


Figure 3: Innominate artery cannulation. The operation is finished and the dissected ascending aorta is replaced by a synthetic graft (yellow arrow). The innominate artery is declamped.

end-to-side fashion (Figures 1-3). Nevertheless, according to the bibliography and our opinion, innominate artery should not be cannulated if any of the following conditions exist: atherosclerosis at the base of the innominate artery, aneurysmal dilatation of the artery, redo sternotomy with the aorta in close proximity to the sternum, the necessity to initiate cardiopulmonary bypass before opening the sternum and type A acute aortic dissection extending to the innominate artery [1,3-5]. In conclusion, innominate artery cannulation, when feasible, is a safe, rapid and "qualified" standard technique mainly in ascending aorta and aortic arch surgery.

References

1. Gaitanakis S, Baikoussis NG, Triantafyllou K. Innominate Artery Cannulation as Standard Technique for Ascending Aorta and Aortic Arch Surgery. *Heart Lung Circ.* 2019;28(7):e119.
2. Siminelakis SN, Baikoussis NG, Papadopoulos GS, Beis IP. Axillary artery cannulation for cardiopulmonary bypass during surgery on the ascending aorta and arch. *J Card Surg.* 2009;24(3):301-4.
3. Banbury MK, Cosgrove DM 3rd. Arterial cannulation of the innominate artery. *Ann Thorac Surg.* 2000;69(3):957.
4. Berretta P, Alfonsi J, Di Bartolomeo R, Di Eusanio M. Innominate artery cannulation during aortic surgery. *Multimed Man Cardiothorac Surg.* 2015;12.
5. Yu Y, Gu T, Shi E, Yu L, Wang C. A technique modification in the cannulation of the innominate artery in the surgical treatment of aortic dissection. *J Cardiothorac Surg.* 2015;10(1):188.
6. Apostolakis EE, Baikoussis NG, Katsanos K, Karanikolas M. Postoperative peri-axillary seroma following axillary artery cannulation for surgical treatment of acute type A aortic dissection. *J Cardiothorac Surg.* 2010;5:43.