



Impaction of Canine Tooth after Alveolar Bone Graft in Patients with Cleft Lip and Palate: A Systematic Review

Marinho N¹, Leyendecker AJR¹, De Arruda AJA², Tanikawa DYS^{1,3,4}, Calasans-Maia M⁵ and Bueno DF^{1,3*}

¹Department of Surgery, Hospital Sírio Libanês, Brazil

²Department of Oral Surgery and Pathology, Universidade Federal de Minas Gerais, Brazil

³Department of Surgery, Hospital Municipal Infantil Menino Jesus, Brazil

⁴Department of Plastic Surgery, Universidade de São Paulo, Brazil

⁵Department of Oral Surgery, Universidade Federal Fluminense, Brazil

Abstract

Cleft Lip and Palate (CL/P) is the most common congenital facial malformation. One of the surgeries that need to be performed to CL/P rehabilitation is the alveolar bone graft which has as one of its functions to allow the eruption of the canine tooth. The aim of this study was to conduct a systematic review on articles that showed the rate of impacting permanent canine tooth in the alveolar cleft area after the secondary bone grafting surgeries in patients with CL/P. An electronic search with English-language studies was undertaken in the following databases: Medline/PubMed, Web of Science and Scopus. A total of 468 were selected and 119 were fully read and 35 fulfilled the inclusion criteria. The articles analyzed showed that the impacted canine tooth rate in the alveolar bone grafted region is not frequently reported after the secondary alveolar bone graft and a very wide variation in the canine impaction rate, ranging from 0% to 93.75%. Due to the risk of bias in the studies included in this literature review we observed that there is insufficient evidence to relate the impact rate of permanent canines after the alveolar bone graft with the type of bone source used or with the achievement of orthodontic maxillary expansion prior to the secondary bone graft.

OPEN ACCESS

*Correspondence:

Daniela Franco Bueno, Department of Surgery, Centro de Processamento Celular, Hospital Sírio-Libanês, Rua Adma Jafet 115, Bela Vista, São Paulo, SP, Brazil, Tel: +551133944177; E-mail: dbuenosp@gmail.com

Received Date: 08 Mar 2019

Accepted Date: 18 Apr 2019

Published Date: 23 Apr 2019

Citation:

Marinho N, Leyendecker AJR, De Arruda AJA, Tanikawa DYS, Calasans-Maia M, Bueno DF. Impaction of Canine Tooth after Alveolar Bone Graft in Patients with Cleft Lip and Palate: A Systematic Review. *Clin Surg*. 2019; 4: 2415.

Copyright © 2019 Bueno DF. This is an open access article distributed under the Creative Commons Attribution License, which permits unrestricted use, distribution, and reproduction in any medium, provided the original work is properly cited.

Introduction

Cleft Lip and Palate (CL/P) is the most common craniofacial malformation present at birth. Its worldwide incidence was estimated at 1:1,000, but varies according to the ethnicity, population studied, and geographic origin [1]. In Brazil, estimates of birth prevalence for CL/P ranged from 0.28 to 1.54:1,000 [2]. Brito et al., [3] demonstrated that the contribution of genetic factors to CL/P varies in different regions of Brazil, thus altering the prevalence among several regions of the country.

An essential step in the surgical treatment of CL/P is the reconstruction of the alveolar bone through the transplantation of a bone graft, usually an autogenous cancellous bone. Secondary Alveolar Bone Graft (SABG) became a well-established procedure since the original work of Boyne and Sands in 1972 [4]. Subsequently, Bergland et al., [5,6] suggested that the surgery should be performed at the mixed dentition stage after the specific orthodontic treatment, alignment and expansion of the dental arch of the maxilla. Several donor sites have already been used for the reconstruction of the alveolus, including iliac crest, calvaria, rib, tibia or mandible [4,7-10]. The iliac crest is considered the gold standard donor source of bone for alveolar reconstruction [11]. However, harvesting autologous bone grafts is associated with a greater morbidity. This morbidity can be eliminated through the use of tissue engineering strategies and growth factors [12-14].

One of the objectives of the Secondary Alveolar Bone Grafting (SABG) surgery is to promote the eruption of the permanent canine and, sometimes, the lateral incisor in the grafted region [15,16]. Other important functions are (1) stabilization of the maxilla, (2) closure of oro-nasal fistulas, (3) restoration of continuity of the dental arch, (4) improving the projection and symmetry of the upper lip, (5) providing periodontal support for the teeth adjacent to the alveolar cleft, (6) promote support for the base of the nose and (7) allow the installation of dental implants when indicated [4-6,17-21].

The success and outcome of SABG are evaluated by a variety of clinical, radiographic, and tomographic measurements. The Bergland scale, the Chelsea indices and the Kindelan indices are the most used for the quantification and location of the newly formed bone within the postoperative

grafted area [5,6,22]. However, few studies have used spontaneous eruption of the canine tooth or the lateral incisor tooth in the grafted region as one of the success factors.

The erupted canine tooth, with adequate periodontal support, allows closure of the orthodontic space and avoids the need for a final prosthesis [23]. However, a canine impaction rate exists even after SABG, which leads to the need for surgical exposure of the crown of the tooth and orthodontic traction of the canine tooth. According to the literature, the risk of impaction of the permanent upper canine in children with alveolar fissures is about 10 times to 20 times higher in comparison with the general population [24-27].

In the present review, the literature on SABG was examined to describe the frequency of canine tooth impaction in the grafted area in patients with complete unilateral or bilateral cleft palate who underwent SABG surgery, and to describe if there is a relationship between the bone source used for the graft and the canine tooth impaction. It will also be described if the maxillary expansion was made before the SABG.

Materials and Methods

This systematic review has been registered in the International Prospective Register of Systematic Reviews (PROSPERO) (CRD42018106571). The methodology of the study followed the recommendations of the Cochrane Handbook for Systematic Reviews of Interventions and the PRISMA-P protocol.

PRISMA-P protocol and the “focused question” was: what is the rate of impaction of the superior canine in patients with cleft lip and palate submitted to a secondary alveolar bone graft?

The primary outcome was the variable rate of maxillary canine impaction. The secondary endpoint was to evaluate the relationship between the graft material and previous orthodontic treatment with the canine impaction rate after bone grafting.

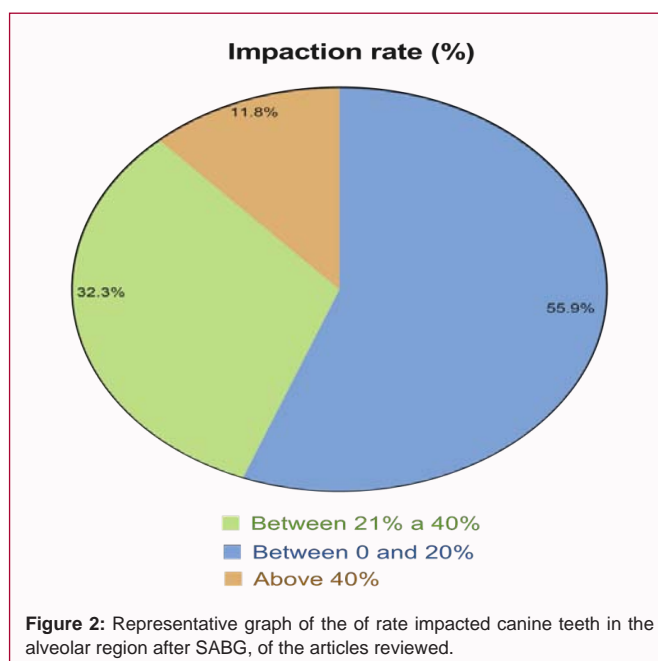
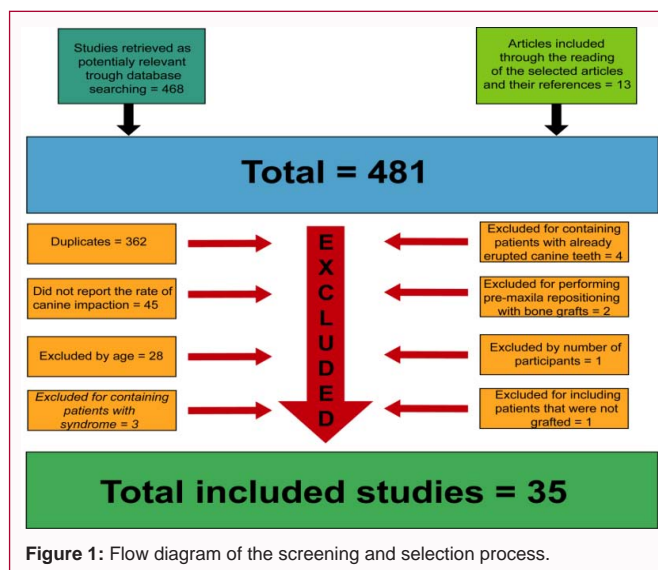
Information sources

In order to avoid the risk of selection bias, the inclusion of the study and the extraction of data were performed independently by two researchers (NM and AL Jr) and disagreements were resolved through discussion with the other authors. The other authors also performed a review of the articles selected and included in this review to ensure that all the studies included in this systematic review have comparable methodological quality and that the populations surveyed were also similar. The quality of all primary studies included in this systematic review was assessed by all researchers involved in this study and, as a result, only studies with plausible valid association results were included in this systematic review. The review authors were not blind to author(s), institution or publication site.

We selected randomized clinical trials, case-control studies, retrospective or prospective cohort studies, cross-sectional studies and case reports. Previous scientific literature review articles were not used in this review. The electronic databases used were: Medline/ PubMed, Web of Science and Scopus. The date of the last search was on 30/09/2018. Only English-language studies, defined in the database search, were selected. In addition, only articles published from 01/01/1987 were included in this review.

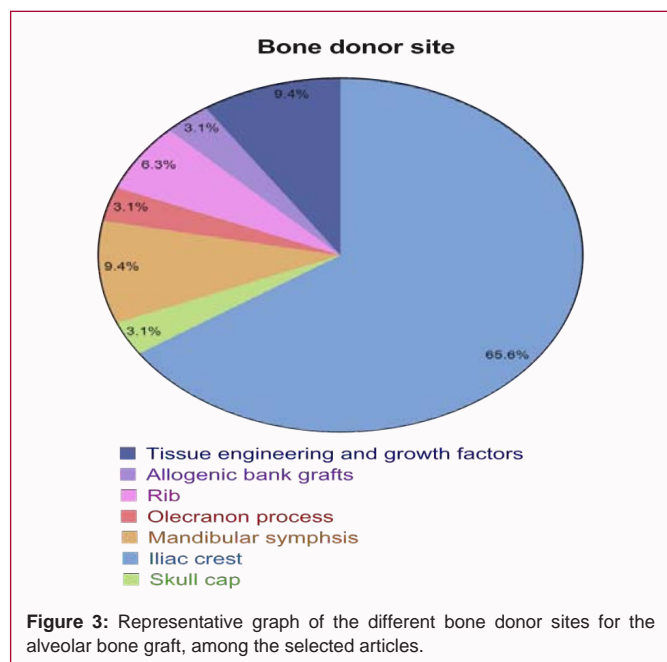
Search strategy

An electronic customized search of scientific articles published between 1984 and September 2018 using PubMed/Medline, Scopus



and Web of Science databases was conducted. The keywords used in the selection process were “((((((((((((((((((canine teeth) OR eruption of the canine) OR eruption of permanent canine) OR tooth eruption) OR impacting canine teeth) OR impacted canine teeth) OR impaction of the maxillary canine) OR canine impaction) OR canine tooth impacted) OR canine tooth impaction) OR canine teeth impacted) OR canine teeth impaction) OR canine eruption) OR maxillary impacted canines)) AND (((((((((((((((((bone transplantation) OR alveolar bone grafting) OR secondary alveolar bone grafting) OR secondary autogenous bone grafting) OR alveolar cleft repair) OR alveolar cleft grafting) OR alveolar reconstruction) OR autogenous bone graft) OR autogenous bone grafting) OR bone graft) OR secondary bone grafting)) AND (((((((((((((((((cleft palate) OR cleft lip) OR (cleft lip and palate)) OR (patients with cleft lip and palate)) OR patients with alveolar clefts) OR patients with clefts) OR cleft patients) OR alveolar cleft) OR alveolar clefts))”.

The possible eligible studies were preliminarily determined by reviewing the titles and abstracts of all studies resulting from the

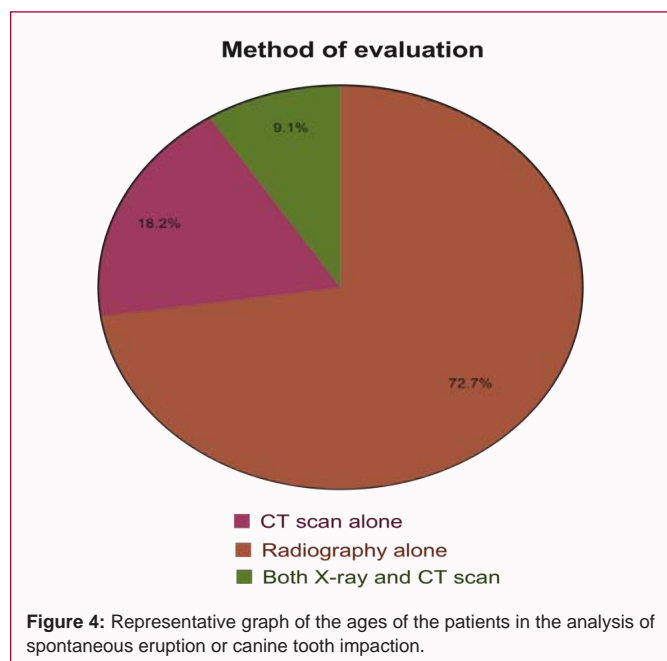


sample size less than or equal to five patients and studies that included patients with canines already erupted before the bone graft, that is, tertiary bone graft. Studies with postoperative evaluation with less than 6 months were also excluded.

Results

A total of 468 publications were identified through the search of electronic databases and 13 were searched manually, and 75 were duplicated, leaving 406 articles for the reading of titles and abstracts, of which 287 were excluded after screening.

Complete articles were obtained from the 119 remaining studies, while only 35 of them were considered eligible for review. The process of identification of the study is presented in Figure 1. Of the 35 eligible and selected studies, nine of them [27-34,57] had as their main outcome variable the evaluation of spontaneous eruption or canine impaction in the grafted area [27-37] (Table 1). All 26 other articles reported spontaneous impact or eruption rate within the results or discussion of the article. Regarding the age at which SABG was performed, in four studies the surgery was performed at an average age between six and eight years of age and in the other 31 studies the surgery was performed at an average age ranging from nine to 12 years [27,29,30,35].



The mean rate of impacted canine teeth in the alveolar region after SABG among the 35 articles reviewed was 22%, and 19 studies had an impaction rate between 0 % and 20%, 13 articles had an impaction rate between 21% and 40% and four articles had the impaction rate above 40%, graphically represented in Figure 2. There was no impaction of the canine tooth in the article by Alonso et al., [14], in which 16 patients were analyzed in total, eight in the group that used the iliac crest as the bone source and eight in the group that used growth factors (rhBMP-2).

A study by Lazarou et al., [31], which analyzed the success of bone grafting with the use of a calcium sulfate-based bone substitute, also did not observe canine tooth impaction in any of the 10 patients in the sample. The study by Newlands et al., [36] with 94 patients submitted

research. The full texts of the possible eligible studies were obtained for final judgment.

Selection criteria

For the inclusion of the articles in this review, we included articles in which individuals with bilateral or unilateral CP were submitted to the secondary alveolar bone graft, from autogenous, allogenic, heterogeneous bone source that used synthetic bone substitutes or growth factors, with varying age between six and 18 years. And the authors evaluated the frequency of eruption of the canine teeth that erupted spontaneously in the region of the alveolar cleft or that impacted and required surgery for surgical exposure of the crown.

Studies with syndromic CL/P patients and studies with bone grafts simultaneous to pre-maxilla osteotomy surgery were excluded from the review. In addition, other exclusion criteria used were a

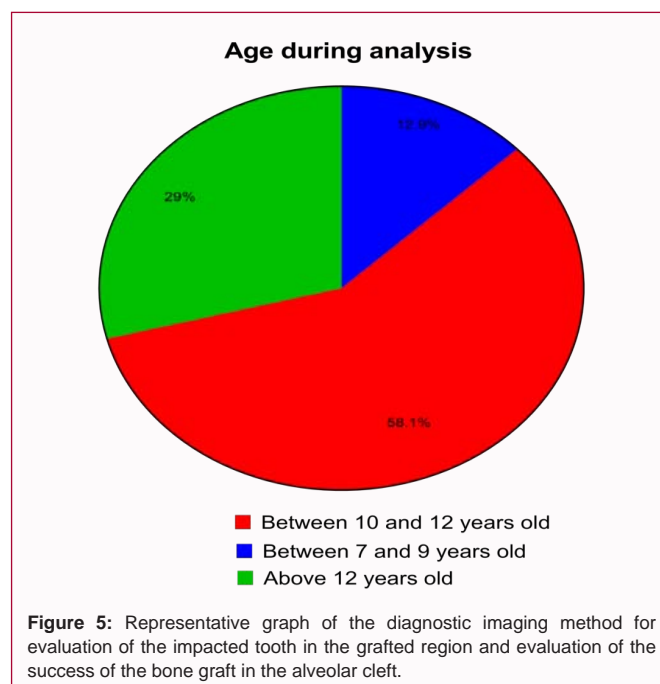


Table 1: Studies selected to be part of this manuscript.

Ref	Participants	Age of Graft (years) mean	Age min (years)	Age max (years)	Sex Fem	Sex Male	Study Type	Type of graft	Canine impaction rate	Anterior maxilla expansion	Type of cleft	Post operative exams	Evaluation of success	Post-operative evaluation time	Age at follow-up
[48]	61 (G1=39 and G2=22)	9.5	8	13.1	18	43	Retrospective study	Rib x mandibular symphysis	G1 13% G2 5%	Yes, those who needed	UC	X-ray	Degree of bone resorption, presence of complications, periodontal problems	1 year	Between 10 and 12 years
[8]	17	10.8	NR	NR	4	13	Retrospective study	Rib	29.40%	Yes, those who needed	UC	X-ray	Periodontal support and alveolar bone height	0.67 years	Between 10 and 12 years
[47]	24	12.75	9	16	NR	NR	Retrospective study	Allogeneic (bank)	17.40%	Yes, 50%	UC	X-ray	Periodontal evaluation/Canine/lateral eruption in the cleft region	3.1 years	Above 12 years
[40]	43	11	8.6	16.3	15	28	Retrospective study	Iliaccrest	5%	Yes, 100%	UC (29) and BC (14)	X-ray	Evaluation of alveolar bone crest	3.1 years	Between 10 and 12 years
[36]	94	10.5	8	18	25	47	Retrospective study	Iliaccrest	4%	Yes, 42%	UC (50) and BC (22)	X-ray	Evaluation of alveolar ridge crest and canine eruption	1 year	Above 12 years
[53]	14	9.1	6	16	4	10	Prospective study	Iliaccrest	21.42%	Yes, those Who needed	UC(11) and BC(3)	CT	Mean bone volume and canine eruption	1 year	Below 10 years
[29]	70	8,4	6,3	10,2	18	52	Retrospective study	Iliaccrest	9.20%	Yes, 58%	UC (64) BC (6)	X-ray	Canine/lateral eruption	4 years	Between 10 and 12 years
[28]	50	NR	8.83	15	18	32	Case Report	Iliaccrest	28%	Yes, those Who needed	UC	X-ray	Canineeruption	3 years	NR
[10]	101	9.83	NR	NR	29	72	Retrospective study	Mandibular symphysis x iliac crest	G1 35% G2 35%	Yes, 100%	UC (101)	X-ray	Relationship between marginal bone level and gingival condition.	0,5 years	Between 10 and 12 years
[54]	57	9	8	11	NR	NR	Prospective study	Iliaccrest	18%	Yes, those Who needed	46 UC and 11 BC	X-ray	Degree of bone resorption	3 years	Between 10 and 12 years
[34]	190	9.1	NR	NR	70	120	Retrospective study	Iliaccrest	18.90%	Yes, those Who needed	UC	X-ray	Canineeruption	0.5 to 22 years	NR
[39]	65	10.5	NR	NR	NR	NR	Retrospective study	Iliaccrest	5%	Yes, those Who needed	UC	X-ray	Berglandand Chelsea Scale	4 years	Above 12 years
[41]	16	10.5	NR	NR	9	7	Prospective study	Iliaccrest	93.75%	NR	UC	CT	Mean Bone Volume/STN-Zeiss Software	1 year	Between 10 and 12 years
[26]	116	12	4	20	NR	NR	Retrospective study	Iliaccrest	15.50%	Yes, those Who needed	UC (87) BC (29)	X-ray	Dental changes and eruption of the canines	5.8 years	Above 12 years
[51]	21	10.58	7,92	13,24	6	15	Prospective study	Iliaccrest	12%	Yes, those Who needed	UC(17) BC(4)	CT	Mean Bone Volume/Amira Software	1 year	Between 10 and 12 years
[14]	16 (G1=8 and G2=8)	9.5	8.41	11.5	7	9	Randomized Clinical Trial	Iliaccrest (8) x rhBMP-2 (8)	G1 0% G2 0%	Yes, those Who needed	UC	CT	Mean Bone Volume and mean bone height	1 year	Between 10 and 12 years
[35]	42	6.91	NR	NR	15	27	Prospective study	Mandibular symphysis	47.91%	Yes, those Who needed	UC(36) and BC(6)	X-ray + CT	Palatine vestibular bone width, Chelsea scale and canine/lateral eruption	0.5 years	Below 10 years
[32]	21	10.5	NR	NR	9	12	Retrospective study	Iliaccrest	12%	Yes, 100%	UC(17) and BC(4)	CT	Canine Eruption Path/Dolphin Software	1 year	Between 10 and 12 years
[42]	30	10.2	9	12	20	10	Randomized Clinical Trial	Iliac crest x hetero-geneous (bovine hydroxyapatite)	G1 50% G2 58%	Yes, those Who needed	UC (22) BC (8)	X-ray	Presence of complications and eruption of canines	2 years	Between 10 and 12 years
[46]	24	9.1	6	11	11	13	Retrospective study	Olecranon process	37.50%	Yes, 66,6%	UC (15) BC (9)	X-ray	Bergland scale and canine eruption	2 years	Between 10 and 12 years
[52]	47 (G1= 29 and G2=18)	10.32	8.9	13.5	24	23	Retrospective study	Mandibular symphysis x Mandibular symphysis + heterogeneous (beta-TCP)	G1 32.3% G2 18.2%	Yes, those Who needed	UC (32) BC (15)	X-ray	Canine eruption, presence of complications	1 year	Between 10 and 12 years
[45]	75	11.5	9	11	28	47	Retrospective study	Mandibular symphysis	33.30%	Yes, 100%	UC	Plaster Model	Goslon Yardstick analysis (study models)	1 year	NR
[56]	11	9.5	NR	NR	4	7	Retrospective study	Iliaccrest	25%	NR	UC (4) BC (7)	X-ray	Eruption of canines, occlusal relationship, trabecular bone formation, continuity and shape of the arch	1 year	Between 10 and 12 years

[31]	10	10.4	9	12	3	7	Prospective study	Synthetic (calcium sulphate)	0%	NR	UC	X-ray	Eruption of canines	5.1 years	Above 12 years
[43]	10	12.6	9	16	10	0	Prospective study	Iliac crest	50%	Yes, 50%	UC (8) BC (2)	X-ray	Evaluation of alveolar ridge crest and canine eruption	0.8 years	Above 12 years
[27]	68	8.5	NR	NR	19	49	Retrospective study	Iliac crest	20.60%	NR	UC	X-ray	Prevalence of impacted canines and factors associated with canine impaction	3 years	Below 10 years
[55]	40	8 to 12	8	12	NR	NR	Retrospective study	Iliac crest	32.50%	NR	UC (24) BC (16)	X-ray	Bergland scale and canine eruption	2 years	Between 10 and 14 years
[37]	40	9.15	NR	NR	16	24	Retrospective study	Iliac crest	5.20%	NR	UC	CT	Evaluation of mean bone graft survival/SimPlant Materialise Software	1 year	Between 10 and 12 years
[44]	27	9.04	8.63	9,45	9	18	Retrospective study	Cranial	6.25%	Yes, those Who needed	UC(22) and BC(5)	X-ray + CT	Enemark's classification and Method of Meazzini.	2 a 18.5 years	Above 12 years
[49]	11	10.4	8.8	11,6	NR	NR	Randomized Clinical Trial	rhBMP-7	9.09%	Yes, 72,72%	UC (9) BC (2)	X-ray	Kindelan Scale	0.5 years	Between 10 and 12 years
[30]	60	8	5	11	17	43	Retrospective study	Iliac crest	18.08%	Yes, 100%	UC	X-ray	Risk of canine impaction (early graft x late graft).	0.5 years	Below 10 years
[33]	24	9.25	NR	NR	NR	NR	Retrospective study	Iliac crest	12.50%	Yes, those Who needed	UC	X-ray or CT	Eruption of the canines, inclination and development of the canine root before and after EOAS.	0.5 years	Between 10 and 12 years
[50]	414 (93 G1=53 and G2=26)	11.5	NR	NR	176	238	Retrospective study	Iliac crest (216) x rhBMP (198)	G1(24.5%) G2 (19.2%)	Yes, those who needed	UC (G1=163 and G2=146) and BC (G1=53 and G2=52)	X-ray	Presence of complications and eruption of the canines.	G1 (4.1 years) G2 (2.9 years)	Above 12 years
[38]	56	10.66	NR	NR	24	32	Retrospective study	Iliac crest	5.40%	Yes, those Who needed	UC (48) and BC (8)	X-ray	Bergland scale, Kindelan and eruption of canines	1 year	Between 10 and 12 years
[57]	42	NR	9	16	19	23	Retrospective study	Iliac crest	33.33%	NR	UC (36) and BC (6)	X-ray	Eruption of canines	1 year	NR

NR: Not Reported; UC: Unilateral Cleft; BC: Bilateral Cleft

to bone grafting with iliac crest, presented a canine impaction rate of 4%. A 5% impaction rate was found in four reviewed articles and all four used iliac crest as a bone source: Oh et al., [37] with 40 patients in the sample; Kumar et al., [38] with 56 patients in the sample; Trindade et al., [39] with 65 patients; and a study by Long et al., [40] with 43 patients. Feichtinger et al., [41] found a high value of 94% of canine impaction rate in his study that was considered as discrepant compared to the other articles reviewed. The other studies that had a value above 40%, besides Feichtinger et al., [41], are Mikoya et al., [35] with 42 patients evaluated after alveolar grafting with mandibular symphysis bone with a 48% impaction rate, Thuaksuban et al., [42] with 30 patients divided into two groups, with a 50% rate in the iliac crest group and 58% in the association of the iliac crest with bovine hydroxyapatite, and Sharma et al., [43], who assessed 10 patients post-graft iliac crest and 50% canine impaction rate.

Regarding the bone donor site, 22 of the 35 studies reviewed used only the medullary bone of the anterior iliac crest. But other bone sources were found in the selected studies and evaluated the eruption of the canine, such as skull cap, mandibular symphysis, olecranon process, bank graft, bovine synthetic and bovine bone substitutes and growth factors (rhBMP), graphically represented in Figure 3. One study used only a skullcap graft from the parietal region and found a canine impaction rate of 6.25% [44]. Two studies used bone of the mandible of the symphysis region, Mikoya et al., [35] with a total of

42 patients, who presented a rate of 48%, and of Ruiter et al., [45] presented a 33.3% rate in 75 patients. The work of Witsenburg et al., [8] used rib, resulting in 29.4% canine impaction in 17 patients. Nadal et al., [46] used the olecranon process in 37.5% in 24 patients. Maxson et al., [47] used allogeneic bank grafts in 24 patients with a canine impaction rate of 17%. Borstlap et al., [48] compared rib graft in a group of 39 patients and mandibular symphysis graft in another group of 22 patients, the impaction rate in the rib group was 13% and in the mandibular symphysis group was 5%. Alonso et al., [14], Ayoub et al., [49] and Hammoudeh et al., [50] used tissue engineering with growth factors (rh-BMPs) in their studies, and obtained 0%, 9% and 19.2% of impacted canine rates, respectively.

Regarding the maxillary expansion prior to SABG surgery, 28 studies of the 35 selected refer in their studies that the patients were followed by an orthodontist and whenever necessary the expansion was performed [8,10,14,26,28-30,32-36,39,40,42-54]. Among the 29 studies, in five studies, 100% of patients underwent maxillary expansion [10,30,32,40,45]. Only seven out of 35 eligible articles did not report this information [27,31,37,41,55-57].

Among the studies selected, the analysis of spontaneous eruption or canine tooth impaction was performed in the age range of seven to nine years in four articles reviewed, between 10 and 12 years of age in 18 articles, and in ages above 12 years in nine revised articles as shown in Figure 4 [8,10,14,26,27,29-37,39-56].

In regard to the study design, three studies selected were randomized clinical trials, one case report article, seven prospective cohort articles, 24 retrospective cohort studies, and no case-control article [8,10,14,26-37,40-53,57].

The selected studies analyzed the success of alveolar bone grafting using scales using linear, angular measurements or three-dimensional measurements through X-ray examinations and/or CT scans. In 25 studies the evaluators used only radiographs to verify the success of the graft and the eruption of the tooth in the grafted area, in six studies the evaluators used only CT scans for this analysis, two studies used both X-rays and CT scans and in one study used radiographs in some patients and CT scans in other patients, as shown in Figure 5 [8,10,14,26,31-37,39-44,46-57].

The follow-up period for postoperative evaluation and analysis of the conditions of the canine/or lateral distal to the cleft ranged from 6-months to 22 years, and was 6-month in seven articles was 1-year follow-up in 12 articles and two or more years of follow-up in 15 articles [8,10,14,26-37,39-57].

Discussion

This systematic review included 35 studies evaluating spontaneous eruption or impaction of the canine tooth after the secondary bone graft in the treatment of patients with cleft lip and/or palate. Because many of the articles selected are prospective or retrospective cohort studies with relatively small sample sizes and often using descriptive outcome variables, these articles are at high risk of bias, and therefore the observed results should be treated with caution.

The iliac crest is the most commonly used donor site for the rehabilitation of patients with cleft lip and palate in the main treatment centers worldwide and is considered the gold standard [11]. The iliac crest graft was conducted in most of the studies analyzed that evaluated the postoperative success and the rate of eruption of the canine teeth [32,33,36,39,40,51,53]. This is because the iliac crest has enough bone to completely fill the alveolar cleft and at the same time it presents a large medullary portion with osteoinductive cells that accelerate the transformation of the grafted bone and it facilitates the eruption of the canine tooth. However, Enemark et al., [10], compared iliac crest and mandibular graft, and found no statistical difference in the success of the procedure and canine tooth impaction rates in both groups, with a value of approximately 35% impaction for both autogenous bone sources. In fact, the symphysis or mandibular branch region presents a smaller amount of medullary bone than the iliac crest, although they are intra-oral donor sites with lower morbidity than the iliac crest, and may be indicated in cases of small alveolar slits.

Other donor sites, such as the tibia, rib and skullcap, have also been used. Of the articles selected, only the study by Han et al., [44] used the skull cap as a bone source. The skull cap is less preferred as a donor site than the iliac crest because of its lower bone marrow content and mainly due to potential complications including dura mater lesions and subdural hemorrhages [11]. According to Han et al., [44], when only the external cortex is removed to collect the pure spongy bone, preserving the internal cortex, it avoids these complications, also increasing the chance of success of the graft.

The main benefit of using tissue engineering aided by growth factors rather than autogenous ones in SABG is the reduction of hospital stay time and the reduction of donor site morbidity [14].

Currently there is a growing search for a type of bone substitute ideal for SABG, which has osteoinductive, osteoconductive and osteogenic characteristics capable of forming a new bone with characteristics similar to the autogenous iliac crest bone. For this, the bone substitute is ideally bioabsorbable and mechanically stable in order to allow the canine to erupt over the grafted area without any type of barrier [50]. In this review, studies by Alonso et al., [14], Ayoub et al., [49] and Hammoudeh et al., [50] used tissue engineering with growth factors (rh-BMPs) for the reconstruction of alveolar clefts, obtaining good results in the analysis of the bone formation and eruption of the canine teeth through the graft.

Thus, one of the main objectives of SABG is to allow the eruption of the canine at the cleft/cleft site to avoid or minimize the need for prosthetic rehabilitation, hence the importance of this review in assessing the frequency of spontaneous eruption or impacting canine teeth. It has been observed through this systematic review that the eruption of the canine through the bone graft can occur spontaneously when well planned, that is, the right moment and age and well-conducted pre-surgical orthodontics [14,31].

On the other hand, the study by Feichtinger et al., [41], which used iliac crest in 16 patients with unilateral cleft, maxillary canine impaction rate was approximately 94%, considered to be discrepant and out of the mean of the set of reviewed articles, but the authors did not mention whether there was previous orthodontics. Despite this, the results of Feichtinger et al., [41] in the evaluation of success were positive regarding the volume of bone formed after one year of follow-up, measured by tomographic analysis.

Even with adequate planning and all the correct conduits, there is a greater risk of impacting or retaining maxillary canines in patients with cleft lip and palate than in the general population [25]. In the article by Enemark et al., [10], the authors indicate that the greater impaction in these patients may be associated with the effects of primary surgeries performed in early childhood, but to date there is no study to prove this relationship.

The treatment of an impacted canine usually involves a surgical approach to expose the crown, attach an orthodontic appliance to the crown, and perform orthodontic movement to correct position or remove the tooth, making treatment more time-consuming and costly [58]. It is believed that the time to wait for spontaneous canine eruption through the graft is approximately 2-years, so the 6-months period may have been insufficient for this evaluation in some revised articles which is based on the results obtained in the present study [8,10]. Another important issue to be evaluated is the time of analysis of the spontaneous eruption of canine teeth. The normal age of spontaneous eruption of the maxillary permanent canines in patients who do not have CP is in the age range of 11 years to 12 years, so the correct thing is to analyze and consider only canine impaction rates in patients submitted to SABG surgery, who were evaluated postoperatively with age above 12-years [26,31,36,39,43,44,47,50,55,59].

On the other hand, Matsui et al., [34] argue that early surgical exposure is necessary to correct inadequate angulations and large deviations of canines when detected radio graphically after SABG, less than 11 years of age, to take advantage of eruptive capacity, and spontaneous eruption should not be expected in these cases, as it would result in higher rates of impaction without success of orthodontic traction.

One factor that may be associated with the risk of impacting canines is the size of the alveolar cleft, as also observed by Matsui et al., [34], where the results suggested that the width of the nasal side cleft is related to the need for surgical exposure of permanent canines in children with cleft lip and/or palate. Another factor that may be associated with the risk of impaction and need for surgical exposure of the canine crown is the inclination of the long axis of the canine in relation to an imaginary vertical line parallel to the median sagittal line, which some authors affirm that the larger this greater slope is the risk of impaction, however, according to the study by Vellone et al., [33], there is no relation between the inclination and the risk of impaction of the canine, with a result of 87.5% of the cases that presented spontaneous eruption of the canine and 12.5% required exposure and orthodontic traction.

The authors of the selected studies agree that the ideal period of bone grafting is between eight and twelve year of age in the mixed dentition period, which is a phase that does not affect the growth of the maxillary complex and allows the correct eruption of the canine tooth or lateral when this tooth is distal to the cleft. Thus, 28 articles were excluded from the review because they included in their studies adolescent patients above 16 years of age and young adults, therefore being submitted to tertiary or late bone grafting, since from that age the canine is normally with the complete formation of the root and the apex closed, hindering the spontaneous eruption of the canine tooth. In addition, tertiary alveolar bone graft procedures are related to a high percentage of failure essentially due to the difficulty of closing the oro-nasal fistulas and bone resorption of the teeth facing the slit, needing to be studied and evaluated separately.

In the studies included in the review, no relation was observed between the mean age at which SABG was performed and the frequency of canine impaction. Kleipoort et al., [30] was the only one of those selected who demonstrated in their study that early secondary alveolar bone graft (prior to eruption of permanent incisor teeth) did not modify the risk of permanent maxillary canine impingement compared to graft prior to maxillary canine eruption (14.29% and 21.88%, respectively, without significant statistical difference) and regardless of the presence or absence of permanent lateral incisor agenesis.

Conclusion

According to this literature review, it was observed that the canine teeth impaction rate is not frequently cited in the results for the evaluation of SABG success. In addition, due to the high risk of bias in the included studies, sufficient evidence was not found to relate the impacting rate of permanent canines to the type of bone source used or to the maxillary expansion prior to grafting. Therefore, this review opens new perspectives for studies on the evaluation of canine rash status to be performed after SABG in patients with CP. In addition, it would serve to better understand the causes of impacting canine teeth in this type of patient and in this way minimize these factors, as well as reduce the need for surgeries for coronary exposure and orthodontic traction.

References

- Carinci F, Scapoli L, Palmieri A, Zollino I, Pezzetti F. Human genetic factors in nonsyndromic cleft lip and palate: an update. *Int J Pediatr Otorhinolaryngol.* 2007;71(10):1509-19.
- Menegotto BG, Salzano FM. Epidemiology of oral clefts in a large South American sample. *Cleft Palate Craniofac J.* 1991;28(4):373-6.
- Brito LA, Cruz LA, Rocha KM, Barbara LK, Silva CB, Bueno DF, et al. Genetic contribution for non-syndromic cleft lip with or without cleft palate (NS CL/P) in different regions of Brazil and implications for association studies. *Am J Med Genet A.* 2011;155A(7):1581-87.
- Boyne PJ, Sands NR. Secondary bone grafting of residual alveolar and palatal clefts. *J Oral Surg.* 1972;30(2):87-92.
- Bergland O, Semb G, Abyholm F, Borchgrevink H, Eskeland G. Secondary bone grafting and orthodontic treatment in patients with bilateral complete clefts of the lip and palate. *Ann Plast Surg.* 1986;17(6):460-74.
- Bergland O, Semb G, Abyholm FE. Elimination of the residual alveolar cleft by secondary bone grafting and subsequent orthodontic treatment. *Cleft Palate J.* 1986;23(3):175-205.
- LaRossa D, Buchman S, Rothkopf DM, Mayro R, Randall P. A comparison of iliac and cranial bone in secondary grafting of alveolar clefts. *Plast Reconstr Surg.* 1995;96(4):789-97.
- Witsenburg B, Peter H, Freihofer M. Autogenous rib graft for reconstruction of alveolar bone defects in cleft patients. Long-term follow-up results. *J Craniomaxillofac Surg.* 1990;18(2):55-62.
- Kalaaji A, Lilja J, Elander A, Friede H. Tibia as donor site for alveolar bone grafting in patients with cleft lip and palate: long-term experience. *Scand J Plast Reconstr Surg Hand Surg.* 2001;35(1):35-42.
- Enemark H, Jensen J, Bosch C. Mandibular bone graft material for reconstruction of alveolar cleft defects: long-term results. *Cleft Palate Craniofac J.* 2001;38(2):155-63.
- Santiago PE, Schuster LA, Levy-Bercowski D. Management of the alveolar cleft. *ClinPlast Surg.* 2014;41(2):219-32.
- Herford AS, Boyne PJ, Rawson R, Williams RP. Bone morphogenetic protein-induced repair of the premaxillary cleft. *J Oral Maxillofac Surg.* 2007;65(11):2136-41.
- Dickinson BP, Ashley RK, Wasson KL, O'Hara C, Gabbay J, Heller JB, et al. Reduced morbidity and improved healing with bone morphogenetic protein-2 in older patients with alveolar cleft defects. *Plast Reconstr Surg.* 2008;121(1):209-17.
- Alonso N, Tanikawa DY, Freitas Rda S, Canan L Jr, Ozawa TO, Rocha DL. Evaluation of maxillary alveolar reconstruction using a resorbable collagen sponge with recombinant human bone morphogenetic protein-2 in cleft lip and palate patients. *Tissue Eng Part C Methods.* 2010;16(5):1183-9.
- Amanat N, Langdon JD. Secondary alveolar bone grafting in clefts of the lip and palate. *J Craniomaxillofac Surg.* 1991;19(1):7-14.
- Long RE Jr, Semb G, Odont, Shaw WC. Orthodontic Treatment of the Patient with Complete Clefts of Lip, Alveolus, and Palate: Lessons of the past 60 Years. *Cleft Palate Craniofac J.* 2000;37(6):1-13.
- Kalaaji A, Lilja J, Friede H, Elander A. Bone grafting in the mixed and permanent dentition in cleft lip and palate patients: long-term results and the role of the surgeon's experience. *J Craniomaxillofac Surg.* 1996;24(1):29-35.
- Lilja J, Möller M, Friede H, Lauritzen C, Petterson LE, Johanson B. Bone grafting at the stage of mixed dentition in cleft lip and palate patients. *Scand J Plast Reconstr Surg Hand Surg.* 1987;21(1):73-9.
- Sullivan KO. Tooth eruption in the bone-grafted maxillary cleft alveolus. *Int J Oral Surg.* 1981;10(1):309-12.
- Enemark H, Krantz-Simonsen E, Schramm JE. Secondary bonegrafting in unilateral cleft lip palate patients: indications and treatment procedure. *Int J Oral Surg.* 1985;14(1):2-10.
- Kalaaji A1, Lilja J, Friede H. Bone grafting at the stage of mixed and permanent dentition in patients with clefts of the lip and primary palate. *Plast Reconstr Surg.* 1994;93(4):690-6.
- Kindelan JD, Nashed RR, Bromige MR. Radiographic assessment of

- secondary autogenous alveolar bone grafting in cleft lip and palate patients. *Cleft Palate Craniofac J*. 1997;34(3):195-8.
23. Ramstad T, Semb G. The effect of alveolar bone grafting on the prosthodontic/reconstructive treatment of patients with unilateral complete cleft lip and palate. *Int J Prosthodont*. 1997;10(2):156-63.
 24. Peck S, Peck L, Kataja M. Prevalence of tooth agenesis and peg-shaped maxillary lateral incisor associated with palatally displaced canine (PDC) anomaly. *Am J Orthod Dentofacial Orthop*. 1996;110(4):441-3.
 25. Russell KA, McLeod CE. Canine eruption in patients with complete cleft lip and palate. *Cleft Palate Craniofac J*. 2008;45(1):73-80.
 26. Tortora C, Meazzini MC, Garattini G, Brusati R. Prevalence of abnormalities in dental structure, position, and eruption pattern in a population of unilateral and bilateral cleft lip and palate patients. *Cleft Palate Craniofac J*. 2008;45(2):154-62.
 27. Westerlund A, Sjöström M, Björnström L, Ransjö M. What factors are associated with impacted canines in cleft patients? *J Oral Maxillofac Surg*. 2014;72(11):2109-14.
 28. Da Silva Filho OG, Teles SG, Ozawa TO, Filho LC. Secondary bone graft and eruption of the permanent canine in patients with alveolar clefts: literature review and case report. *Angle Orthod*. 2000;70(2):174-8.
 29. Lilja J, Kalaaji A, Friede H, Elander A. Combined bone grafting and delayed closure of the hard palate in patients with unilateral cleft lip and palate: facilitation of lateral incisor eruption and evaluation of indicators for timing of the procedure. *Cleft Palate Craniofac J*. 2000;37(1):98-105.
 30. Kleinpoort F, Ferchichi H, Belkhou A, Tramini P, Bigorre M, Captier G. Early secondary bone grafting in children with alveolar cleft does not modify the risk of maxillary permanent canine impaction at the age of 10 years. *J Craniomaxillofac Surg*. 2017;45(4):515-9.
 31. Lazarou SA, Contodimos GB, Gkegkes ID. Correction of alveolar cleft with calcium-based bone substitutes. *J Craniofac Surg*. 2011;22(3):854-7.
 32. Oberoi S, Gill P, Chigurupati R, Hoffman WY, Hatcher DC, Vargervik K. Three-dimensional assessment of the eruption path of the canine in individuals with bone-grafted alveolar clefts using cone beam computed tomography. *Cleft Palate Craniofac J*. 2010;47(5):507-12.
 33. Vellone V, Cirignaco G, Cavarretta B, Cascone P. Canine Eruption After Secondary Alveolar Bone Graft in Unilateral Cleft Lip and Palate Patients. *J Craniofac Surg*. 2017;28(5):1206-10.
 34. Matsui K, Echigo S, Kimizuka S, Takahashi M, Chiba M. Clinical study on eruption of permanent canines after secondary alveolar bone grafting. *Cleft Palate Craniofac J*. 2005;42(3):309-13.
 35. Mikoya T, Inoue N, Matsuzawa Y, Totsuka Y, Kajii TS, Hirose T. Monocortical mandibular bone grafting for reconstruction of alveolar cleft. *Cleft Palate Craniofac J*. 2010;47(5):454-68.
 36. Newlands LC. Secondary alveolar bone grafting in cleft lip and palate patients. *Br J Oral Maxillofac Surg*. 2000;38(5):488-91.
 37. Oh TS, Park JS, Choi JW, Kwon SM, Koh KS. Risk factor analysis of bone resorption following secondary alveolar bone grafting using three-dimensional computed tomography. *J Plast Reconstr Aesthet Surg*. 2016;69(4):487-92.
 38. Kumar R, Heggie A, Shand J, Dominguez-Gonzalez S, Kilpatrick N, Shah J. Secondary bone grafting of alveolar clefts: a review of outcome at two centres in Australia and the UK. *Br J Oral Maxillofac Surg*. 2017;55(5):496-9.
 39. Trindade IK, Mazzottini R, Silva Filho OG, Trindade IE, Deboni MC. Long-term radiographic assessment of secondary alveolar bone grafting outcomes in patients with alveolar clefts. *Oral Surg Oral Med Oral Pathol Oral Radiol Endod*. 2005;100(3):271-7.
 40. Long RE Jr, Paterno M, Vinson B. Effect of cuspid positioning in the cleft at the time of secondary alveolar bone grafting on eventual graft success. *Cleft Palate Craniofac J*. 1996;33(3):225-30.
 41. Feichtinger M, Mossböck R, Kärcher H. Evaluation of bone volume following bone grafting in patients with unilateral clefts of lip, alveolus and palate using a CT-guided three-dimensional navigation system. *J Craniomaxillofac Surg*. 2006;34(3):144-9.
 42. Thuaksuban N, Nuntanarant T, Pripatnanont P. A comparison of autogenous bone graft combined with deproteinized bovine bone and autogenous bone graft alone for treatment of alveolar cleft. *Int J Oral Maxillofac Surg*. 2010;39(12):1175-80.
 43. Sharma S, Rao DJ, Majumder K, Jain H. Secondary alveolar bone grafting: Radiographic and clinical evaluation. *Ann Maxillofac Surg*. 2012;2(1):41-5.
 44. Han K, Park J, Choi J, Son D. Long-term outcomes of simplified gingivoperiosteoplasty performed at the time of hard palatal closure: A review of 55 alveolar clefts. *J Plast Reconstr Aesthet Surg*. 2016;69(11):e217-e24.
 45. De Ruiter A, van der Bilt A, Meijer G, Koole R. Orthodontic treatment results following grafting autologous mandibular bone to the alveolar cleft in patients with a complete unilateral cleft. *Cleft Palate Craniofac J*. 2010;47(1):35-42.
 46. Nadal E, Sabás M, Dogliotti P, Espósito R. Secondary alveolar bone grafting: our experience with olecranon bone graft. *J Craniofac Surg*. 2010;21(2):371-4.
 47. Maxson BB, Baxter SD, Vig KW, Fonseca RJ. Allogeneic bone for secondary alveolar cleft osteoplasty. *J Oral Maxillofac Surg*. 1990;48(9):933-41.
 48. Borstlap WA, Heidbuchel KL, Freihofer HP, Kuijpers-Jagtman AM. Early secondary bone grafting of alveolar cleft defects. A comparison between chin and rib grafts. *J Craniomaxillofac Surg*. 1990;18(5):201-5.
 49. Ayoub A, Roshan CP, Gillgrass T, Naudi K, Ray A. The clinical application of rhBMP-7 for the reconstruction of alveolar cleft. *J Plast Reconstr Aesthet Surg*. 2016;69(1):101-7.
 50. Hammoudeh JA, Fahradyan A, Gould DJ, Liang F, Imahiyerobo T, Urbinelli L, et al. A Comparative Analysis of Recombinant Human Bone Morphogenetic Protein-2 with a Demineralized Bone Matrix versus Iliac Crest Bone Graft for Secondary Alveolar Bone Grafts in Patients with Cleft Lip and Palate: Review of 501 Cases. *Plast Reconstr Surg*. 2017;140(2):318-25.
 51. Oberoi S, Chigurupati R, Gill P, Hoffman WY, Vargervik K. Volumetric assessment of secondary alveolar bone grafting using cone beam computed tomography. *Cleft Palate Craniofac J*. 2009;46(5):503-11.
 52. Weijs WL, Siebers TJ, Kuijpers-Jagtman AM, Bergé SJ, Meijer GJ, Borstlap WA. Early secondary closure of alveolar clefts with mandibular symphyseal bone grafts and beta-tri calcium phosphate (beta-TCP). *Int J Oral Maxillofac Surg*. 2010;39(5):424-9.
 53. Tai CC, Sutherland IS, McFadden L. Prospective analysis of secondary alveolar bone grafting using computed tomography. *J Oral Maxillofac Surg*. 2000;58(11):1241-9.
 54. Schultze-Mosgau S, Nkenke E, Schlegel AK, Hirschfelder U, Wiltfang J. Analysis of bone resorption after secondary alveolar cleft bone grafts before and after canine eruption in connection with orthodontic gap closure or prosthodontic treatment. *J Oral Maxillofac Surg*. 2003;61(11):1245-8.
 55. Gaujac C, De Souza Faco EF, Shinohara EH, de Souza Faco RA, Pereira FP, Assunção WG. Influence analysis of cleft type and supernumerary teeth eruption in the prognosis of bone graft in patients with cleft palate. *J Craniofac Surg*. 2014;25(5):408-11.
 56. Walia A. Secondary alveolar bone grafting in cleft of the lip and palate patients. *Contemp Clin Dent*. 2011;2(3):146-54.
 57. Antunes CL, Aranha AM, Bandeca MC, de Musis CR, Borges ÁH, Vieira EM. Eruption of Impacted Teeth after Alveolar Bone Graft in Cleft Lip and

- Palate Region. *J Contemp Dent Pract*. 2018;19(8):933-6.
58. Becker A, Chaushu S. Etiology of maxillary canine impaction: a review. *Am J Orthod Dentofacial Orthop*. 2015;148(4):557-67.
59. Kuijpers MA, Chiu YT, Nada RM, Carels CE, Fudalej PS. Three-dimensional imaging methods for quantitative analysis of facial soft tissues and skeletal morphology in patients with orofacial clefts: a systematic review. *PLoS One*. 2014;9(4):93442.