



# Imaging Criterion for Responsibility Segment of Cervical Myelopathy

Bolong Zheng, Dingjun Hao, Zhen Chang and Baorong He\*

Department of Spine Surgery, Xi'an Jiaotong University, China

## Abstract

**Purpose:** Explore the most appropriate combination of four MRI parameters (signal intensity on T2WI, cord/dura sagittal ratio, cord/dura area ratio, cord deformation ratio) as the imaging criterion for cervical myelopathy to achieve the highest sensitivity and specificity.

**Material and Methods:** From February 2011 to August 2013, One hundred and thirty patients with single segmental cervical myelopathy were chosen from the patient data base of our hospital, male/female ratio was 11/9, the average age was  $48.62 \pm 10.02$  years (ranged 37~54 years), the average course of disease was  $6.51 \pm 4.33$  months (ranged 4.1~10.2 months). Through measuring the preoperative MRI images with PACS software, the cut-off points of signal intensity on T2WI, cord/dura sagittal ratio, cord/dura area ratio, cord deformation ratio were calculated respectively using 100 patients according to Receiver Operating Characteristic (ROC). After testing the effectiveness of these four cut-off points, the most appropriate combination of these four parameters as the imaging criterion of cervical myelopathy was explored by the rest 30 patients through calculate the sensitivity, specificity and Youden index of each possible combination.

**Results:** The cut-off points of signal intensity on T2WI, cord/dura sagittal ratio, cord/dura area ratio and cord deformation ratio were 1, 0.77, 0.61 and 0.46 respectively according to Receiver Operating Characteristic (ROC), and Youden index of these four cut-off points were 0.72, 0.67, 0.63 and 0.48, respectively, with all in acceptable range. Through comparing each possible combination with one another, the most appropriate combination was: T2WI  $\geq 1$  or (cord/dura sagittal ratio  $\geq 0.77$  and cord/dura area ratio  $\geq 0.61$  and cord deformation ratio  $\leq 0.46$ ), with corresponding sensitivity =0.97, specificity =0.89, Youden index =0.86, PPV (Positive Predictive Value) =0.74, NPV (Negative Predictive Value) =0.99, showing a satisfying diagnostic imaging criterion for cervical myelopathy.

**Conclusion:** When using T2WI  $\geq 1$  or (cord/dura sagittal ratio  $\geq 0.77$  and cord/dura area ratio  $\geq 0.61$  and cord deformation ratio  $\leq 0.46$ ) as the diagnostic imaging criterion of cervical myelopathy, the sensitivity and the specificity are both high. It's a useful assistant tool for spine surgeons better decide the responsibility segment and boost the accuracy of surgical decompression, but the scope of application should be evaluated prudently.

**Keywords:** Cervical myelopathy; Responsibility segment; Diagnostic test; Youden index; ROC curve

## Introduction

The etiology of cervical myelopathy is the degeneration of cervical spine, which usually begins with intervertebral disc. So far, several theories of the pathogenesis have been proposed, including static compression [1-4], dynamic compression [5-7], spinal cord deformation [6], spinal cord blood supply [6,7], spinal cord tolerance [7]. However, the whole clinical scenario cannot be explained by one of them alone.

For spine surgeons, the more concerning question is: how severely the spinal cord should be compressed or to what extent the MRI signal of spinal cord should achieve can lead to clinically evident myelopathy? This question has been haunting surgeons, because sometimes the responsibility segment (namely the segment causing the symptom) is difficult to discern by physical examination, especially when multiple segments are involved. Under this circumstance, most of spine surgeons tend to decompress all the possible segments to achieve better surgical result. And the situation seems to be more troublesome for surgeons inclined to perform anterior decompression, because more surgical risks and complications will ensue compared with posterior approach. So many researchers have tried to find a better method to decide the responsibility segment. Ikuo Murone et al. [8] found

## OPEN ACCESS

### \*Correspondence:

Baorong He, Department of Spine Surgery, Hong-Hui Hospital, Xi'an Jiaotong University, College of Medicine, No. 555 Friendship East Road, Beilin District, Xi'an, Shaanxi, China, Tel: +8615229883719; Fax: (86) 29-87800002;

E-mail: hebr2014@163.com

Received Date: 19 Mar 2019

Accepted Date: 17 Apr 2019

Published Date: 22 Apr 2019

### Citation:

Zheng B, Hao D, Chang Z, He B. Imaging Criterion for Responsibility Segment of Cervical Myelopathy. Clin Surg. 2019; 4: 2411.

**Copyright** © 2019 Baorong He. This is an open access article distributed under the Creative Commons Attribution License, which permits unrestricted use, distribution, and reproduction in any medium, provided the original work is properly cited.

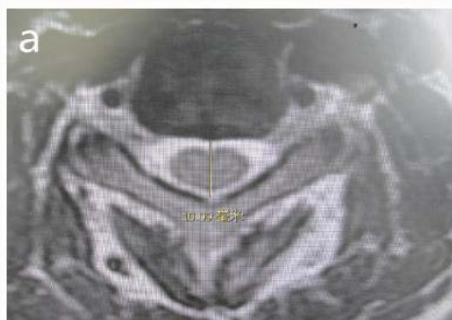

Figure 1a: Dura Sagittal diameter.

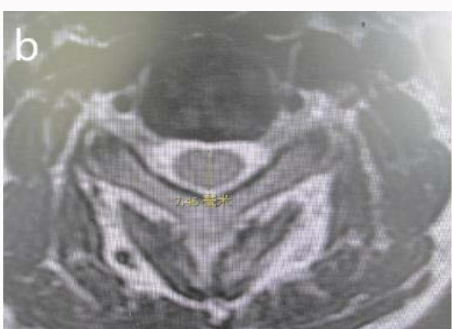

Figure 1b: Cord Sagittal diameter.

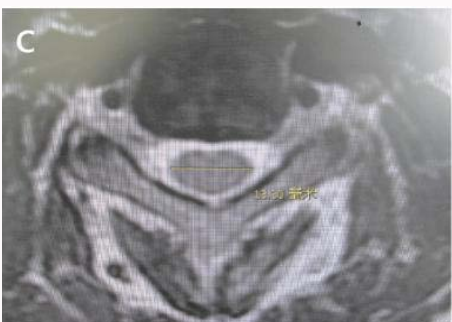

Figure 1c: Cord transverse diameter.

that if sagittal spinal canal diameter is less than 12 mm, the risk of cervical myelopathy is highly increased [8]. Zdenek Kadanka et al. [9] proposed that mJOA score has significant difference between patients with spinal cord sectional area less than 50 mm<sup>2</sup> and those greater than 60 mm<sup>2</sup> [9]. Other researchers used T2WI of spinal cord [10] or spinal cord deformation ratio [3] to decide. However, few brought up a definite parameter or a combination of these parameters for deciding responsibility segment.

This study arose from the need of exploring an imaging criterion with a combination of MRI parameters, including signal intensity on T2WI of spinal cord, cord/dura sagittal ratio, cord/dura area ratio, cord deformation ratio, to better decide the responsibility segment of cervical myelopathy.

## Material and Methods

Written informed consent was achieved at clinic during the patients' follow-up. The study protocol was approved by the institutional review board of the authors' hospital (Hong Hui Hospital, Medical College of Xi'an Jiaotong University).

## Inclusion and exclusion criterion

**Inclusion criterion:** 1. Unequivocal diagnosed with single segmental cervical myelopathy with long tract signs, such as walking instability, and physical examination showed Babinski sign (+) and Romberg sign (+); 2. Older than 18 years; 3. Underwent Anterior Cervical Decompression and Fusion (ACDF); 4. Preoperative symptoms were greatly relieved at 3 to 12 months follow-up.

**Exclusion criterion:** 1. Other types of cervical spondylosis, including cervical radiculomyelopathy; 2. Single or multiple segmental instability on flexion and extension dynamic X-ray, according to the cervical instability criterion proposed by White and Panjabi in 1987 [11]; 3. Cervical kyphosis; 4. Multiple cervical canal stenosis; 5. Spinal canal tumors; 6. Spinal infection; 7. Adhesive arachnoiditis; 8. peripheral polyneuritis; 9. Other neuromuscular disease.

## Sample size estimation

Each intervertebral disc was regarded as the study object in this research, and each patient contributed 4 discs (one was symptomatic and the other three were non symptomatic). Through the preliminary test with 20 patients, the sensitivity was expected to be 0.9, error to be 0.06 mm; specificity was expected to be 0.8, error to be 0.05 mm. So according to sample size estimation formula of diagnostic test  $n = \frac{u\alpha/2}{p^*(1-p)/\delta^2}$ , the sample size of diseased group was 96 ( $u\alpha/2=1.96$ ,  $P=0.9$ ,  $\delta=0.06$ ), while the sample size of control group was 245 ( $u\alpha/2=1.96$ ,  $P=0.8$ ,  $\delta=0.05$ ), which meant 96 symptomatic intervertebral discs and 245 non-symptomatic intervertebral discs were needed, so 130 patients (namely 130 intervertebral discs with symptoms and 390 intervertebral discs without symptoms) admitted in our hospital and underwent ACDF from February 2011 to August 2013 were included.

## Measuring method

T1WI and T2WI were achieved by MRI equipment (Siemens Sonata, Germany). T1WI: slice thickness 2.0 mm, TR/TE=587/12 ms, matrix 192\*256; T2WI: slice thickness 2.0 mm, TR/TE=4481/130 ms, matrix 180\*256. The following five values are measured at C3/4, C4/5, C5/6, C6/7: 1. dura Sagittal diameter; 2. cord Sagittal diameter; 3. cord transverse diameter; 4. dura area. 5. cord area (Figure 1a-1e). Single senior spine surgeon used Picture Archiving and Communication System (PACS) to measure. Each value was measured twice, and the average was the result.

To test the reliability of this measuring method, the five values of C5/6 segment mentioned above of 20 included patients were firstly measured by two independent senior spine surgeons. The reliability is evaluated by intro observer and inter observer ICC (Intraclass Correlation Coefficient).

Then three parameters were calculated using the five values mentioned above: 1. Cord/dura sagittal ratio=cord sagittal diameter/dura sagittal diameter; 2. Cord/dura area ratio=cord area/dura area; 3. cord deformation ratio=cord Sagittal diameter/cord transverse diameter.

To evaluate the signal intensity of MRI T2WI, three levels proposed by Yukawa et al. [10] were adopted to record (Figure 2). Grade 0=isointensity, grade 1=mildly increased signal intensity, grade 2=severely increased signal intensity. So adding the above three parameters, four parameters were gotten totally.

## Statistical analysis

SPSS 16.0 (SPSS Inc. USA) was used to analyze data. From the 130

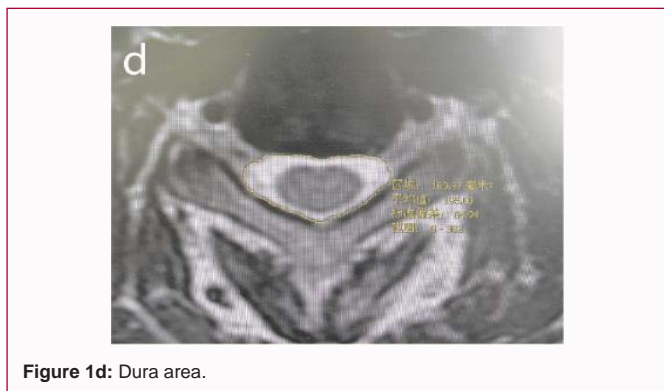

Figure 1d: Dura area.

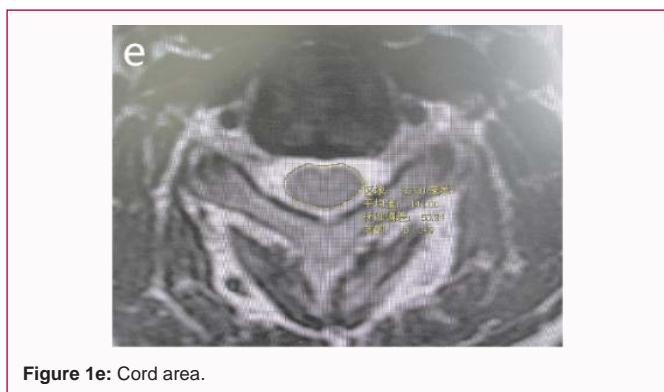

Figure 1e: Cord area.

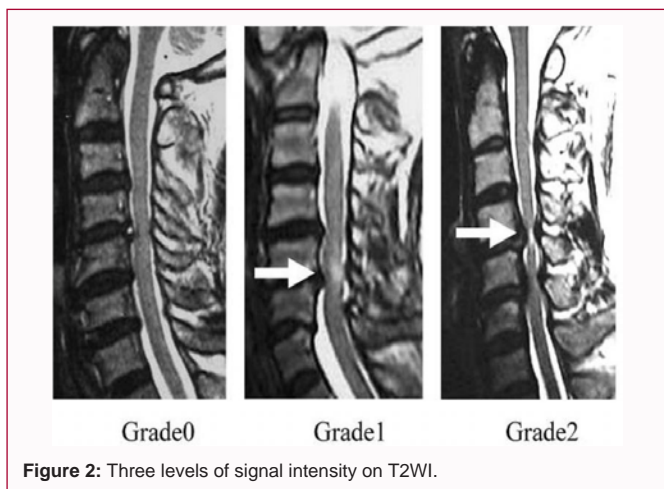


Figure 2: Three levels of signal intensity on T2WI.

patients, 75% (namely 100 cases) was randomly drawn. The sensitivity and specificity under different cut-off points were determined by ROC curve. Then the cut-off points of the four parameters (T2WI, cord/dura sagittal ratio, cord/dura area ratio, cord deformation ratio) are calculated to achieve greatest Youden index (Youden index=sensitivity + specificity-1). The rest 25% patients (namely 30 cases) was used to test the effectiveness of the cut-off points, and to explore the most appropriate combination of these four parameters as the imaging criterion of cervical myelopathy to achieve greatest Youden index.

## Results

### General condition

Because of using each intervertebral disc as the study object, in the first involved 100 patients, the distribution of the symptomatic intervertebral discs group and non-symptomatic intervertebral discs

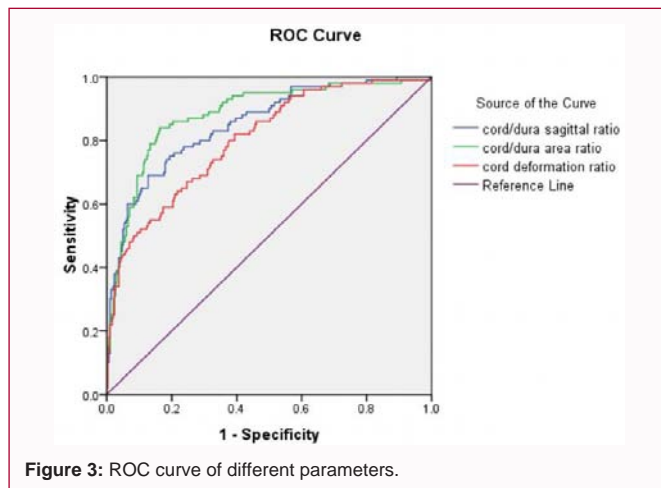


Figure 3: ROC curve of different parameters.

Table 1: Intro observer and inter observer ICC.

	Intro observer ICC	Inter observer ICC
C5/6 dura Sagittal diameter	0.95	0.92
C5/6 cord Sagittal diameter	0.92	0.98
C5/6 cord transverse diameter	0.98	0.97
C5/6 dura area	0.96	0.95
C5/6 cord area	0.97	0.94

ICC: Intra Class Correlation Coefficient

group were identical: male/female ratio was 11/9; the average age was  $48.62 \pm 10.02$  years, the average course of disease was  $6.51 \pm 4.33$  months. Similarly, in the rest 30 patients, the two groups were also identical: male/female ratio was 11/4, the average age was  $46.17 \pm 11.37$  years, and the average course of disease was  $7.59 \pm 3.12$  months.

### ICC (Intraclass Correlation Coefficient)

The intro observer and inter observer ICC were both greater than 0.90, suggesting the reliability of this measuring method was fairly good (Table 1).

### Merging the data of separate intervertebral discs

Through stratifying the C3/4, C4/5, C5/6, C6/7 intervertebral discs, symptomatic intervertebral discs group (Table 2) and non-symptomatic intervertebral discs group (Table 3) were found no statistically significant difference ( $p > 0.05$ ) ( $\chi^2$  test was used in signal intensity on T2WI and ANOVA was used in the other three parameters). So merging the data of separate intervertebral discs was well-founded.

### The ROC curve and cut-off points of the four parameters

In Figure 3 and Table 4, the Area Under the Curve (AUC) of cord/dura sagittal ratio, cord/dura area ratio, cord deformation ratio was 0.850 ( $p < 0.001$ ), 0.883 ( $p < 0.001$ ), 0.801 ( $p < 0.001$ ) respectively, suggesting that the difference between each AUC and 0.5 was statistically significant. However, the 95% Confidential Interval (CI) of them were mutually overlapped, meaning no statistically significant difference existed between them.

If the cut-off points of cord/dura sagittal ratio, cord/dura area ratio, cord deformation were calculated, adding T2WI at the same time (using  $T2WI \geq 1$  as the cut-off point), the result (Table 5) indicated that when using 0.61 as the cut-off point of cord/dura area ratio, the Youden index was the greatest, 0.67. However, the greatest Youden index that individual parameter could achieve was far from

**Table 2:** Comparison between different segments of symptomatic discs.

Segment	Increased intensity on T2WI	cord/dura sagittal ratio	cord/dura area ratio	cord deformation ratio
C3/4	72.70%	0.83 ± 0.07	0.67 ± 0.19	0.35 ± 0.21
C4/5	75%	0.82 ± 0.07	0.69 ± 0.07	0.37 ± 0.08
C5/6	60.40%	0.80 ± 0.08	0.66 ± 0.09	0.38 ± 0.10
C6/7	62.50%	0.85 ± 0.85	0.70 ± 0.14	0.41 ± 0.04
P-value	0.635	0.112	0.615	0.48

**Table 3:** Comparison between different segments of non-symptomatic discs.

Segment	Increased intensity on T2WI	cord/dura sagittal ratio	cord/dura area ratio	cord deformation ratio
C3/4	0	0.70 ± 0.07	0.50 ± 0.09	0.49 ± 0.08
C4/5	0	0.71 ± 0.07	0.52 ± 0.09	0.46 ± 0.08
C5/6	0	0.72 ± 0.09	0.55 ± 0.10	0.46 ± 0.07
C6/7	0	0.69 ± 0.07	0.52 ± 0.10	0.48 ± 0.08
P-value	0	0.052	0.067	0.071

**Table 4:** ROC curve and 95% CI of the parameters.

Parameter	AUC	P-value	95% CI
cord/dura sagittal ratio	0.85	<0.001	(0.808, 0.896)
cord/dura area ratio	0.883	<0.001	(0.842, 0.923)
cord deformation ratio	0.801	<0.001	(0.752, 0.851)

ROC: Receiver Operating Characteristic; CI: Confidence Interval; AUC: Area Under the Curve

satisfactory. So combining these four parameters to obtain a better diagnostic criterion seemed to be necessary. But before this, the effectiveness of the cut-off points were tested by the rest 30 patients to make sure validity.

#### Test of effectiveness of the four cut-off points

By comparing Table 5 and Table 6, the variation of Youden index of individual parameter was within acceptable range, suggesting that the cut-off points calculated above were valid and the combination of the four parameters could be further analyzed.

#### Exploring the most appropriate combination as the imaging criterion

Signal intensity on T2WI, cord/dura sagittal ratio, cord/dura area ratio, cord deformation ratio were tagged with A, B, C, D respectively, so the possible combination of them represented by the mathematical expressions were shown as follows (if only 2 or 3 parameters were chosen from A, B, C, D to combine, the Youden indexes were all less than when the four parameters were involved. So only the

combinations of four parameters were displayed due to limitation of space) (Table 7).

In Table 7, combination 9 ( $A \geq 1$  or  $B \geq 0.77$  and  $C \geq 0.61$  and  $D \leq 0.46$ ) has the greatest Youden index, 0.86, with the corresponding sensitivity=0.97, specificity=0.89, PPV (Positive Predictive Value) =0.74, NPV (Negative Predictive Value) =0.99, consistency parameter Kappa =0.778>0.75, suggesting they were highly consistent (Table 8). The equivalent meaning of this mathematical expression is that for a cervical segment on MRI, the T2WI should be more than mildly increased signal intensity, otherwise the following 3 conditions should be simultaneously satisfied: cord/dura sagittal ratio  $\geq 0.77$  and cord/dura area ratio  $\geq 0.61$  and cord deformation ratio  $\leq 0.46$ .

## Discussion

Precise spine surgery has been proposed as the future trend since recently. And the prerequisite lies in the accurate decision of responsibility segment. For cervical myelopathy, especially when multiple segments are involved, the responsibility segment is usually difficult to discern. Although physical examination is the gold standard, equivocal results often lead to excessive decompression that augments surgical complications and unnecessary economic burden. So solving this problem seems to be imperative.

Based upon four easily accessible parameters (T2WI, cord/dura sagittal ratio, cord/dura area ratio, cord deformation ratio) for spine surgeons when reading MRI with PACS, this study explored the

**Table 5:** Four parameters of the first 100 patients.

Parameter	Cut-off point	Sensitivity	Specificity	Youden index
signal intensity on T2WI	$\geq 1.00$	0.65	1	0.65
cord/dura sagittal ratio	$\geq 0.77$	0.75	0.81	0.56
cord/dura area ratio	$\geq 0.61$	0.84	0.83	0.67
cord deformation ratio	$\leq 0.46$	0.8	0.62	0.42

**Table 6:** Four parameters of the rest 30 patients.

Parameter	Cut-off point	Sensitivity	Specificity	Youden index
signal intensity on T2WI	$\geq 1.00$	0.72	1	0.72
cord/dura sagittal ratio	$\geq 0.77$	0.96	0.71	0.67
cord/dura area ratio	$\geq 0.61$	0.96	0.67	0.63
cord deformation ratio	$\leq 0.46$	0.96	0.52	0.48

**Table 7:** The sensitivity, specificity and Youden index of possible combinations.

Number	Combination	Sensitivity	Specificity	Youden index
1	$A \geq 1$ or $B \geq 0.77$ or $C \geq 0.61$ or $D \leq 0.46$	0.97	0.31	0.28
2	$A \geq 1$ and $B \geq 0.77$ and $C \geq 0.61$ and $D \leq 0.46$	0.83	0.96	0.79
3	$A \geq 1$ or $B \geq 0.77$ or ( $C \geq 0.61$ and $D \leq 0.46$ )	0.97	0.62	0.59
4	$A \geq 1$ or $C \geq 0.61$ or ( $B \geq 0.77$ and $D \leq 0.46$ )	0.97	0.67	0.64
5	$A \geq 1$ or $D \leq 0.46$ or ( $B \geq 0.77$ and $C \geq 0.61$ )	0.97	0.44	0.41
6	( $A \geq 1$ and $B \geq 0.77$ ) or $C \geq 0.61$ or $D \leq 0.46$	0.97	0.4	0.37
7	( $A \geq 1$ and $C \geq 0.61$ ) or $B \geq 0.77$ or $D \leq 0.46$	0.97	0.36	0.33
8	( $A \geq 1$ and $D \leq 0.46$ ) or $B \geq 0.77$ or $C \geq 0.61$	0.97	0.58	0.55
9	$A \geq 1$ or ( $B \geq 0.77$ and $C \geq 0.61$ and $D \leq 0.46$ )	0.97	0.89	0.86
10	$B \geq 0.77$ or ( $A \geq 1$ and $C \geq 0.61$ and $D \leq 0.46$ )	0.97	0.71	0.68
11	$C \geq 0.61$ or ( $B \geq 0.77$ and $A \geq 1$ and $D \leq 0.46$ )	0.97	0.68	0.65
12	$D \leq 0.46$ or ( $B \geq 0.77$ and $C \geq 0.61$ and $A \geq 1$ )	0.97	0.52	0.49
13	( $A \geq 1$ or $B \geq 0.77$ ) and $C \geq 0.61$ and $D \leq 0.46$	0.97	0.83	0.8
14	( $C \geq 0.61$ or $A \geq 1$ ) and $B \geq 0.77$ and $D \leq 0.46$	0.97	0.81	0.78
15	( $C \geq 0.61$ or $B \geq 0.77$ ) and $A \geq 1$ and $D \leq 0.46$	0.82	0.97	0.79
16	( $D \leq 0.46$ or $B \geq 0.77$ ) and $C \geq 0.61$ and $A \geq 1$	0.81	0.97	0.78
17	( $D \leq 0.46$ or $A \geq 1$ ) and $B \geq 0.77$ and $C \geq 0.61$	0.91	0.89	0.8
18	( $C \geq 0.61$ or $D \leq 0.46$ ) and $A \geq 1$ and $B \geq 0.77$	0.83	0.95	0.78

**Table 8:** Comparison between new criterion and gold standard.

New criterion	Gold standard	
	Symptomatic discs	Symptomatic discs
positive	29	10
negative	1	80

most appropriate combination of them as the imaging criterion for cervical myelopathy, namely  $T2WI \geq 1$  or (cord/dura sagittal ratio  $\geq 0.77$  and cord/dura area ratio  $\geq 0.61$  and cord deformation ratio  $\leq 0.46$ ), with the corresponding sensitivity =0.97, specificity =0.89, PPV=0.74, NPV=0.99, Youden index =0.86. Compared with using each parameter as the standalone diagnostic imaging criterion, this combination better approximates the reality defined by the gold standard. T2WI is in parallel connection with the latter three parameters, but the latter three are in series connection mutually. According to the principle of combination, parallel connection increases sensitivity but decreases specificity, series connection does inversely. In Table 5, the specificity of T2WI is 1, but the sensitivity is 0.65, so putting it in parallel connection increases the sensitivity to 0.97 at the expense of decreasing the specificity to 0.89, but the greatest Youden index is achieved eventually, which means the authenticity peaks using this combination. However, under other circumstances, surgeons can consult Table 7 to find optimal combination. For example, if high sensitivity is needed, combination 1 or 3-14 are the choices; if high specificity is required, combination 2 or 15 or 16 or 18 are all satisfactory, but if both of them are considered, combination 9 is definitely the best.

For signal intensity on T2WI, previous researchers mainly focused upon the relationship between high signal intensity on T2WI and prognosis of surgical decompression. Some proposed that high signal intensity on T2WI indicates poor surgical prognosis [12,13], but others did not find any correlation between them. However, at present, most researchers agree that T2WI hyper intensity accompanied

by T1WI hypointensity indicates poor prognosis, but T2WI hyperintensity alone has an ambiguous relationship with surgical prognosis [14-18], because T2WI hyperintensity alone represents a vast range of nonspecific neuropathological changes, such as loss of neurons, gliosis, gray of white matter edema, Wallerian degeneration, demyelination [19], among which some mild changes have a great recovery potential. This study only clarify that the specificity of T2WI hyper intensity as the imaging criterion for cervical myelopathy is high (1.00), but the sensitivity of it is low (0.65), but the relationship with the surgical prognosis cannot be extrapolated.

Meanwhile, to determine the cut-off points of imaging measurements for clinically evident myelopathy, many researchers have made great contributions. Ono et al. first proposed the spinal cord deformation ratio in 1977, and found that if the spinal cord deformation ratio is less than 0.4 (in our study, the cut-off point is 0.46), the function of spinal cord will deteriorate [9]. Kadanka et al. [9] conducted a survey in 2007, revealing that mJOA score has significant difference between patients with spinal cord sectional area less than 50 mm<sup>2</sup> and those greater than 60 mm<sup>2</sup>. But our study demonstrates that individual difference of spinal cord area is fairly large, if it is not divided by dura area to create a ratio, the standardization cannot be achieved. Some researchers recently proposed other possible method [20], especially the cord/dura volume ratio [21] brought up by Yanase et al. [21] in 2006, but the practicability needs further evaluation. Our study integrates the parameters proposed by previous researchers and creates a brand new combination of them, which means that if T2WI signal intensity is mildly or highly increased, this segment can be confidently regarded as the responsibility segment, otherwise only the latter three parameters all satisfy the criterion can the surgeon have enough confidence to make the final decision, because some responsibility segments are isointense on T2WI as everybody knows. However, the imaging criterion mentioned above is just a supplementary method, because only physical examination is the gold standard.

When practicing the conclusion of this study, surgeons should be cautious, because it can be only applied to patients of cervical myelopathy without dynamic instability, which was excluded through flexion and extension dynamic X-ray when selecting the cases. And from the perspective of pathogenesis, static compression and dynamic instability are far from each other. Meanwhile, PPV and NPV of this imaging criterion may vary in different places due to inconsistent prevalence of cervical myelopathy, but the sensitivity and specificity are universally valid, which are only related to the criterion per se.

Several limitations also lie in this study: 1. In inclusion criterion, preoperative symptoms are greatly relieved in 3 to 12 months follow-up, which is obtained mainly by telephone or patients' revisit, but not quantified. 2. Blinding method is not used, which may lead to measurement bias, but it can be controlled to minimum by multiple measurements.

In conclusion, although imaging criterion just assists physical examination in clinical practice, it still can help spine surgeons better decide the responsibility segment, and boost the accuracy of surgical decompression, which lays a solid foundation for precise spine surgery. This study, however, is a retrospective analysis, so more prospective and double-blinded studied in the future are needed to confirm or modify the imaging criterion, to further increase the sensitivity, specificity and Youden index, thus improve the surgical effectiveness and ameliorate the therapeutic prognosis.

## References

- Pavlov H, Torg JS, Robie B, Jahre C. Cervical spinal stenosis: determination with vertebral body ratio method. *Radiology*. 1987;164(3):771-5.
- Penning L, Wilmink JT, van Woerden HH, Knol E. CT myelographic findings in degenerative disorders of the cervical spine: clinical significance. *AJR Am J Roentgenol*. 1986;146(4):793-801.
- Ono K, Ota H, Tada K, Yamamoto T. Cervical myelopathy secondary to multiple spondylotic protrusions: a clinicopathologic study. *Spine*. 1977;2(2):109-25.
- Houser OW, Onofrio BM, Miller GM, Folger WN, Smith PL. Cervical spondylotic stenosis and myelopathy: evaluation with computed tomographic myelography. *Mayo Clin Proc*. 1994;69(6):557-63.
- Matz PG, Anderson PA, Holly LT, Groff MW, Heary RF, Kaiser MG, et al. The natural history of cervical spondylotic myelopathy. *J Neurosurg Spine*. 2009;11(2):104-11.
- Breig A, Turnbull I, Hassler O. Effects of mechanical stresses on the spinal cord in cervical spondylosis: a study on fresh cadaver material. *J Neurosurg*. 1966;25(1):45-56.
- Dommissie GF. The blood supply of the spinal cord. *Bone & Joint J*. 1974;56:225-35.
- Murone I. The importance of the sagittal diameters of the cervical spinal canal in relation to spondylosis and myelopathy. *J Bone Joint Surg Br*. 1974;56(1):30-6.
- Kadanka Z, Kerkovsky M, Bednarik J, Jarkovsky J. Cross-sectional transverse area and hyperintensities on magnetic resonance imaging in relation to the clinical picture in cervical spondylotic myelopathy. *Spine (Phila Pa 1976)*. 2007;32(23):2573-7.
- Yukawa Y, Kato F, Yoshihara H, Yanase M, Ito K. MR T2 image classification in cervical compression myelopathy: predictor of surgical outcomes. *Spine (Phila Pa 1976)*. 2007;32(15):1675-8.
- Whitehill R, Moran DJ, Fechner RE, Ruch WW, Drucker S, Hooper WE, et al. Cervical ligamentous instability in a canine *in vivo* model. *Spine (Phila Pa 1976)*. 1987;12(10):959-63.
- Alafifi T, Kern R, Fehlings M. Clinical and MRI predictors of outcome after surgical intervention for cervical spondylotic myelopathy. *J Neuroimaging*. 2007;17(4):315-22.
- Avadhani A, Rajasekaran S, Shetty AP. Comparison of prognostic value of different MRI classifications of signal intensity change in cervical spondylotic myelopathy. *Spine J*. 2010;10(6):475-85.
- Mehalic TF, Pezzuti RT, Applebaum BI. Magnetic resonance imaging and cervical spondylotic myelopathy. *Neurosurgery*. 1990;26(2):217-26.
- Okada Y, Ikata T, Yamada H, Sakamoto R, Katoh S. Magnetic resonance imaging study on the results of surgery for cervical compression myelopathy. *Spine (Phila Pa 1976)*. 1993;18(14):2024-9.
- Ramanauskas WL, Wilner HI, Metes JJ, Lazo A, Kelly JK. MR imaging of compressive myelomalacia. *J Comput Assist Tomogr*. 1989;13(3):399-404.
- Suri A, Chhabra RP, Mehta VS, Gaikwad S, Pandey RM. Effect of intramedullary signal changes on the surgical outcome of patients with cervical spondylotic myelopathy. *Spine J*. 2003;3(1):33-45.
- Takahashi M, Yamashita Y, Sakamoto Y, Kojima R. Chronic cervical cord compression: clinical significance of increased signal intensity on MR images. *Radiology*. 1989;173(1):219-24.
- Mizuno J, Nakagawa H, Inoue T, Hashizume Y. Clinicopathological study of "snake-eye appearance" in compressive myelopathy of the cervical spinal cord. *J Neurosurg*. 2003;99(Suppl 2):162-8.
- Lee MJ, Cassinelli EH, Riew KD. Prevalence of cervical spine stenosis. Anatomic study in cadavers. *J Bone Joint Surg Am*. 2007;89(2):376-80.
- Yanase M, Matsuyama Y, Hirose K, Takagi H, Yamada M, Iwata H, et al. Measurement of the cervical spinal cord volume on MRI. *J Spinal Disord Tech*. 2006;19(2):125-9.