



Graft Telescopic Inversion Anastomosis for Acute Type A Aortic Dissection Repair

Mi Kyung Lee, Jong Bum Choi and Nan Yeol Kim*

Department of Thoracic and Cardiovascular Surgery, Wonkwang University School of Medicine, Republic of Korea

Abstract

The remaining dissected aorta in repair of acute type A aortic dissection was approximated with two Teflon felt strips of different widths of 7 mm and 14 mm, and the graft was anastomosed with a uniformized telescopic suture technique. In hemiarch and total arch replacements to repair acute type A aortic dissection, the addition of the telescopic suture inversion technique to the approximation of the dissected aorta using two felt strips may be a secure hemostatic technique in the graft-to-aorta anastomosis.

Keywords: Aorta; Dissection; Aneurysm; Hemostasis; Suture technique

Introduction

In repairing acute type A aortic dissection, it is essential to employ the correct anastomotic technique in securing the graft to the aorta to ensure hemostasis and prevent false aneurysms. Some surgeons reinforced the friable wall of the dissected aorta with the Teflon or pericardial strips [1,2]. The graft telescopic inversion suture technique was previously presented, among various anastomosis options [3]. Here, we describe proximal and distal anastomoses in acute aortic dissection repair. First, we reinforced the friable aortic wall with two felt strips of different widths. Then, we performed a uniform graft telescopic inversion suture.

Surgical Techniques

The right axillary artery was cannulated for a cardiopulmonary bypass. During systemic cooling, the ascending aorta was cross-clamped and transected. After a retrograde blood cardioplegia into the coronary sinus, the ascending aorta was trimmed at 1.5 cm to 2.0 cm above the three commissures. The dissected commissures were reattached to the adventitia using pledgeted 4-0 polypropylene mattress sutures. In patients with deep dissection into sinuses, we packed a 4- × 4-in gauze in the aortic root to distend the sinuses, and then we applied BioGlue (CryoLife Inc., Kennesaw, GA, USA) to the false lumen and compressed the adventitia gently with a sponge-stick(s) to eradicate the false lumen. The ascending aorta was reinforced just above three commissures; by attaching a 7-mm wide, 8 cm to 9 cm long inner felt strip and a 12-mm wide, 11 cm to 12 cm long outer felt strip with a continuous 4-0 polypropylene mattress suture. The upper margins of the two strips were placed at the same level. The non-reinforced aortic end was trimmed, leaving 3 mm to 4 mm. During antegrade selective cerebral perfusion, we anastomosed the graft to the distal aorta (the arch or descending aorta) with a telescopic inversion suture.

For hemiarch replacement, the inferior half of the arch was reinforced with two strips and suture (Figure 1A). A 3 mm to 4 mm non-reinforced aortic wall was left after trimming. A 26-mm Hemashield graft (Maquet Getinge Group, Rastatt, Germany) was anastomosed to the reinforced arch with a continuous 3-0 polypropylene over-and-over suture (Figure 1A). Briefly, the graft was sutured with a simple stitch in the most profound posterior aspect of the arch and tied. Continuous sutures were then applied to each lateral aspect of the graft. The length of each stitch was 7 mm, which was the width of the inner strip, and the stitch interval was 5 mm to 6 mm, which was just less than the stitch length (Figure 1A). The superficial and deep stitches did not pass the inner strip; instead, they passed along the upper and lower margins alongside the inner strip. For total arch replacement, the descending aorta was reinforced with the same technique; then the graft was anastomosed with a telescopic inversion suture. During rewarming, we anastomosed the proximal end of the graft to the prepared proximal ascending aorta with another graft telescopic inversion suture (Figure 1B-1D and Figure 2). Since 2016, we used this anastomotic technique in 25 consecutive patients who required acute aortic dissection repair (n=20 hemiarch replacement and

OPEN ACCESS

*Correspondence:

Nan Yeol Kim, Department of Thoracic and Cardiovascular Surgery, Wonkwang University School of Medicine, 895 Muwang-Ro, Iksan, Chonbuk, 54538 Republic of Korea, Tel: +82-63-859-2540; Fax: +82-63-852-8480; E-mail: nanyeolkim@gmail.com

Received Date: 04 Sep 2019

Accepted Date: 20 Sep 2019

Published Date: 26 Sep 2019

Citation:

Lee MK, Choi JB, Kim NY. Graft Telescopic Inversion Anastomosis for Acute Type A Aortic Dissection Repair. *Clin Surg*. 2019; 4: 2594.

Copyright © 2019 Nan Yeol Kim. This is an open access article distributed under the Creative Commons Attribution License, which permits unrestricted use, distribution, and reproduction in any medium, provided the original work is properly cited.

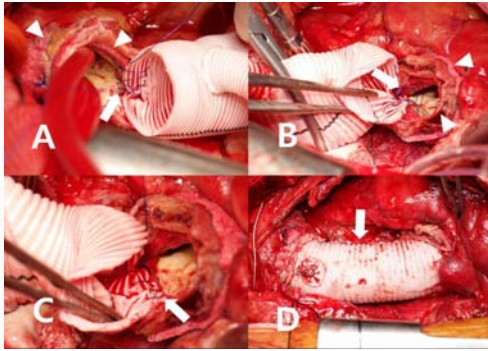


Figure 1: Aortic dissection repair in an 82-year-old patient with a dissected friable intima. **(A)** The dissected arch was reinforced with two felt strips of different widths (arrowheads), and a 3-mm non-reinforced aortic margin was left after trimming. The graft was anastomosed to the arch in a telescopic inversion configuration with a continuous 3-0 polypropylene suture (arrow). **(B)** The dissected proximal aorta was also reinforced with two felt strips (arrowheads) and anastomosed to the graft with the same telescopic inversion suture (arrow). **(C)** With the sutures in (B) tightened, the inverted graft covered the inner felt strips (arrow). **(D)** Completed dissection repair with a graft telescopic inversion suture (arrow).

n=5 total arch replacements). None required re-exploration due to bleeding. One patient died in the hospital.

Discussion

The graft telescopic inversion technique had already been described [3]. We reinforced the friable intima of the dissected aorta with an additional inner felt strip, as described previously [1]. Due to the narrow, 7-mm wide inner strip, each continuous stitch was a constant 7 mm in length. The inverted graft covered the inner strip, which prevented strip exposure to the bloodstream. Additional sutures were rarely needed for hemostasis. The 5 mm to 6 mm stitch spacing was not difficult to maintain, because the spacing was slightly

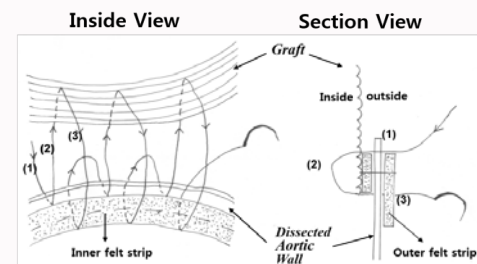


Figure 2: Diagram of the graft telescopic inversion suture technique. *(Left)* The inside of the graft-aorta anastomosis shows the narrow inner felt-strip and a 3-mm non-reinforced aortic end (dissected aortic wall). In the graft-aorta anastomosis, a continuous 3-0 polypropylene suture was applied. Each turn of the suture always consisted of (1) the first out-in superficial aortic stitch through the non-reinforced aortic end, (2) the second out-in stitch through the graft (stitch is 7-mm long), and (3) the third in-out deep aortic stitch, which (*right*) entered at the lower margin of the inner felt strip, then through the aortic wall, and exited through the outer felt strip.

smaller than the 7-mm stitch length, and the upper aortic stitches were not a waste of time.

References

1. Kouchokos NT, Blackstone EH, Hanley FL, Kirklin JK. Acute aortic dissection. In: Kouchokos NT, Blackstone EH, Hanley FL, Kirklin JK, editors. *Kirklin/Barratt-Boyes Cardiac Surgery*. 4th ed. Philadelphia: Elsevier Saunders. 2013;941-72.
2. Tanaka K, Morioka K, Li W, Yamada N, Takamori A, Handa M, et al. Adventitial inversion technique without the aid of biologic glue or Teflon buttress for acute type A aortic dissection. *Eur J Cardiothorac Surg*. 2005;28(6):864-9.
3. Rylski B, Siepe M, Schoellhorn J, Beyersdorf F. An improved technique for aortic anastomosis: graft telescopic inversion. *J Thorac Cardiovasc Surg*. 2010;140(4): 934-5.