



Giant Phyllodes Tumor

Ayesha Saeed and Humna Siraj*

Department of Surgery, Pakistan Atomic Energy Hospital, Islamabad, Pakistan

Abstract

Phyllodes tumor is also called as Phyllodes Cystosarcoma. They are rare breast tumor; accounting for less than 1% of all breast tumors. In this case, we report a case of a middle aged female presenting with large size mass involving whole right breast. There was high suspicion of malignancy but definitive diagnosis was not made until we had histopathology report of that mass after its complete excision. Accurate diagnosis is necessary to provide appropriate treatment to the patient and to avoid recurrence.

Keywords: Phyllodes tumor; Benign; Histopathology

Introduction

Phyllodes is a Greek word which means leaf like pattern [1]. It can occur in younger females but mostly effect women over the age of 40 years. It presents as large sometimes massive tumor with irregularly protuberant surface, also sometimes ulceration of overlying skin occurs due to pressure necrosis. Regardless of size Phyllodes remain mobile on chest wall. There is a wide variation in there histological appearance, with some benign lesions similar like fibroadenoma while other with high mitotic index have malignant potential; having capacity of local.

Case Presentation

A 50 years old female patient came to outpatient department with the complaint of right breast lump which she first noticed 10 years back. At that time lump was small and painless with no overlying skin changes. From last 6 months she noticed a rapid increase in size of lump causing heaviness and discomfort in right breast along with increase hair growth around areola and skin changes of overlying skin. Her family history is negative for any malignancy or of any breast related disease. She was still menstruating and with regular period interval and normal cycles. Physical examination of right breast revealed huge swelling occupying whole right breast; measures 30 cm × 20 cm approximately, it was non-tender, with no temperature difference, having an active serous discharging sinus in the lower quadrant and inferior aspect of right breast. Right breast also had Peau d'orange appearance of overlying skin. Left breast was normal with no lump or any other pathology. No axillary lymph nodes were palpable bilaterally (Figure 1).

Her complete blood count test showed, white cell count of 8910/ μ L; with Neutrophil count 68%, and Monocyte count 24%, Eosinophil 2% and Basophil 0%, hemoglobin of 10.2 g/dl, while other baseline test were within normal range. Her Trucut biopsy was done which showed fibroepithelial lesion (Figure 2). There are scattered, compressed and dilated ducts lined by epithelial and myoepithelial cells. The surrounding stroma shows spindle cell overgrowth. No cytological atypia, necrosis and mitosis noted in specimen examined. Biopsy category B2 (differential diagnosis of fibroadenoma versus benign Phyllodes tumor). Elective mastectomy of right breast was planned and done with the preoperative findings of massively enlarge right breast with tumor of about 30 cm × 20 cm, having high vascularity and edematous underlying muscle and surrounding tissue. Tumor was excised along with whole right breast and was sent for histopathology; according to the report the weight of specimen was 4,293 grams with size of 31 cm × 23 cm, it was a well circumscribed fibroepithelial lesion consistent with benign pathology, with tumor free resection margins and negative for ductal carcinoma in situ and malignancy, hence confirming the diagnosis of Benign Phyllodes Tumor (Figure 3). Patient is put on regular follow up of 6 monthly intervals for detection of any recurrence (Figure 4).

Discussion

Phyllodes tumors are usually an incidental finding during the examination. Phyllodes tumor's peak is between 30 to 40 years of age, but can occur at any age [1-3]. Phyllodes tumor also called Cystosarcoma Phyllodes is classified as benign, borderline or malignant tumor. Borderline

OPEN ACCESS

*Correspondence:

Humna Siraj, Department of Surgery,
Pakistan Atomic Energy Hospital,
Islamabad, Pakistan,
E-mail: humosiraj@gmail.com

Received Date: 22 Jun 2021

Accepted Date: 08 Jul 2021

Published Date: 13 Jul 2021

Citation:

Saeed A, Siraj H. Giant Phyllodes
Tumor. Clin Surg. 2021; 6: 3249.

Copyright © 2021 Humna Siraj. This is an open access article distributed under the Creative Commons Attribution License, which permits unrestricted use, distribution, and reproduction in any medium, provided the original work is properly cited.

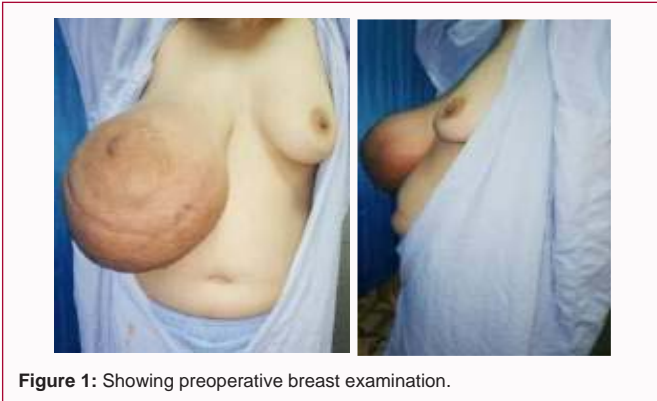

Figure 1: Showing preoperative breast examination.

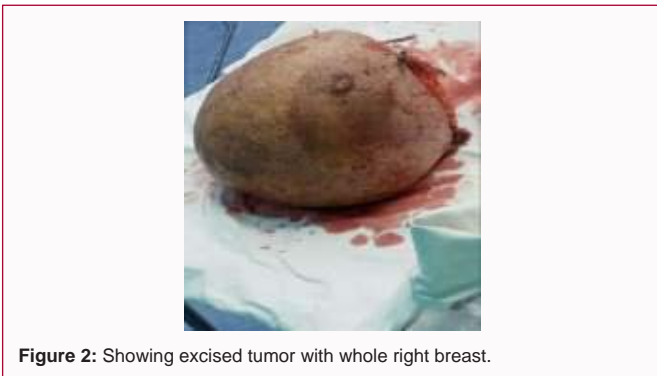

Figure 2: Showing excised tumor with whole right breast.

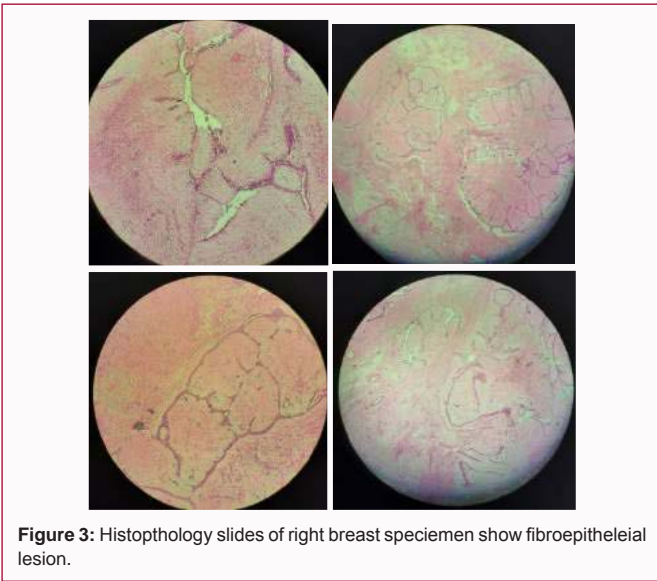


Figure 3: Histopathology slides of right breast specimen show fibroepithelial lesion.

Phyllodes are more likely to have local recurrence than the other two. Calcification on Mammography and the morphologic evidence of necrosis do not differentiate between the three types of Phyllodes; hence it is difficult to distinguish between benign variant of Phyllodes from malignant one and even from fibroadenoma [4]. Phyllodes tumor are usually markedly separated from the surrounding breast tissue which is compressed and distorted. Phyllodes create a false capsule, through which the tumor extends and grows into the rest of the healthy breast tissue. These tumors on gross examination give a leaf-like appearance due to characteristics of sizeable malignant sarcoma, and presence of cystic spaces on histology. Trucrut biopsy




Figure 4: Trucrut sample and histopathology report of right breast.

is the reliable investigation but excision and large biopsy are the definitive methods for diagnosing the Phyllodes tumor. Complete excision is the treatment of choice; thus local excision with margin of normal breast tissue is done. If there is a suspicion of malignant Phyllodes, re excision of the biopsy site is done to ensure complete excision of tumor with 1 cm of normal mammary tissue is indicated. Large Phyllodes tumor may require mastectomy but axillary clearance is not recommended because of rare chances of axillary lymph nodes metastasis [5]. Local recurrence in Phyllodes tumors has been associated with inadequate local excision. Positive surgical margins, tumor size, high mitotic count stromal overgrowth, and necrosis are factors which have shown an increase in the local recurrence [6]. Till date the most giant benign Phyllodes tumor mentioned is of 4,857 grams weight and 40.2 cm × 36.3 cm × 15 cm in size (mentioned in a case report by department of oncology, Mexico city) [7].

Conclusion

Benign Phyllodes should always be in differential diagnosis for the female patient having giant or large breast lump, a thorough examination and Trucrut biopsy should be done followed by excision and large biopsy of the lump to confirm the diagnosis and should be put on close follow ups for detection of recurrence or any malignancy even if it was benign variant.

References

1. Phyllodes tumors of breast.
2. Richard C, Sainsbury. The Breast. In: William, Connell, McCaskie, editors. Phyllodes tumor. 27th Ed. Boca Raton, FL: CRC PRESS; 2018. p. 870.
3. Albalawi IA. A huge phyllodes tumor in the breast: A case report. Electron Physician. 2018;10(6):6951-5.
4. Parkar, Catherine C,. "The Breast." Schwartz's Principles of Surgery, 11th Ed. Vol 1, MacGraw-Hill Education, 2019. p. 600.
5. Parkar, Catherine C. "The Breast." Schwartz's Principles of Surgery, 11th Ed. Vol 1, MacGraw-Hill Education, 2019. p. 601.
6. Albalawi IA. A huge Phyllodes tumor in the breast: a case report. Electron Physician. 2018;10(6):6951-5.
7. Fernández-Ferreira R, Arroyave-Ramírez A, Motola-Kuba D, Alvarado-Luna G, Mackinney-Novelo I, Segura-Rivera R. Giant benign mammary Phyllodes tumor: Report of a case and review of the literature. Case Rep Oncol. 2021;14:123-33.