



Germ Cell Tumors

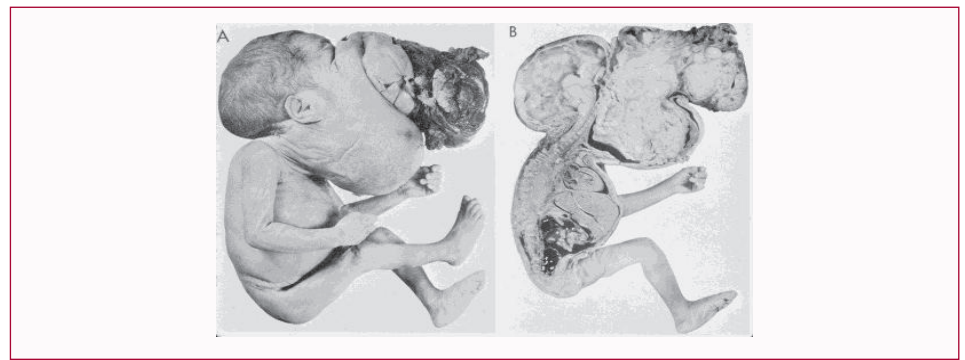
Hart Isaacs*

Department of Pathology, Rady Children's Hospital, USA

Clinical Image

Germ cell tumors are an assorted group of benign and malignant neoplasms derived from primordial germ cells. They are found in a variety of sites, both gonadal and extragonadal, the latter in midline locations as the sacrococcygeal area, retroperitoneum, mediastinum, neck and pineal region. Teratoma is the leading fetal and neonatal neoplasm in several reviews. Most germ cell tumors of the fetus and neonate are benign histologically.

Pharyngeal Teratoma



There is great distortion of the facial and neck regions. (A) Lateral view of the body surface. (B) Sagittal section throughout the midline showing the extent of the tumor.

How would you treat this awesome problem? Is the tumor resectable?

OPEN ACCESS

***Correspondence:**

*Hart Isaacs, Department of Pathology,
Rady Children's Hospital, 3020
Children's Hospital Way MC 5007, San
Diego, CA 92123, USA, Tel: 858-966-
5944;*

E-mail: hisaacs@ucsd.edu

Received Date: 06 Mar 2017

Accepted Date: 22 Jun 2017

Published Date: 04 Jul 2017

Citation:

*Isaacs H. Germ Cell Tumors. Clin Surg.
2017; 2: 1531.*

Copyright © 2017 Hart Isaacs. This is an open access article distributed under the Creative Commons Attribution License, which permits unrestricted use, distribution, and reproduction in any medium, provided the original work is properly cited.