



Fetoscopic Diagnosis of Adams-Oliver Syndrome

Joan Sabrià^{1*}, Mar Benassar¹, Annabel Laborda², Miriam Pérez¹, Gemma Arca¹, Elena Muñoz³, Olga Gómez¹ and Josep Maria Martínez¹

¹BCNatal - Barcelona Center for Maternal-Fetal and Neonatal Medicine (Hospital Sant Joan de Déu and Hospital Clínic), Spain

²Department of Obstetrics and Gynecology, Hospital Comarcal de l'Alt Penedès, Vilafranca del Penedès, Spain

³Department of Pediatric Surgery, Hospital Sant Joan de Déu, Spain

Abstract

Adams-Oliver Syndrome (AOS) is a rare congenital disorder, characterized by limb reduction defects and congenital aplasia cutis. Central nervous and cardiopulmonary systems may also be affected. We describe the first report of a prenatally diagnosed case in a couple without history of affected children, presenting a distal limb reduction defect, an image compatible with detachment of the skin at the level of scalp and significant right heart dominance. A fetoscopic approach allowed to confirm the severity of the limb anomalies and the skin defect of the scalp and was critically useful to identify the vascular origin of the findings, ruling out the existence of amniotic bands. Moreover, fetoscopy was useful for parents, providing them a better understanding of the severity of the defects. After extensive counseling, parents opted for termination of pregnancy. All of the findings at postmortem examination confirmed the ultrasound and fetoscopic features and were consistent with the AOS. Our report shows that fetoscopy can be a useful tool to perform the differential diagnosis of uncommon entities, directly visualizing the type and extension of the different defects.

Keywords: Adams-Oliver syndrome; Limb defects; Aplasia cutis; Fetoscopy

Case Presentation

This was the first pregnancy of a 36-year-old mother, with no history of teratogenics exposure and without family history of congenital anomalies or hereditary diseases. First trimester scan revealed a normal nuchal translucency, no apparent structural anomalies and a low risk combined screening for aneuploidy. The course of the pregnancy was uneventful until a structural defect of the fetal fingers and toes was detected at the second trimester scan. Then, she was referred to our hospital. The ultrasound showed according fetal biometry, with normal posterior placenta and normal amniotic fluid. The fetal anatomy study revealed a symmetrical and distal transverse reduction defect affecting the four extremities (Figure 1A, 1B), the intermediate and distal phalanges of the fingers of both hands and feet, were absent. No other anomalies were observed at the level of carpal and tarsal bones, whereas the rest of the skeleton appeared normal. In addition, an image compatible with a small detachment of the skin at the left parietal level of scalp was identified (Figure 1C), which led us to the suspicion of congenital aplasia cutis. No other structural malformations were detected neither we were able to identify images suggestive of amniotic bands. Echocardiography showed significant right heart dominance (right-to-left ratio 1.8), with a slightly reduced sized aortic isthmus (Z-score -2.3) with antegrade flow. Amniocentesis confirmed a normal male fetus [arr (1-22) ×2 (XY) ×1]. In view of the unspecific ultrasonographic findings, a diagnostic fetoscopy was offered to parents in order to better determine the extension of the limb defects, to confirm the scalp anomaly and to rule out amniotic band syndrome. After extensive counseling, parents gave written informed consent for diagnostic fetoscopy. The procedure was performed at 23.0 weeks under maternal local anesthesia and sedation, a 3 mm trocar was percutaneously introduced and an evaluation of the fetal anatomy could be performed without complications (Figures 1D-1F). We could clearly confirm the distal amputation of all the fingers and toes, with ulcerations at the level of the skin through which the phalanges were protruding. In addition, we could observe a violaceous appearance of the skin not only in the extremities but also in the trunk and abdomen, compatible with *marmorata cutis*. Furthermore, the presence of a 3 cm ulcerated area at the level of the scalp was clearly visualized, suggesting the diagnosis of congenital aplasia cutis. Amniotic band syndrome was definitely excluded. Based on the phenotype a likely diagnosis of Adams-Oliver Syndrome (AOS) was accorded. The whole procedure lasted 15 min skin-to-skin without changes in fetal heart rate and maternal complications. The mother was discharged 6 h later. After

OPEN ACCESS

*Correspondence:

Joan Sabrià, Fetal Medicine Unit,
BCNatal - Barcelona Center for
Maternal-fetal and Neonatal Medicine
(Hospital Sant Joan de Déu and
Hospital Clínic), Passeig Sant Joan de
Déu, 2, Barcelona, 08950, Spain, Tel:
+34 932532100;
E-mail: jsabria@sjdhospitalbarcelona.

org

Received Date: 14 Apr 2021

Accepted Date: 26 Apr 2021

Published Date: 29 Apr 2021

Citation:

Sabrià J, Benassar M, Laborda A,
Pérez M, Arca G, Muñoz E, et al.
Fetoscopic Diagnosis of Adams-Oliver
Syndrome. *Clin Surg.* 2021; 6: 3152.

Copyright © 2021 Joan Sabrià. This
is an open access article distributed
under the Creative Commons
Attribution License, which permits
unrestricted use, distribution, and
reproduction in any medium, provided
the original work is properly cited.

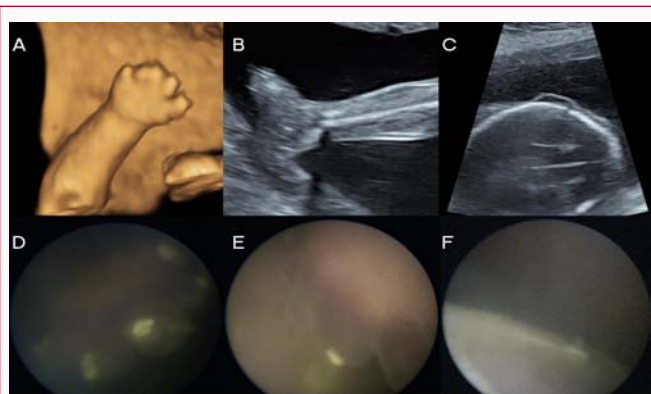


Figure 1: Images showing the ultrasound findings at hands (A), feet (B) and head (C) level. The same lesions seen by fetoscopy at hands (D), feet (E) and head (C) level.

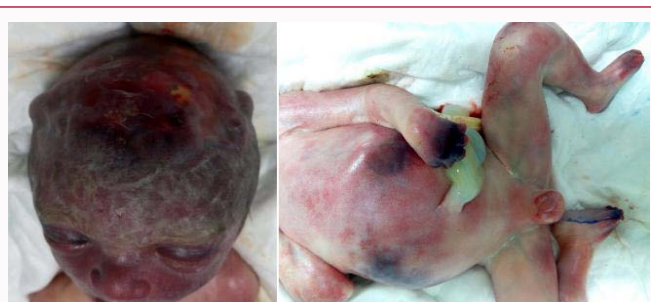

Figure 2: Postmortem examination. Note the characteristic hands and feet defects, cutis marmorata and aplasia cutis on the head.

fetoscopy, the video was reviewed together with pediatric specialists in the presence of parents, as previously committed. Parents could thus better understand the severity of the anomalies. After extensive discussion, parents requested a termination of pregnancy, which was accepted by an external committee. Postmortem examination (Figure 2) confirmed all the fetoscopic findings that were consistent with the AOS. Thereafter, exome sequencing identified a new heterozygous mutation in the gene NOTCH1 [*NOTCH1:c.1423C>Tp(Gin475Ter)*]. Later on, this mutation was also found in the father, whose physical examination was normal, with only mild venous insufficiency at the lower extremities.

Discussion

We present a novel case of a combined ultrasonographic and fetoscopic prenatal diagnosis of AOS, which was performed in a no-risk family for the first time. AOS is a rare congenital defect of unknown etiology [1]. There is a genetic basis since most cases show autosomal dominant inheritance [2]. A vasculopathy disruption leading to a variety of phenotypes has been suggested as a pathogenical cause. Thus, clinical spectrum is broad and variable. Major clinical

criteria are transverse limb reduction defects, congenital aplasia cutis and family history. Minor criteria include *cutis marmorata*, congenital heart defects as well as vascular anomalies. The presence of two major criteria, or the combination of one major and one minor are regarded to be sufficient for the diagnosis [3]. To our knowledge, prenatal diagnosis of AOS has been reported only once, in a family with a previous affected child that was diagnosed postnatally and two consecutive prenatal diagnosis cases at 23 and 13 weeks in the following pregnancies [4]. In fact, due to the broad spectrum of symptoms and heterogeneity of AOS, it is difficult to do a correct differential diagnosis with other rare entities, such as amniotic band syndrome or other causes of limb reduction defects. Thus, the authors already suggested that fetoscopy might be useful to assess the severity of some cases with limb reductions and scalp defects [4]. Fetoscopy is currently a low-risk procedure for the mother that is usually performed under local anesthesia, for therapeutic purposes in most of the times. We offered to the parents the possibility to perform a diagnostic fetoscopy in order to confirm the diagnosis more quickly and to evaluate the grade of extension of the skin anomalies. Indeed, fetoscopy allowed us to visualize the scalp and the limbs defects, and, especially, to better determine the extension of the lesions, excluding the existence of amniotic bands as well. Moreover, we could additionally identify the presence of *marmorata cutis* affecting a large part of the body surface. Thus, fetoscopy was helpful in leading to our multidisciplinary team to suggest a precise diagnosis of AOS and to establish the unfavorable prognosis. Furthermore, fetoscopy review with pediatric specialists was particularly useful for parents counseling, providing them a better understanding of the severity of the defects, and helping them in their decision-making options. Interestingly, in our case the directed exome sequencing revealed a new mutation, also present in the father, which would render for an early prenatal diagnosis in a following pregnancy. To conclude, fetoscopic direct visualization can be a useful tool to perform the differential diagnosis of uncommon anomalies, particularly those affecting external features of the limbs, face, genitalia and rest of the skin. Parents counseling may obtain benefit by reviewing the procedure with a multidisciplinary team.

References

1. Forrest H, Adams C, Oliver P. Hereditary deformities in man: Due to arrested development. *J Hered.* 1945;36(1):3-7.
2. Lister Hill National Centre for Biomedical Communications (Internet). U.S. National Library of Medicine National Institutes of Health Department of Health & Human Services. Adams Oliver syndrome. 2019.
3. Saeidi M, Ehsanipoor F. A case of Adams-Oliver Syndrome. *Adv Biomed Res.* 2017;6:167.
4. Becker R, Kunze J, Horn D, Gasiorek-Wiens A, Entezami M, Rossi R, et al. "Autosomal recessive type of Adams-Oliver syndrome: Prenatal diagnosis. *Ultrasound Obstet Gynecol.* 2002;20:506-10.