



Fecopneumothorax Surgery by Thoracoabdominal Incision after McKeown Esophagectomy

Julio Sesma¹ and Mong-Wei Lin^{2*}

¹Department of Thoracic Surgery, Hospital General Universitario Alicante, Alicante, Spain

²Department of Surgery, National Taiwan University Hospital and National Taiwan University College of Medicine, Taipei, Taiwan

Abstract

Fecopneumothorax is an unusual but life-threatening condition. Fecopneumothorax after esophagectomy is extremely rare, with only two reported cases; it is managed with a two-staged surgical approach: Laparotomy followed by thoracotomy. We report the first case, to our knowledge, of fecopneumothorax due to colonic intrathoracic perforation after minimally invasive esophagectomy managed by a left thoracoabdominal incision and barrel-loop colostomy. As the surgical field was already known to be contaminated, loop colostomy was considered to avoid anastomotic site leakage and related complications. The thoracoabdominal incision is a safe and feasible approach that allows one-step surgery for the thoracic and abdominal field.

Introduction

Fecopneumothorax is an unusual but life-threatening condition that is usually associated with intrathoracic colon perforation due to a strangulated diaphragmatic hernia [1-4]. The most frequent causes are congenital [3] and traumatic conditions [4] but it can also occur as an extremely rare complication after esophagectomy [1,2]. In global literature, only two cases of fecopneumothorax after esophagectomy [1,2] have been reported that were treated by a two-stage surgery: Laparotomy for hernia reduction and colectomy in the first stage and lateral thoracotomy or video-assisted thoracic surgery (VATS) for decortication in the second stage. We present the first case in the world literature for fecopneumothorax due to colonic intrathoracic perforation after minimally invasive esophagectomy managed by a left thoracoabdominal incision.

OPEN ACCESS

Case Presentation

A 59-year-old man who had undergone a minimally invasive McKeown esophagectomy with VATS and laparoscopic approach as well as gastric tube reconstruction due to middle third esophageal squamous cell carcinoma was referred to our department 12 months after surgery. The first follow-up computed tomography (CT) shows no diaphragmatic hernia 6 months after minimally invasive McKeown esophagectomy Figure 1A and B. He complained about intermittent cramping epigastric pain and dyspnea 7 days before this admission. Physical examination revealed tachycardia (122/min) and tachypnea (22/min) with decreased breathing sounds on the left side. Laboratory data showed a white blood cell count of 11930/ μ L with left shift change (Seg 86.0%), elevated C-reactive protein (> 40 mg/dL), elevated blood urea nitrogen (BUN)/creatinine (77.1/3.6 mg/dL) and elevated lactate level (2.88 mmol/L). Blood gas analysis showed severe acidosis (pH 7.141, pCO₂ 45.3 mmHg, HCO₃ 15.3 mmol/L, base excess -13.9 mmol/L). A chest radiograph revealed left basal and lateral pneumothorax, with pleural effusion and lower lung collapse Figure 1C. The left, upper-chest field showed one huge bullous lesion. The CT scan showed a diaphragmatic hernia, intrathoracic perforation of the transverse colon, and pleural effusion Figure 1D and E. The diagnosis was confirmed as colon perforation-related fecopneumothorax with septic shock and acute renal failure.

We performed an emergent left-thoracoabdominal incision to explore and repair the colonic and diaphragmatic injuries at the same stage of surgery. The surgery started within 6 hrs after patient arrival at our emergency department. We identified the site of the diaphragmatic hernia and perforated colon in the left hemithorax, with a total of 700 cc of fecaloid effusion surrounding the area Figure 2A. Diffuse pleural thickening was noted Figure 2B. Suction of the thoracic fecaloid effusion and VATS decortication was performed to allow adequate lung expansion. The transverse colon was firmly incarcerated in the hiatal defect of the diaphragm Figure 2C and D. Therefore,

*Correspondence:

Mong-Wei Lin, Department of Surgery, National Taiwan University Hospital and National Taiwan University College of Medicine, Taipei, Taiwan, Tel: 886-2-2312-3456 (ext. 65085);
E-mail: mwlin@ntu.edu.tw

Received Date: 10 Sep 2018

Accepted Date: 10 Oct 2018

Published Date: 12 Oct 2018

Citation:

Sesma J, Lin M-W. Fecopneumothorax Surgery by Thoracoabdominal Incision after McKeown Esophagectomy. *Clin Surg.* 2018; 3: 2155.

Copyright © 2018 Mong-Wei Lin. This is an open access article distributed under the Creative Commons Attribution License, which permits unrestricted use, distribution, and reproduction in any medium, provided the original work is properly cited.

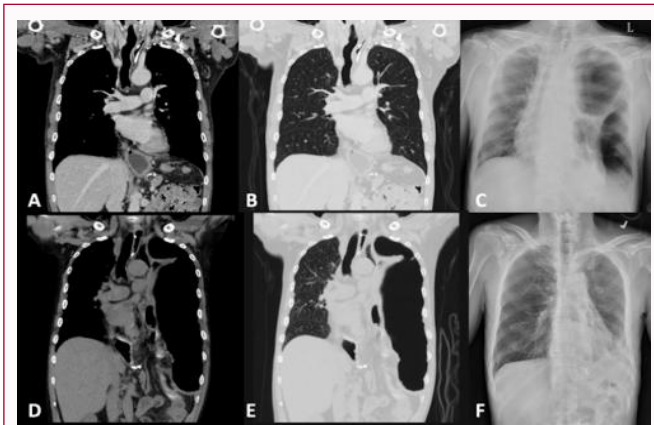


Figure 1(A-F): McKeown esophagectomy.

the peritoneal cavity was not contaminated with fecaloid effusion. Ischemic compromise and transverse colon perforation were found, so we performed a transverse colon necrotic portion resection at the level of the incarcerated site Figure 2E. Due to poor bowel preparation, we did not perform direct colon anastomosis. A double-barrel colostomy involving the proximal and distal end of the colon was performed. The diaphragmatic defect was repaired by primary suture. Thoracic and abdominal cavities were irrigated with warm saline fluid.

The patient's clinical condition improved after surgery. The inotropic agent was discontinued on the second postoperative day. Renal function recovered to the normal range. He was transferred to the general ward on the third postoperative day. His condition was complicated with limited surgical wound infection to the lower part of the wound. Wound culture revealed *Bacteroides fragilis* and *Enterococcus avium*. The wound condition improved after wound care and antibiotic therapy. The patient was discharged on postoperative day 33 Figure 1E and readmitted for colostomy closure 2 months postoperatively. No other complications occurred and the follow-up was uneventful.

Comment

Fecopneumothorax due to colonic perforation is an extremely rare presentation after esophagectomy [1,2]. To our knowledge, this is the third case of fecopneumothorax after esophagectomy; the first one was managed through a thoracoabdominal approach. Fecopneumothorax may occur from 2 months to 10 years after the first esophageal surgery. The first case underwent a left hemicolectomy, pleural cavity lavage, and primary transverse/sigmoid colon anastomosis [2]. The second case underwent colectomy for resection of the necrotic portion and primary anastomosis, thoracic irrigation, and debridement [1]. The surgical procedures of the previous two cases were both performed as two-stage surgeries: Laparotomy at the first stage and then thoracotomy at the second stage. Besides, the 2 previous cases underwent primary anastomosis despite poor colon preparation. By contrast, this case underwent a left thoracoabdominal approach with a double-barrel colostomy. The colostomy closure was performed 2 months after the first surgery.

Fecopneumothorax can lead to life-threatening conditions. Therefore, early surgical intervention with an appropriate approach is a key to achieve successful treatment. Instead of two-step surgeries with independent approaches, we propose a thoracoabdominal approach

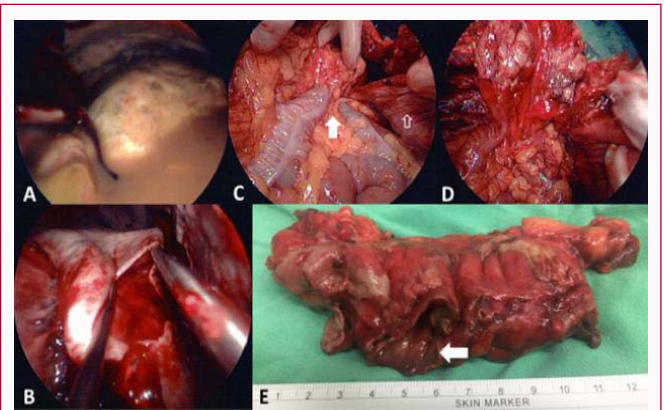


Figure 2(A-E): Emergent left-thoracoabdominal incision to explore and repair the colonic and diaphragmatic injuries at the same stage of surgery.

to allow full cleaning of the chest cavity and complete decortication, diaphragm repair, and colonic replacement and resection in a one-step surgery. As the surgical field is already contaminated in the thoracic area, a laparotomy for the perforated colon reduction and repair as the first stage of surgery may lead to contamination of the peritoneal cavity. We suggest that the thoracoabdominal approach allows better exposure of both cavities, thereby helping to perform meticulous decortication with subsequent diaphragmatic repair. In addition, colon replacement can be better performed via 2 cavities for visual control, to identify any thoracic or abdominal inconvenience during the repositioning maneuvers.

In the 2 reported cases, no loop colostomy was performed. As in our case, fecopneumothorax due to intrathoracic colonic perforation can lead to quick clinical worsening, severe septic shock, and multiple organ failure. Therefore, in this context, with poor colonic preparation and the presence of an already contaminated surgical field, loop colostomy and anastomosis in a second-stage operation could be a good strategy to avoid anastomotic site leakage and related complications. The colostomy closure may be scheduled 1-2 months after the first episode of sepsis recovery.

Although fecopneumothorax due to colonic perforation is an extremely rare presentation after esophagectomy, it can lead to life-threatening conditions. Thoracoabdominal incision is a safe and feasible approach that allows one-step surgery for thoracic and abdominal fields, helping colonic replacement maneuvers, decortication, and diaphragmatic repair. As the surgical field is already known to be contaminated, loop colostomy should be considered to avoid anastomotic site leakage and related complications.

Acknowledgement

The authors declare no conflicts of interest. This study was supported by the Ministry of Science and Technology, Taiwan (MOST105-2628-B002-011-MY2) and National Taiwan University Hospital, Taipei, Taiwan (NTUH107-N004038).

References

1. Kim KW, Lee JI, Kim JS, Park KY, Park CH, Jeon YB. Fecopneumothorax: a rare case of delayed colon diaphragmatic herniation following esophagectomy. *Indian J Surg*. 2015;77:117-9.
2. Markogiannakis H, Theodorou D, Tzertzelis D, Dardamanis D, Toutouzas KG, Misthos P, et al. Fecopneumothorax: a rare complication of esophagectomy. *Ann Thorac Surg*. 2007;84(2):651-2.

3. Chai Y, Zhang G, Shen G. Adult Bochdalek hernia complicated with a perforated colon. *J Thorac Cardiovasc Surg.* 2005;130(6):1729-30.
4. Seelig MH, Klingler PJ, Schönleben K. Tension fecopneumothorax due to colonic perforation in a diaphragmatic hernia. *Chest.* 1999;115:288-91.