



## Experimental Occipital Lobe Epilepsy in Cats: A Possible Model of Photic Epilepsy

Fujita T\* and Tanaka T

Department of Neurosurgery, Asahikawa Medical University, Asahikawa, Japan

### Abstract

Electroencephalographic and clinical observations were made after an injection of Kainic Acid (KA) solution through a chronically implanted cannula into a unilateral Visual Cortex (VC) of freely moving and unanesthetized cats. About 1 h after the KA injection, multiple spikes started at the injected site of VC and resulted in focal seizure status. About 2 h to 3 h after the injection, each seizure propagated to the right lateral Geniculate Body (GL), Mesencephalic Reticular Formation (MRF) and left visual cortex. These seizures developed and became generalized seizure status 3 h to 12 h after the injection. During interictal period, intermittent photic stimulations were occasionally tested and photoconvulsive responses were elicited. However, photosensitivity was not constant. Only several sessions of stimulation could have elicited photo-convulsive responses and generalized seizures in each animal. Then, seizures became infrequent and subsided within 30 h. The result demonstrated that KA induced VC seizure is not only applicable to study the mechanism of secondary generalization of the VC seizure but also study the possible mechanism of photically induced seizures.

**Keywords:** Kainic acid; Visual cortex; Lateral geniculate body; Photic stimulation; Photoconvulsive response; Generalized seizure, Photic epilepsy

### Introduction

The occipital lobe is the main center of the visual system. Occipital lobe epilepsy accounts for about 5% to 10% of all epilepsy. This kind of epilepsy can be either idiopathic or symptomatic. Among subtypes of occipital epilepsy, photosensitive epilepsy is characterized predominantly by generalized tonic-clonic seizures and commonly induced by flickering lights, or sunlight or television. Black-and-white striped patterns were also effective as precipitant of seizures. Moreover, surgical indication is often impossible due to the risk of visual field impairment in patients with medically refractory occipital lobe epilepsy. In this study, experimental occipital lobe epilepsy is induced by a microinjection of Kainic Acid (KA) in the unilateral visual cortex of rats. Several animal models were reported to be applicable to the visual cortical seizures or photosensitive epilepsy; they are visual cortical electrical stimulation [1,2], systemic application of the penicillin [3], focal cortical application of the Kainic Acid [4], systemic application of allylglycine or thiosemicarbazide following the lateral geniculate body kindling [5,6], genetic epilepsy model of Senegalese baboon *Papio papio* [7] and epileptic fowl [8]. Kainic acid (KA) is an analogue of the neuro-excitatory amino acids and has a potent excitatory effect [9]. It is known that neocortex contained glutamate receptors. Therefore, we injected KA into a unilateral occipital Visual Cortex (VC) in freely moving cats and elicited generalized seizure status. An electroencephalographic and clinical observations as well as an effect of Intermittent Photic Stimulation (IPS) were studied.

### Materials and Method

The submitted study was approved by the relevant research ethics committee of Asahikawa Medical University. Ten adult cats of both sexes (2.5 kg to 3.5 kg) were used in this study. Under pentobarbital anesthesia (35 mg/kg i.p.), stereotaxic operations were carried out under aseptic conditions. Stereotaxic coordinates were determined using the atlas of Jasper and Mone-Marsan [10]. Stainless-steel screws were placed bilaterally in the skull over the anterior sigmoid gyri and occipital cortices. A 25 gauge stainless steel pipe with inner needle guide for KA injection was inserted to the right occipital visual cortex (VC: A-6.0 L+2.0 D+12.5). Bipolar electrodes were placed into the bilateral lateral geniculate body (GL: A+7.5 L+10.5 D+2.5), right Mesencephalic Reticular Formation (MRF: A+3.0 L+3.0 D-1.8) and right dorsal hippocampus (HIP: A+2.0 L+8.5 D+6.0). IPS was applied and exact locations of electrodes of both GL were confirmed. The electrodes and cannula

### OPEN ACCESS

#### \*Correspondence:

Tsutomu Fujita, Department of Neurosurgery, Asahikawa Medical University, Asahikawa 078, Japan, Tel: +81-99-228-5053; E-mail: tominami@symphony.plala.or.jp

Received Date: 24 Jun 2022

Accepted Date: 08 Jul 2022

Published Date: 15 Jul 2022

#### Citation:

Fujita T, Tanaka T. Experimental Occipital Lobe Epilepsy in Cats: A Possible Model of Photic Epilepsy. *Clin Surg.* 2022; 7: 3550.

**Copyright** © 2022 Tsutomu Fujita. This is an open access article distributed under the Creative Commons Attribution License, which permits unrestricted use, distribution, and reproduction in any medium, provided the original work is properly cited.

were fixed with dental cement and electrodes were connected to the head socket. The animals were covered by warm blankets during the surgery. Cephalothin (300 mg/kg) was administered subcutaneously for 3 days following the operation. The animals were left free in the comfort cages at least 8 days for recovery from the operation. Then, they were placed in the recording chamber and clinical observations and EEG monitoring were done. The inner guide was removed and replaced with an injection needle connected to a catheter with a microinjector for microinjection. KA was dissolved with phosphate buffer solution (0.2M at pH 7.4) to a concentration of 20 µg/µl. The solution was sterilized with Millex-HA microfilters (0.45 µm filter unit). The KA solution (30 µg of KA) was injected into the right VC by a microinjector in seven cats. The rate of injection was 1 µl/min. The cannula was left in the place for 15 min. These procedures were done under aseptic conditions. Phosphate buffer solution (2 µl) was injected in 3 cats for a control study. EEG and clinical observations were performed up to one month, and IPS was occasionally tested. At the end of experiment, all survived cats were perfused with 10% formalin solution under a deep pentobarbital anesthesia (50 mg/kg i.p.). After fixation and embedding in paraffin, coronal section (5 µm in thickness) was made and processed for microscopic examination. The sections were stained with hematoxylin and eosin or cresyl-violet. Four cats were perfused immediately after the death due to generalized status.

## Results

Each KA injection into unilateral VC resulted in successive development of the seizure. In accordance with changes of EEG and behavior, we divided the seizure development into four stages.

### Stage 1 (Focal seizure status stage)

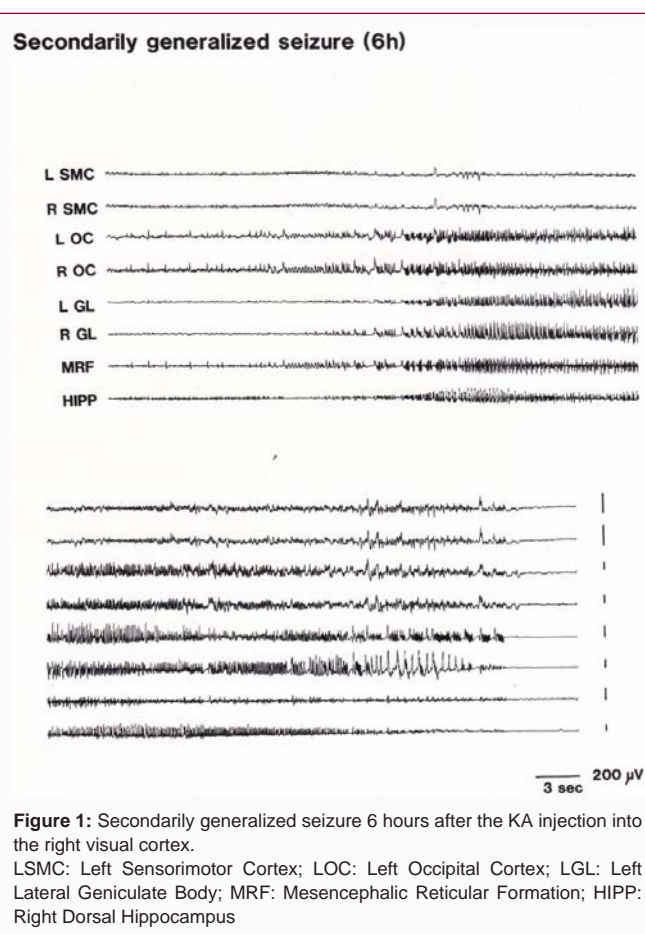
About 1 hour after the injection of KA into the right VC, multiple spikes started at the right VC (injected site). In this stage, these seizure activities were limited in the right VC and seizure propagation was not observed in the ipsilateral HIPP. Behavioral changes were not induced on this stage.

### Stage 2 (Partial seizure status stage)

About 2 h to 3 h after the KA injection, focal seizure status evolved and each seizure begun to propagate to the right GL, MRF and left VC. These seizures lasted for about 30 sec and repeated in every 20 min. Spike propagation to the sensori-motor cortex was not induced on this stage. However, at the middle of each seizure, seizure propagated to bilateral HIPP. Then, cats showed arrest of ongoing behavior during the seizure. IPS showed high amplitude reaction in the right VC and GL, but epileptic change was not yet triggered.

### Stage 3 (Generalized seizure status stage)

About 3 h to 6 h after the KA injection, secondarily generalized tonic-clonic seizures were frequently observed. Each seizure was initially provoked at the right VC, GL and MRF (injected site) simultaneously and then propagated to ipsilateral VC, GL, and bilateral sensori-motor cortex (Figure 1). Seizures lasted for about 30 sec to 60 sec and were found about once in every 10 min to 20 min. The initial behavioral changes of seizure development were the arrest of ongoing behavior and contralateral head turning to the side of injection. Then, the cat began to circle contralaterally, lost postural control and finally fell down with a generalized tonic-clonic convulsion. Limbic-type facial automatism or automatic symptom was not observed as an initial symptom. There was always latency from 5 sec to 10 sec for the seizure propagation to the hippocampus



**Figure 1:** Secondarily generalized seizure 6 hours after the KA injection into the right visual cortex.

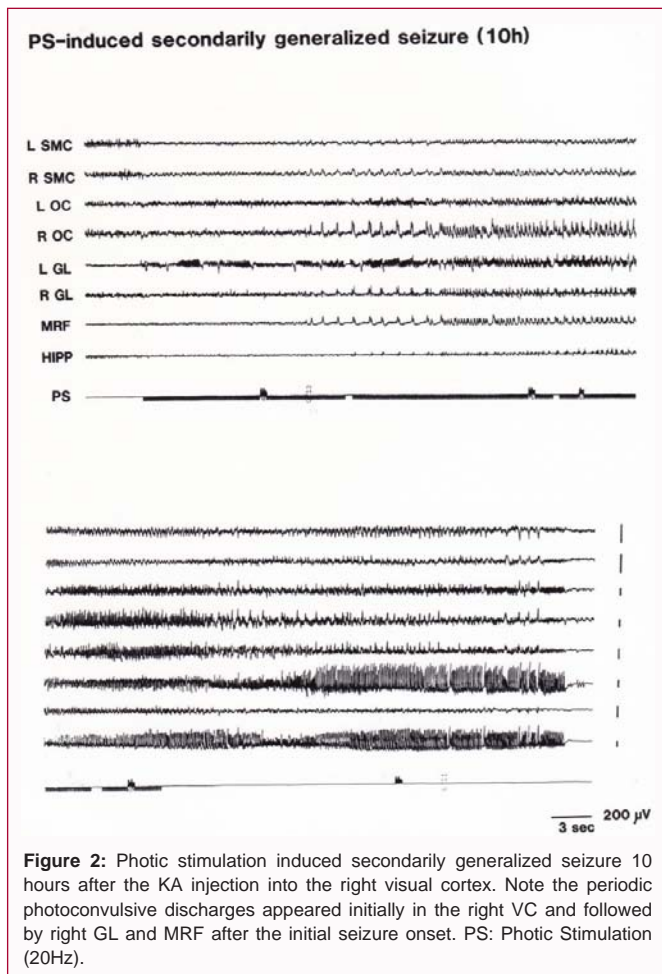
LSMC: Left Sensorimotor Cortex; LOC: Left Occipital Cortex; LGL: Left Lateral Geniculate Body; MRF: Mesencephalic Reticular Formation; HIPP: Right Dorsal Hippocampus

after each seizure onset from the VC. This phenomenon explained that these seizures were elicited by an epileptogenic focus in the VC but not from the focus of hippocampus. Occasionally, IPS evoked generalized tonic-clonic convulsion and optimal frequencies of these IPS were 14 Hz to 20 Hz (Figure 2). These photically induced seizures were characterized by an initial photo-convulsive response of periodic sharp waves in the KA-injected site of right VC and then followed by right GL and MRF. These seizures evolved to generalized seizures. However, it was very difficult to identify whether the seizure was naturally occurring secondarily generalized seizure or photically induced seizure. However, MRF participation to the seizure may be a very important role in the generalization of the photic epilepsy in this model. This stage continued for about 24 h. Two out of 7 cats were died on this stage during the intractable generalized status epilepticus.

### Stage 4 (Focal IID stage)

About 30 h after the KA injection, survived cats exhibited IID pattern only in the right VC (injected site) on EEG and returned to normal behavior. These epileptic phenomena subsided within 3 days after injection and cats became normal electro-clinically during following observation period. In 3 control cats, neither electrical change nor photically induced seizure was observed after the phosphate buffer injection.

Histopathological examination revealed circumscribed neuronal cell loss and pyknosis only in the right VC where KA was injected (Figure 3). There were no abnormal findings in the other structures including lateral geniculate body and limbic structures. In control cats, no histopathological change was observed at the injected site of



VC.

## Discussion

The present study demonstrated that the microinjection of KA into unilateral VC produced focal status epileptics and successive generalized status epileptics for about 30 h. In the early stage (stage 1), multiple spikes were induced only in the unilateral VC, then, the seizure propagated progressively to the subcortical structures (stage 2). In the stage 3, seizures propagated to the subcortical and bilateral sensori-motor cortex and resulted in generalized seizure status. In this special stage, acquired photosensitivity was occasionally observed. An IPS induced a focal seizure at the injected site of the VC and resulted in generalized tonic-clonic seizures. Clinical manifestations of these photically induced generalized seizures were analogous to those of KA-induced VC seizures. However, there were striking differences on EEG. The photically induced response was characterized by initial photo-convulsive responses of the right VC and right GL, and periodic sharp wave discharges and finally followed by secondarily generalized seizures. As generalized seizures reoccurred every 20 min in this stage, IPS was tested during the interictal periods. But IPS often failed to elicit seizure. In stage 4, only IID pattern in VC (injected site) were observed. About 48 h after KA injection, cats no longer exhibited epileptic manifestation. Their EEG and behavior returned normal. IPS no longer induced epileptic phenomena but usual evoked responses in VC and GL. On the other hand, Wada et al. [2] reported that VC kindling required significantly higher After-Discharge (AD) threshold and showed significantly



**Figure 3:** Photomicrograph of the right visual cortex stained with hematoxylin and eosin, showing neuronal cell loss and pyknosis (30 days after KA injection) at the injected site of visual cortex.

shorter duration of the initial AD than that in amygdaloid kindling. Marked seizure instability was also characteristic in their study. However, Montea and Singer [11] reported that none of the subjects developed a generalized convulsion by VC kindling. In contrast, in our study, a stable generalized seizure status was induced by KA injection. Monaghan [9] reported that binding sites for the [3H] Kainic acid have been isolated in neocortex and these receptors have been found to be especially enriched in the terminal fields of deep pyramidal layer [11]. This layer is expected to be most sensitive to the convulsant effects of the direct intracortical microinjection of this agent. Wada et al. [2] reported that electrode tip of VC kindled cat (2/7) was placed in the layer 6 but failed kindled cats (5/7) in the layer 4 or 5. Chatt and Ebersole [4] injected KA into occipital cortex and recorded Visual Evoked Potential (VEP). Their result was that low concentrations of KA injections (5  $\mu$ M to 50  $\mu$ M) never alter the control response, while moderate concentration of KA (0.5  $\mu$ M to 5  $\mu$ M) suppresses the control response. Higher concentration of KA (15  $\mu$ M) induces localized epileptiform abnormality and 50  $\mu$ M had diffuse hyperexcitability regardless of the cortical layer injected. However, their study was made under general anesthesia in an acute condition. Neither behavioral change nor electroencephalographic analysis was made. In our preliminary results, low dose of KA (1  $\mu$ g to 2  $\mu$ g) Injection into VC showed no response and 5  $\mu$ g to 10  $\mu$ g of KA injection only provoked localized spikes in the injected site of VC. Further propagation of seizure was not observed. High dose of KA (30  $\mu$ g to 80  $\mu$ g) injection Induced 24 h of generalized seizure status. Consequently, cortex required much KA than limbic structure did to induce epileptic phenomena. Histopathological examination revealed that cannula was placed in the cortical deep layer or superficial layer of the white matter. The results suggested that KA injection should have affected the deep pyramidal layer 6 and seizures should be induced as Monaghan and Cotman [9] had indicated. Another important finding is photically induced epileptic phenomena during stage 3 in this study. Until now, it was very difficult to study the basic mechanism of photically induced epilepsy. Because few animal models were known to be applicable to study the photically induced epilepsy and limited laboratories could afford this research with special equipment. Unfortunately, photosensitive reaction was not always elicited by IPS in the present study. Because we tested photosensitivity during interictal period during generalized seizure status. The effect of post-refractory period should have modified the true effect of IPS. However, the present feline model of photically induced epilepsy



requires no gorgeous equipment and is very easy to prepare a photosensitivity. Our result suggests that epileptic excitation of visual cortex precipitate the start of photosensitive epilepsy. It is important to note that epileptic excitation of the VC was always precede to those of the lateral geniculate body or frontal motor cortex. Moreover, MRF participation to the VC seizure may be play an important role in the generalization of photic epilepsy. This fact explains that our model is like those of human photosensitive epilepsy [12] and is different from those of photosensitive baboons [7].

In patients with drug resistant occipital lobe seizure, surgical resections of the epileptic foci often produce homonymous visual field defects on the contralateral side to the surgery. The present study demonstrated seizure propagation networks in a model of focal visual cortex seizure by ictal EEG. The seizure propagation from visual cortex initially propagated to subcortical structures such as lateral geniculate body, hippocampus, and mesencephalic reticular formation before seizure propagation to the motor cortex. Considering the scarcity of literatures covering the safe surgical procedures for drug resistant occipital lobe epilepsy, our results will suggest insights for less invasive modulation therapy, such as deep brain stimulation, radiofrequency thermocoagulation or focused ultrasound therapy for these deep structures to avoid serious visual problems in patients with drug resistant occipital lobe epilepsy. Further studies are required to confirm efficacy of modulation therapy in this model of visual cortex seizure.

## Conclusion

KA induced VC seizures are not only applicable to study a focal seizure of VC origin secondarily generalized but also important to study the mechanism of photically induced epilepsy.

## Acknowledgement

This study has been partly performed with the aid of the Japanese Ministry of Education, Science and Culture under No. 02857158 Grant-in-Aid for Encouragement of Young Scientists.

## References

1. Baba H. Facilitatory effects of intermittent photic stimulation on visual cortical kindling. *Epilepsia*. 1982;23(6):667-70.
2. Wada Y, Hasegawa H, Okuda H, Yosida K, Yamaguchi N. Kindling of the visual cortex in cats: Comparison with amygdaloid kindling. *Jpn J Psychiatr Neurol*. 1989;43(2):245-53.
3. Quesney L. Pathophysiology of generalized photosensitive in the cat. *Epilepsia*. 1984;25(1):61-9.
4. Chatt AB, Ebersole JS. The convulsant effects of kainic acid microinjection into cerebral cortex are concentration but not laminar dependent. *Exp Neurol*. 1989;103(1):105-9.
5. Wada Y, Okuda H, Hasegawa H, Jibiki I, Kido H, Yamaguchi N. A new experimental model for drug studies: effects of pentobarbital and phenytoin on photosensitivity in the lateral geniculate-kindled cat. *Epilepsia*. 1987;28(6):667-72.
6. Wada Y, Okuda H, Yamaguchi N, Yosida K. Effects of allylglycine on photosensitivity in the lateral geniculate-kindled cat. *Exp Neurol*. 1986;94(1):228-36.
7. Naquet R, Meldrum B. Photogenic seizures in Baboon: Experimental models of epilepsy - a manual for the laboratory worker, Raven Press, New York. 1972. p. 373-406.
8. Crawford RD. A new mutant causing epileptic seizures in domestic fowl. *Poultry Sci*. 1969;48:1799.
9. Monaghan D, Cotman C. The distribution of [3H] kainic acid binding sites in rat CNS as determined by autoradiography. *Brain Res*. 1982;252(1):91-100.
10. Jasper H, Ajimone-Marsan C. A stereotaxic atlas of the diencephalon of the cat. *Exp Neurol*. 1954;25:295-330.
11. Montea, M, Singer W. Critical period plasticity of kitten visual cortex is not associated with enhanced susceptibility to electrical kindling. *Dev Brain Res*. 1986;395(1):104-9.
12. Newmark E, Penry K. Photosensitivity and epilepsy: A review. Raven Press: New York 1979.