



Esophageal Cancer Showing Complete Remission of Nephrotic Syndrome after Neoadjuvant Chemotherapy Plus Surgery

Chao Cheng^{1*}, Weixiong Yang¹, Shuishen Zhang¹ and Sai-Ching Jim Yeung²

¹Department of Thoracic Surgery, The First Affiliated Hospital of Sun Yat-sen University, China

²Department of Emergency Medicine, The University of Texas MD Anderson Cancer Center, USA

Abstract

How to treat esophageal cancer with concurrent nephrotic syndrome is major challenge. We report a patient treated with neoadjuvant chemotherapy plus surgical resection of esophageal cancer, resulting in a complete remission of NS. The patient achieved partial response and down staged from cT₂N₁M₀ to cT_{1b}N₀M₀ after neoadjuvant chemotherapy (nedaplatin and liposomal paclitaxel). Using intravenous albumin to maintain serum albumin >30 g/L, esophagectomy *via* video-assisted Mckewon approach was performed with no major perioperative complications. There was no recurrence of cancer or relapse of NS at 32 months after surgery. We concluded that neoadjuvant chemotherapy plus esophagectomy with Mckewon approach seems to be safe and effective for esophageal cancer patient with NS, maintaining serum albumin >30 g/L may mitigate concerns of surgical complications.

Keywords: Esophageal cancer; Nephrotic syndrome; Neoadjuvant chemotherapy; Surgery

Introduction

Esophageal cancer with concurrent Nephrotic Syndrome (NS) has been rarely documented [1] and no clear guidelines for therapy decision or perioperative management of esophageal cancer patients with NS have been established. We herein documented a patient presenting with NS and esophageal cancer. He was treated with neoadjuvant chemotherapy and surgery, achieving complete remission of NS.

Case Presentation

A 52-year-old male with chief complaint of lower limb edema and mild dysphagia was admitted to our hospital. Blood biochemical tests showed hypoalbuminemia (23 g/L). Urinalysis showed proteinuria (3+) and the 24 hr urinary protein was 6.34 g/day. A diagnosis of NS was made. Histopathology and electron microscopy of a renal biopsy specimen demonstrated global thickening of basement membrane (Figure 1). Immunofluorescence microscopy showed granular deposits of IgG, C3 and C1q in the basement membrane. PET/CT indicated thickening of the lower thoracic esophagus and suspected paratumor lymph node metastasis. Endoscopic biopsy and histological analysis showed poorly differentiated squamous cell carcinoma. According to the 7th UICC TNM classification, the tumor was staged cT₂N₁M₀, IIB.

This challenging case was discussed by a Multidisciplinary Team (MDT) including thoracic surgeons, nephrologists, and radiation oncologists. Considering the clinical stage being IIB and high risk of surgery due to hypoalbuminemia (23 g/L), neoadjuvant chemotherapy with two 21-day cycles of nedaplatin (50 mg/kg on day 1) and liposomal paclitaxel (100 mg/kg on day 1) was recommended for the patient. After neoadjuvant chemotherapy, the tumor shrank and down staged to cT_{1b}N₀M₀, IB. The serum albumin level rose up to 30.6 g/L with albumin supplementation, while NS had not significantly improved (i.e., proteinuria 3+ and 24 hr urinary protein 6.00 g/day). No significant chemotherapy-related complications occurred.

The second MDT was conducted and reached a consensus recommendation to proceed with surgical resection. Esophagectomy *via* the video-assisted Mckewon approach was chosen and gastrointestinal tract reconstruction with neck anastomosis was performed. The pathologic stage was pT_{1b}N₀M₀, IB. After the operation, we used albumin 15 g intravenously every day to maintain

OPEN ACCESS

*Correspondence:

Chao Cheng, Department of Thoracic Surgery, The First Affiliated Hospital of Sun Yat-sen University, 58 Zhongshan 2nd Road, Guangzhou, 510080, China, Tel: 862087755766; Fax: +86-20-87332750;

E-mail: drchengchao@163.com

Received Date: 09 Feb 2019

Accepted Date: 12 Mar 2019

Published Date: 15 Mar 2019

Citation:

Cheng C, Yang W, Zhang S, Jim Yeung S-C. Esophageal Cancer Showing Complete Remission of Nephrotic Syndrome after Neoadjuvant Chemotherapy Plus Surgery. *Clin Surg*. 2019; 4: 2359.

Copyright © 2019 Chao Cheng. This is an open access article distributed under the Creative Commons Attribution License, which permits unrestricted use, distribution, and reproduction in any medium, provided the original work is properly cited.

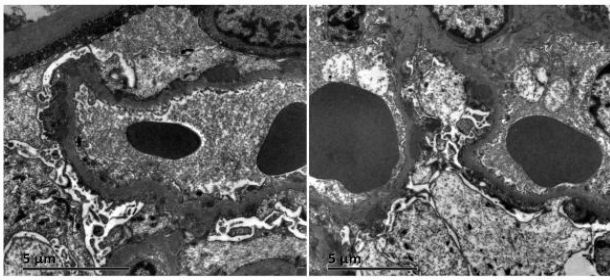


Figure 1: Electron microscopy of a renal biopsy specimen shows global thickening of the glomerular basement membrane without increased numbers of mesangial cells.

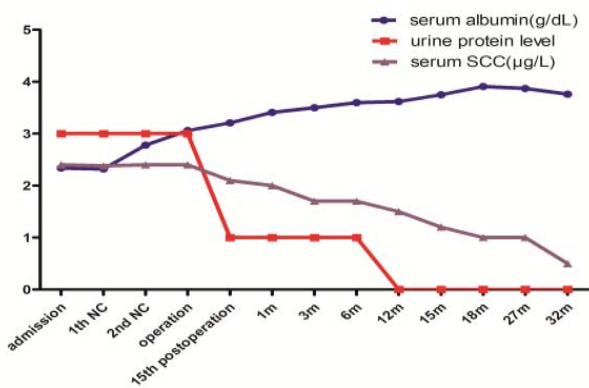


Figure 2: The relationships among urine protein level, serum albumin, and serum SCC from the diagnosis of NS to resolution of proteinuria.

the serum albumin >30 g/L. However, the average drainage of postoperative thoracic fluid was 710 ml/day. The chest drainage tube was remained until little drainage (240 ml) on the 12th postoperative day. The patient made an uneventful recovery after surgery and was discharged on the 15th postoperative day. Although he was still having proteinuria (2+) at the time of discharge, the level of Squamous Cell Carcinoma antigen (SCC) decreased from 2.40 µg/L at admission to 2.10 µg/L and continued to decline in follow-ups (Figure 2). At about one year after the operation, urinary protein was not detectable, which indicated that resolution of NS. There has been no recurrence of esophageal cancer or relapse of NS 32 months after the operation.

Discussion

Esophageal cancer with NS is a rare occurrence and its management is challenging [1]. To our knowledge, this is the first report to describe the resolution of NS after treatment of esophageal cancer with neoadjuvant chemotherapy and surgical resection.

Postoperative severe complications were previously reported, such as anastomotic leakage and lung atelectasis after esophagectomy requiring reintubation [2,3]. As a strategy to mitigate postoperative complications, we chose Mckewon surgery, two-field lymphadenectomy *via* video-assisted cervico-thoraco-abdominal approach with anastomosis in the neck other than in the chest. Fortunately, no major postoperative complications, such as anastomotic leakage, occurred in our patient.

Although paraneoplastic NS caused by esophageal cancer has an etiology mediated by immune mechanisms, high dose glucocorticoid treatment may not be advisable in tumor patient. This successful case shows that administration of albumin preparations (15 g per day) to maintain the albumin level >30 g/L was a very helpful tool in the perioperative period.

To summarize, neoadjuvant chemotherapy plus esophagectomy with Mckewon approach seems to be safe and effective for esophageal cancer patients with NS. Of note, keeping serum albumin level >30 g/L was helpful in the perioperative period to mitigate postoperative complications from NS.

References

1. Leeaphorn N, Kue-A-Pai P, Thamcharoen N, Ungprasert P, Stokes MB, Knight EL. Prevalence of cancer in membranous nephropathy: a systematic review and meta-analysis of observational studies. *Am J Nephrol.* 2014;40(1):29-35.
2. Naritaka Y, Asaka S, Miyaki A, Isohata N, Shimakawa T, Yamaguchi K, et al. A case of esophageal cancer showing complete remission of nephrotic syndrome after esophagectomy. *Anticancer Res.* 2010;30(9):3763-7.
3. Ito H, Kumagai Y, Iida M, Yamazaki S, Odajima H, Kawano T. A patient with esophageal cancer showing remission of nephrotic syndrome after esophagectomy: Report of a case. *Surgery Today.* 2013;43(12):1452-6.