



Entero-Scrotal Fistula in an Adult: A Complication of Traditional Health Care Practice in Ghana

Joachim KA Amoako^{1*}, Theodore Wordu², Philemon K Kumassah², Joelle M Amissah² and Michael Ohene-Yeboah¹

¹Department of Surgery, University of Ghana, Ghana

²Department of Surgery, Bator Catholic Hospital, Ghana

Abstract

Inguinal hernias are common in Ghanaian men. However, access to inguinal hernia surgery is limited. Considerable morbidity and significant mortality are associated with untreated, large, long standing inguinal hernias. Some patients with inguinal hernias seek relief from traditional health care providers. We present a case of entero-scrotal fistula in a 32-year-old man following treatment of an obstructed inguinal hernia by a traditional health care practitioner. A laparotomy was done with a limited right hemicolectomy and Nylon-darn repair of his inguinal hernia in a district general hospital with his full recovery.

Keywords: Inguinal hernia; Entero-scrotal fistula; Traditional health care practitioner

Introduction

Inguinal hernias are a common surgical condition worldwide. In Ghana, inguinal hernias occur in 10.8% of men [1]. However, the surgical repair rate is estimated at a low 30 per 100, 000 of the population per year [2]. Untreated inguinal hernia limits agricultural activity such as crop production and fishing and social life [3]. As a result of limited understanding of inguinal hernia disease process, high cost of (orthodox) health care and inadequate capacity for surgical care at the health facilities in rural communities, many patients with untreated inguinal hernias seek help from traditional health care practitioners. We present a case of entero-scrotal fistula in one of these patients.

Case Presentation

A 32-year-old man presented to a district general hospital, complaining of a discharging wound on the scrotum for one month. Over the previous 12 months, he had been aware of a mass in his right groin which occasionally disappeared. He experienced an occasional dragging pain in the mass which was worse anytime he engaged in manual activity. The mass usually disappeared with relief of his pain when he lay down for some time. Four weeks prior to presentation, he experienced severe pain in the swelling. This time the swelling did not disappear even when he lay down. Over the next four days he developed abdominal pain, vomited several times and noticed he had become very weak. He consulted the traditional health care practitioner who was his brother. Following treatment, the abdominal pain resolved, and he stopped vomiting. However, he soon noticed that he did not pass stool or flatus. There was a persistent offensive discharge from a wound on the scrotum. The wound failed to heal after a month. He therefore decided to go to the hospital.

On clinical examination, he was mildly dehydrated. He was not pale or jaundiced. His body temperature was 36.9°C. His blood pressure was 132/68 mmHg and his pulse rate was 76 beats per minute. Clinical examination of the chest revealed no abnormalities. His abdomen was soft, with no areas of tenderness, guarding or rebound tenderness. There was a 10 cm long segment of viable bowel that had eviscerated through a right groin wound (Figure 1A and 1B). The mucosa of the bowel was exposed. There was discharge of feculent fluid from the bowel. The skin wound edges were clean and healing and the scrotal skin was normal.

His haemoglobin, white blood cell count, platelets count, creatinine, urea, potassium, sodium and serum albumin levels were normal. The patient was resuscitated and informed consent was obtained for a laparotomy under general anesthesia. At laparotomy, urethral catheters were passed into two openings in the eviscerated bowel. It was found by palpation for the catheters intra-abdominally that a larger supero-lateral opening in the eviscerated bowel was continuous with the ascending

OPEN ACCESS

*Correspondence:

Joachim KA Amoako, Department of Surgery, School of Medicine and Dentistry, University of Ghana, PO Box GP 4236, Accra, Ghana, Tel: +233244973093;

E-mail: Joachim_amoako@yahoo.com

Received Date: 19 Jun 2018

Accepted Date: 11 Jul 2018

Published Date: 14 Jul 2018

Citation:

Amoako JKA, Wordu T, Kumassah PK, Amissah JM, Ohene-Yeboah M. Entero-Scrotal Fistula in an Adult: A Complication of Traditional Health Care Practice in Ghana. *Clin Surg*. 2018; 3: 2025.

Copyright © 2018 Joachim KA Amoako. This is an open access article distributed under the Creative Commons Attribution License, which permits unrestricted use, distribution, and reproduction in any medium, provided the original work is properly cited.



Figure 1A and 1B: Photographs showing the fistula at presentation (A) and before skin preparation in theatre (B).

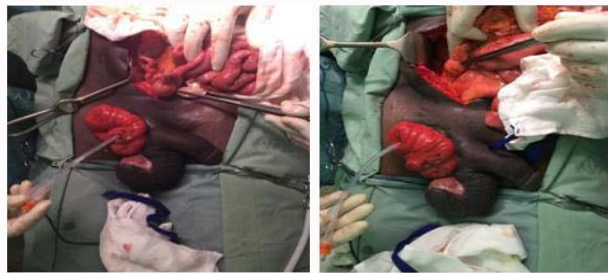


Figure 2A and 2B: Photographs of catheterized ileum (A) and ascending colon (B).

colon while a smaller infero-medial opening was continuous with the terminal ileum (Figure 2A and 2B). The right testis was exposed. A limited right hemicolectomy was performed with end-to-end hand-sewn ileocolic anastomosis. The inguinal incision was extended laterally and herniotomy and Nylon-darn herniorrhaphy were done. A right orchidopexy was also performed. The patient had an uneventful postoperative period and was discharged home seven days after the operation (Figure 3).

Discussion

The prevalence of inguinal hernias in Ghanaian men is 10.8% with a repair rate estimated at just 30 per 100, 000 of the population per year [1,2]. In contrast, the repair rate in the United States of America is 275 per 100, 000 of the population per year [4]. Access to inguinal hernia surgery in Ghana is limited in part by lack of trained surgeons and anaesthetists, the cost of surgery and anaesthesia, and the lack of patient education on the disease. We present a case of entero-scrotal fistula in a young Ghanaian male following incision of an obstructed right inguinoscrotal hernia as treatment by a traditional health care practitioner who was his brother. He had no electrolyte abnormalities and underwent a laparotomy with a limited right hemicolectomy and nylon darn repair of his hernia with an uneventful recovery. The fact that the traditional health care practitioner is brother to the patient may have played a role in his decision to seek initial care from him. Entero-scrotal fistulas commonly occur spontaneously in neglected Richter's hernias. The obstruction to less than two thirds of the circumference of the bowel wall in some cases allows for continuous passage of luminal contents. Therefore, symptoms of intestinal obstruction do not occur and diagnosis is difficult or delayed. The prolonged obstruction to the blood supply of part of the bowel wall predisposes it to gangrene, necrosis and fistulation. These fistulae usually occur in the paediatric age group and are rare in adults [5-7]. Indeed, a previous report from Ghana was in an adult male who lost two months of farm work [5].

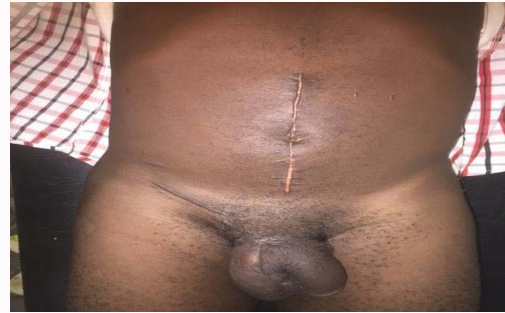

Figure 3: Photograph of patient two weeks after surgery.

Reports of entero-scrotal fistulae following incision by a traditional health care practitioner are rare. Nwabunike (1984) reported three cases of entero-scrotal fistulae following incision by traditional health care providers who mistook the obstructed hernias for abscesses [4]. The incision in the obstructed hernia in this index case went deep through the trapped caecum, and led to the discharge of its luminal content. This allowed the proximal bowel to empty continuously over the next month but without continuity with the distal segment. The integrity of the intra-abdominal small bowel was not disturbed, and this enabled adequate absorption of food nutrients and may partly explain his relatively good nutritional status at presentation. In the absence of scrotal necrosis, the bowel healed to the scrotal skin edges resulting in maturation of the fistula.

Conclusion

This unique case report of a complication and associated morbidity of treatment of inguinal hernia by a traditional health care practitioner in Ghana is preventable. It is further evidence for concerted effort to increase the elective inguinal hernia repair rate in Ghana.

References

- Ohene-Yeboah M, Beard JH, Frimpong-Twumasi B, Koranteng A, Mensah S. Prevalence of Inguinal Hernia in Adult Men in the Ashanti Region of Ghana. *World J Surg.* 2016;40(4):806-12.
- Grimes CE, Law RS, Borgstein ES, Mkandawire NC, Lavy CB. Systematic review of met and unmet need of surgical disease in rural sub-Saharan Africa. *World J Surg.* 2012;36(1):8-23.
- Nwabunike TO. Enterocutaneous fistulas in Enugu Nigeria. *Dis Colon Rectum.* 1984;27(8):542-4.
- Rutkow IM. Demographic and socioeconomic aspects of hernia repair in the United States in 2003. *Surg Clin North Am.* 2003;83(5):1045-51.
- Ohene-Yeboah M. Entero-scrotal fistula in a Ghanaian adult: a case report of spontaneous rupture of a neglected strangulated inguinal hernia. *Hernia.* 2011;15(4):455-7.
- Rattan KN, Garg P. Neonatal scrotal fecal fistula. *Pediatr Surg Int.* 1998;13(5-6):440-1.
- Ghritlaharey RK, Shrivastava DK, Kushwaha AS. Spontaneous scrotal faecal fistula in infant: a case report and literature review. *J Clin Diag Res.* 2007;4:303-6.