



# Endoscopic Management for Posterior Hip Pain as Deep Gluteal Syndrome (DGS)

Myung-sik Park<sup>1\*</sup>, Hong-man Cho<sup>2</sup>, Joon-Soo Ha<sup>3</sup> and Hyung-bae Park<sup>4</sup>

<sup>1</sup>Department of Orthopedic Surgery, Hosung Jeonju Hospital, Republic of Korea

<sup>2</sup>Department of Orthopaedic Surgery, Gwangju Veterans Hospital, Republic of Korea

<sup>3</sup>Department of Orthopaedics, King's College Hospital, UK

<sup>4</sup>Department of Biology, Chonbuk University, Republic of Korea

## Abstract

**Purpose:** The purpose of this study is to assess the effectiveness of endoscopic sciatic neurolysis of deep gluteal syndrome and evaluated the differences of clinical results according to pathology.

**Methods:** Retrospective study of 85 hips (85 patients, 45 males and 40 female) with mean age of 50.5 year old (range, 19 to 77 years old) with DGS treated with an endoscopic technique between 2009 and 2018 with a minimum follow-up of 12 months. Compromising structures were divided five groups: hypertrophied vascular nest in 46 hips, piriformis in 16 hips, other short external rotator in 10 hips, soft tissue mass in 3 hips and pelvic trauma in 10 hips. The patients were evaluated pain score using VAS and function by modified HHS and postoperative satisfaction graded by Benson score. Statistical significance was evaluated ( $p > 0.05$ ).

**Results:** We identified all scores improved. The Benson score was  $2.82 \pm 0.85$  ( $p = 0.56$ ), mean VAS  $5.69 \pm 0.89$  to  $2.30 \pm 1.72$  ( $P = 0.32$ ), and the mean mHHS increased from  $65.85 \pm 5.50$  to  $91.40 \pm 5.80$  ( $P = 0.002$ ). Usually pain and function improve in all groups except trauma group. Trauma group was significantly lower scores versus non trauma group ( $p = 0.04$ ). Five patient complaint persistent pains, which were managed with second look in one patient and others, were managed with NSAIDs and sono-guided steroid injection. There were no complications related with endoscopic procedure.

**Conclusion:** Endoscopic sciatic neurolysis offers an alternative management of DGS by improving functionality and reducing pain levels in selected patients. Recurred pain should be evaluated sacroiliac joint pathology, spine disorder, and depression.

**Keywords:** Hip; Endoscopy; Sciatic nerve; Deep Gluteal Syndrome (DGS)

## Introduction

Hip arthroscopy is now widely introduced and used as diagnosis hip pathology and management of for Femoroacetabular Impingement (FAI) that showed good results [1,2]. Many papers suggest that non discogenic sciatica defined piriformis syndrome, which usually covered posterior hip pain [3,4]. Recently Deep Gluteal Syndrome (DGS) has been introduced but not well known phenomenon [5]. DGS is an underdiagnosed entity characterized by pain and/or dysesthesias in the buttock area, hip or posterior thigh and/or radicular pain due to a non-discogenic sciatic nerve entrapment in the subgluteal space. Multiple pathologies have been incorporated in this all-inclusive "piriformis syndrome", a term that has nothing to do with the presence of fibrous bands, obturator internus/gemelli syndrome, quadratus femoris/hamstring pathology, gluteal disorders and orthopedic causes [5,6]. We defined hip endoscopy means the procedure to extra-articular abnormalities. Posterior hip pain and related back pain were commonly managed with conservative or ultrasound guided NSAID injection. If symptoms persisted in spite of conservative management, they can be managed with open and endoscopic management [7-11]. We report hip endoscopic management for posterior hip pain from DGS, subcategorized according to its cause, and its outcomes.

## Material and Methods

Between September 2009 and February 2018, sciatic neurolysis was performed using hip endoscopic techniques in 85 hips (85 patients, 45 males and 40 female). Mean age was 50.2 years (range, 19 to 77 years) at time of surgery. This study includes more than one year follow up.

## OPEN ACCESS

### \*Correspondence:

Myung-sik Park, Department of Orthopedic Surgery, Hosung Jeonju Hospital, Republic of Korea, E-mail: hugo999@daum.net

Received Date: 19 Apr 2019

Accepted Date: 28 May 2019

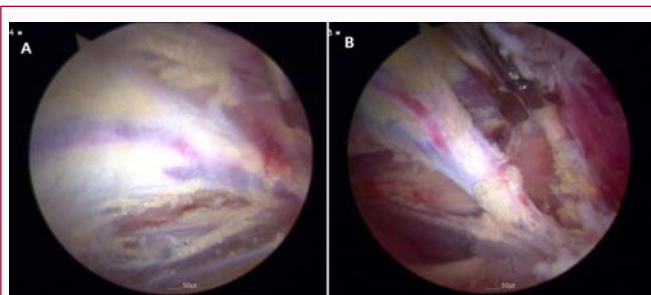
Published Date: 04 Jun 2019

### Citation:

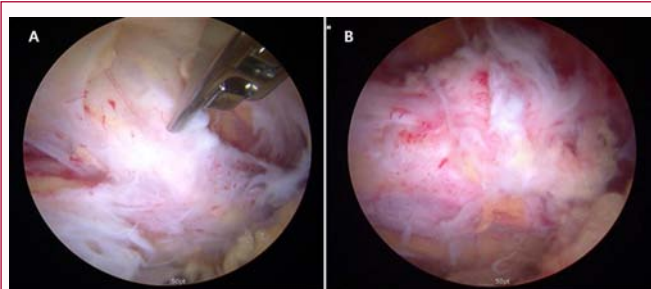
Myung-sik Park, Hong-man Cho, Joon-Soo Ha, Hyung-bae Park. Endoscopic Management for Posterior Hip Pain as Deep Gluteal Syndrome (DGS). Clin Surg. 2019; 4: 2460.

Copyright © 2019 Myung-sik Park.

This is an open access article distributed under the Creative Commons Attribution License, which permits unrestricted use, distribution, and reproduction in any medium, provided the original work is properly cited.



**Figure 1:** A 52-year-old woman showed DGS. A) Vascular nest on sciatic nerve. B) Vessels were cauterized and resected.



**Figure 2:** A 47-year-old man who had taken posterior wall fracture of acetabulum, A) Scar tissue adhered to sciatic nerve; B) Nerve is glide after resection of scar tissue.

Preoperative diagnosis of DGS was based on clinically walking pain, sitting pain (>30 min), tenderness, paresthesia. Pain was aggravated in FADIR (Flexion Adduction and Internal Rotation) and seated piriformis test [5]. All patients had plain hip X-ray (anteroposterior, axial, Dunn 45° view, cross-table view) and Magnetic Resonance Image (MRI). We confirmed Femoroacetabular Impingement (FAI) in symptomatic patient and alpha angle more than 55° at Dunn 45 and oblique axial view of MRI hip [12]. All radiographic images are acquired digitally through the Picture Archiving and Communication System (PACS, Marotech Maroview, and Seoul).

Hip arthroscopy was performed routinely central part first. After traction released, we make an ancillary posterolateral portal as working portal and viewing portal used in previous anterolateral portal of hip arthroscopy procedure. Compromising structures as a hypertrophied vascular nest were carefully cauterized with radiofrequency ablation. Piriformis muscle, obturator internus and Gemelli or hamstring muscles were partially resected perpendicular to epimysium. Sometimes, pelvic and or acetabular fracture managed with open methods resulted posterior hip pain. Sciatic nerve may be irritated and or compressed by hardware including proximal screw of intramedullary nailing and dome screw of acetabular cup in Total Hip Arthroplasty (THA). We divided the causes of compromise into five groups. Group 1 is fibro vascular group in 46 hips, Group 2 is piriformis muscle group in 16 hips, Group 3 is short external rotation group i.e. obturator internus, gemelli and or quadratus femoris muscles in 10 hips, Group 4 is trauma group by acetabular fracture and or hardware e.g. protrude screw in 10 hips, Group 5 is soft tissue mass as simple cyst or schwannoma in 3 hips (Table 1). We exclude one hip which shows dome screw of acetabular cup irritating sciatic nerve at greater sciatic notch [13]. We evaluated pain outcomes using VAS score and functional outcomes by a modified Harris hip score preoperative and postoperatively [14]. Postoperative satisfaction was evaluated using a Benson score (Table 2) [7]. Statics were performed

**Table 1:** Demographic data.

Variables	Total 85 hips (84 patients)
Age	50.3 (range, 19 to 77) years old
Sex	Total 85 hips ( 85 patients, 45 male/ 40 female)
Group	Group 1 (46 hips), Fibrovascular group
	Group 2 (16 hips). Piriformis muscle
	Group 3 (10 hips), Obturator internus Gemelli group.
	Group 4 (10 hips), Trauma (Pelvic Fracture and proximal hip fractures)
	Group 5 (3 hips), Cystic mass (Schwannoma and cyst)
VAS	5.69 (preop) - 2.27 (postop)
Benson's score	2.93 ± 0.85 (post op)
mHHS	65.589 (51.7-80.3) preop-91.09 (69.5-100) postop

by SPSS software (version 18.0; SPSS Inc. Chicago, IL) was used for all the analyses. The difference of VAS, mHHS and Benson score at postoperative follow-up were analyzed using paired-sample t-tests. The differences of clinical outcome scores in five groups were compared using the repeated measures ANOVA (with p<0.05 to determine significance).

### Results

We evaluated 85 hips which follow up period was more than one year. Combined FAI was 47 hips (55%) and patients who had taken previous spine surgery like a discectomy and posterior lumbar interbody fusion in 13 patients (15%). The mean scores of Benson score is 2.93. The VAS scores improved from 5.69 to 2.27, and mHHS improved from 65.58 to 91.09 (p=0.02). Group 1 with 46 hips reveals mean Benson's score was 2.91, VAS score improved from 5.70 to 2.52 and mHHS 65.65 ± 46.07 to 91.07 ± 6.34, (p=0.45). Group 2 with 16 hips reveals mean Benson's score was 3.00, VAS scores improved from 5.53 to 1.80, mHHS 66.60 ± 5.55 to 93.60 ± 4.06 (p=0.67). Group 3 with 10 hips reveals mean Benson's score 3.00, VAS score 5.60 to 1.70, mHHS 64.90 ± 0.00 to 92.37 ± 4.54, (p=0.34). Group 4 with 10 hips reveals mean Benson's score 2.64, VAS score improved 5.82 ± 2.64, mHHS 66.70 ± 6.28 to 87.90 ± 4.66 (p=0.04). Group 5 with 3 hips resulted mean Benson's score 3.67, VAS score 6.33 to 1.33, mHHS 67.12 ± 3.38 to 97.53 ± 4.27 (p=0.12) (Table 3).

These results show soft tissue mass and musculotendinous compression group resulted in favorable outcomes. Post traumatic trauma group showed unsatisfactory outcomes associated with surrounding soft tissue atrophy and adhesions aggravating the disease. Five patients complained of persistent pain in follow up. These patients were primarily diagnosed as fibro vascular group in 4 patients and trauma in one patient. One patient required a second look group and others are managed with NSAID and steroid injection.

### Discussion

Hip endoscopic management for sciatic nerve pathology is very challenging. There were few articles for sciatic nerve neurolysis using endoscopic techniques. The progression in understanding posterior hip anatomy and sciatic nerve kinematics has helped to identify several locations where the sciatic nerve can be entrapped. For that reason, the deep gluteal syndrome instead of piriformis syndrome is now preferred to describe the presence of pain in the buttock caused from nondiscogenic and extra pelvic entrapment of the sciatic nerve [15,16]. The structures that can be involved in sciatic nerve entrapment within gluteal space include the piriformis muscle, fibrous

**Table 2:** Benson's surgical outcomes rating.

Outcomes	Symptoms
Excellent (4)	No pain with prolonged periods of sitting (>30 min), strenuous activity, bending, twisting, stairs, rapid walking, jogging
Good (3)	No pain with short periods of sitting ( $\leq$ 30 min) or daily activities or mild pain with prolonged periods of sitting or strenuous activity.
Fair (2)	Occasional mild pain with short periods of sitting or normal daily activities or moderate pain with prolonged sitting or strenuous activity.
Poor (1)	Severe pain with short periods of sitting or normal daily activities, little change from preoperative level of pain associated with sciatic nerve.

**Table 3:** Pain and functional evaluations according to Group (causes).

Etiology	Benson Score	Preop VAS	Postop VAS	Preop mHHS	Postop mHHS	P value
Group 1	2.91	5.7	2.52	65.65 ( $\pm$ 6.07)	91.02 ( $\pm$ 6.55)	0.456
Group 2	2.94	5.56	1.81	66.50 ( $\pm$ 5.37)	93.63 ( $\pm$ 4.10)	0.676
Group 3	3	5.6	1.7	64.90 ( $\pm$ 000)	92.37 ( $\pm$ 4.54)	0.341
Group 4	2.7	5.8	2.7	64.07 ( $\pm$ 6.28)	84.44 ( $\pm$ 7.15)	0.04
Group 5	3.67	6.33	1.33	67.13 ( $\pm$ 3.86)	96.60 ( $\pm$ 3.73 )	0.123

bands containing blood vessel, gluteal muscles, hamstring muscles, the Gemelli-obturator internus complex, vascular abnormalities and space occupying lesions [5,17-25]. There may be anatomical variation of sciatic nerve course. The sciatic nerve passing below the piriformis muscle usually (84%) and some variation nerve divided between and below the muscle (12%) [26,27]. These variations should be expected when surgeon undertake hip endoscopy for DGS.

Deep gluteal syndrome is a condition that sciatic nerve is compressed by any structures in deep gluteal space. The chief symptom was caused by sciatic nerve entrapment surrounding structures which usually cause a buttock pain and also complaint include inability to tolerate long periods sitting (more than 30 min) [5]. These pains become worse during sitting, walking and hip flexion movement combined with hip internal rotation. Also, these patients may complain radicular pain of affected leg, much like nerve root pain associated with lumbar disc disease [18]. Previously the term "piriformis syndrome" was used as a broad term to include deep gluteal syndrome [5]. Filler et al., [15] described the source of nondiscogenic sciatic entrapment in 239 patients, and the most common sites were beneath the piriformis muscle (67.8%), sciatic foramen (6%), ischial tunnel (4.7%), followed by the additional sources pain. However, any structures in deep gluteal region can cause this syndrome by compression sciatic nerve, so sciatic nerve entrapment syndrome or deep gluteal syndrome may be a proper representation. There are a number of etiological factors of sciatic nerve entrapment syndrome, such as direct trauma of buttock or pelvis, hypertrophy of muscles in deep gluteal region, hematoma or neoplasm and anatomical variants between piriformis and sciatic nerve, etc. [4,10,11]. It is important to be aware of possible anatomical variation bifurcation of the sciatic nerve through the muscles [18]. Proper diagnosis of DGS is uncertain by plain radiography and MRI, and can be supported by clinical symptoms and physical examination [5]. To determine the diagnostic accuracy of clinical tests for sciatic nerve entrapment in gluteal region, the active piriformis and seated piriformis stretch test to help identify the patients can be used with and without sciatic nerve entrapment [28]. Advancement in MRI allows to observe unilateral hypertrophy and bowing of the sciatic nerve [29]. In these cases, most patients complain of sensory change around buttock and posterior thigh. Our indications for hip endoscopy are persistent pain and limitation of motion in spite of NSAIDs and sono-guide steroid injection.

Issack et al., [8] reported management of sciatic nerve neuropathy associated fracture or reconstructive surgery of the acetabulum by

open method. After open methods, most sensory symptoms are improved for minimum of one year, but there were no patients with worsening of neurologic examination after release. They reported also improved symptoms of a tenderness and or paresthesia of affected leg after surgery and some improvement of foot drop. However, there are risks associated with open technique such as hematoma, infection and poor cosmesis and long rehabilitation time.

In this study 5 patient complaints with recurrent pain and paresthesia around buttock. We recommend recurred symptoms should be evaluated for sacroiliac disease, concomitant spinal disorder, and psychological factors. Posterior hip pain commonly presents in a chronic fashion significantly affecting the quality of life. Therefore, a psychological evaluation before any treatment is recommended for patients complaining of chronic pain more 6 months, who are using narcotics, and have significantly impaired social function. Psychological strategies for diagnosing depression and anxiety disorders related with chronic pain have shown high specificity and reliability. These factors could affect the outcomes and the satisfaction of the patient and the surgeon [30].

This endoscopic management shows improvement of sitting pain and sensory changes around buttocks and minimal complications [5,6]. We postulate the incidence of endoscopy complication rate using the hip arthroscopy for FAI will be similar with reports that less than 1% and 8% of open surgical procedures and 0% and less than 1% of endoscopic procedures resulted in major (deep wound infection) and minor complications, respectively [2]. Aguilera-Bohorques et al., [9] reports endoscopic management of sciatic nerve in 44 operations of 42 patients. One patient continued to manifest residual pain of the posterior cutaneous the residual pain related with posterior cutaneous femoral nerve pain. Four cases required revision at 6 months following the procedure due to compression of the scarred tissue surrounding the sciatic nerve.

We did not find any complication related endoscopy surgery but persistent pain in five patients. It requires dedicated training and learning curve however can offer successful results in well-selected patient according to indication and experience of the surgeon.

Our limitations are short term follow up and small volume evaluation. In general procedure, endoscopic surgeries are widely used as its convenience and minimal skin incision. Along with hip arthroscopy. This sciatic neurolysis will require development before new surgical techniques can be introduced.

## Conclusion

Endoscopic sciatic neurolysis offers an alternative management of DGS by improving functionality and reducing pain levels in appropriately selected patients. Recurred pain should be evaluated for sacroiliac joint pathology, spine disorder, and depression.

## References

- Menge TJ, Briggs KK, Dornan GJ, McNamara SC, Philippon MJ. Survivorship and Outcomes 10 Years Following Hip Arthroscopy for Femoroacetabular Impingement: Labral Debridement Compared with Labral Repair. *J Bone Joint Surg Am.* 2017;99(12):997-1004.
- Zhang D, Chen L, Wang G. Hip arthroscopy versus open surgical dislocation for femoroacetabular impingement: A systematic review and meta-analysis. *Medicine (Baltimore).* 2016;95(41):e5122.
- Cass SP. Piriformis syndrome: a cause of nondiscogenic sciatica. *Curr Sports Med Rep.* 2015;14(1):41-4.
- Parziale JR, Hudgins TH, Fishman LM. The piriformis syndrome. *Am J Orthop (Belle Mead NJ).* 1996;25(12):819-23.
- Martin HD, Reddy M, Gómez-Hoyos J. Deep gluteal syndrome. *J Hip Preserv Surg.* 2015;2(2):99-107.
- Hernando MF, Cerezal L, Carro LP, Abascal F, Canga A. Deep gluteal syndrome: anatomy, imaging, and management of sciatic nerve entrapments in the subgluteal space. *Skeletal Radiol.* 2015;44(7):919-34.
- Benson ER, Schutzer SF. Posttraumatic piriformis syndrome: diagnosis and results of operative treatment. *J Bone Joint Surg Am.* 1999;81:941-9.
- Issack PS, Kreshak J, Klinger CE, Toro JB, Buly RL, Helfet DL. Sciatic nerve release following fracture or reconstructive surgery of the acetabulum. Surgical technique. *J Bone Joint Surg Am.* 2008;90:227-37.
- Aguilera-Bohorquez B, Cardozo O, Brugiatti M, Cantor E, Valdivia N. Endoscopic treatment of sciatic nerve entrapment in deep gluteal syndrome: Clinical results. *Rev ESP Cir Orthop Traumatol.* 2018;62(5):322-7.
- Martin HD, Shears SA, Johnson JC, Smathers AM, Palmer IJ. The endoscopic treatment of sciatic nerve entrapment/deep gluteal syndrome. *Arthroscopy.* 2011;27(2):172-81.
- Park MS, Yoon SJ, Jung SY, Kim SH. Clinical results of endoscopic sciatic nerve decompression for deep gluteal syndrome: mean 2-year follow-up. *BMC Musculoskelet Disord.* 2016;17:218.
- Smith KM, Gerrie BJ, McCulloch PC, Lintner DM, Harris JD. Comparison of MRI, CT, Dunn 45° and Dunn 90° alpha angle measurements in femoroacetabular impingement. *Hip Int.* 2018;28(4):450-5.
- Yoon SJ, Park MS, Matsuda DK, Choi YH. Endoscopic resection of acetabular screw tip to decompress sciatic nerve following total hip arthroplasty. *BMC Musculoskelet Disord.* 2018;19(1):184.
- Byrd JW, Jones KS. Arthroscopic femoroplasty in the management of cam-type femoroacetabular impingement. *Clin Orthop Relat Res.* 2009;467:739-46.
- Filler AG, Haynes J, Jordan SE, Prager J, Villablanca JP, Farahani K, et al. Sciatica of nondiscogenic origin and piriformis syndrome: diagnosis by magnetic resonance neurography and interventional magnetic resonance imaging with outcome study of resulting treatment. *J Neurosurg Spine.* 2005;2:99-115.
- McCrory P, Bell S. Nerve entrapment syndromes as a cause of pain in the hip, groin and buttock. *Sports Med.* 1999;27(4):261-74.
- Robinson DR. Piriformis Syndrome in Relation to Sciatic Pain. *Am J Surg.* 1947;73(3):355-8.
- Carro LP, Hernando MF, Cerezal L, Navarro IS, Fernandez AA, Castillo AO. Deep gluteal space problems: piriformis, ischiofemoral impingement and sciatic nerve release. *Muscles Ligaments Tendons J.* 2016;6(3):384-96.
- Puranen J, Orava S. The hamstring syndrome. A new diagnosis of gluteal sciatic pain. *Am J Sports Med.* 1988;16(5):517-21.
- Young IJ, van Riet RP, Bell SN. Surgical release for proximal hamstring syndrome. *Am J Sports Med.* 2008;36(12):2372-8.
- Cox JM, Bakkum BW. Possible generators of retro trochanteric gluteal and thigh pain: the gemelli-obturator internus complex. *J Manipulative Physiol Ther.* 2005;28:534-8.
- Meknas K, Kartus J, Letto JI, Christensen A, Johansen O. Surgical release of the internal obturator tendon for the treatment of retro-trochanteric pain syndrome: a prospective randomized study, with long-term follow-up. *Knee Surg Sport Traumatol Arthroscopy.* 2009;17:1249-56.
- Labropoulos N, Tassiopoulos AK, Gasparis AP, Phillips B, Pappas PJ. Veins along the course of the sciatic nerve. *J Vasc Surg.* 2009;49(3):690-6.
- Papadopoulos SM, McGillicuddy JE, Albers JW. Unusual cause of 'piriformis muscle syndrome'. *Arch Neurol.* 1990;47(10):1144-6.
- Beauchesne RP, Schutzer SF. Myositis ossificans of the piriformis muscle: an unusual cause of piriformis syndrome. *J Bone Joint Surg Am.* 1997;79:906-10.
- Beaton LE, Anson BJ. The relation of the sciatic nerve and its subdivisions to the piriformis muscle. *Anat Record.* 1937;70:1-5
- Pecina M. Contribution to the etiological explanation of the piriformis syndrome. *Acta Anat (Basel).* 1979;105(2):181-7.
- Martin HD, Kivlan BR, Palmer IJ, Martin RL. Diagnostic accuracy of clinical tests for sciatic nerve entrapment in the gluteal region. *Knee Surg Sports Traumatol Arthroscopy.* 2014;22(4):882-8.
- Knudsen JS, Mei-Dan O, Brick MJ. Piriformis Syndrome and Endoscopic Sciatic Neurolysis. *Sports Med Arthroscopy Rev.* 2016;24(1):e1-7.
- Rivera J, Singh V, Fellows B. Reliability of psychological evaluation in chronic pain in an interventional pain management setting. *Pain Phys.* 2005;8:375-83.