



## Endoscopic Endonasal Transsphenoidal and Transplanum Removal of Chordoid Glioma of the Third Ventricle

Jonathan Raskin<sup>1</sup>, Arthur W Wu<sup>2</sup>, Michela Borrelli<sup>2</sup> and Adam N Mamelak<sup>3\*</sup>

<sup>1</sup>Oakland University William Beaumont School of Medicine, USA

<sup>2</sup>Division of Otolaryngology, Cedars-Sinai Medical Center, USA

<sup>3</sup>Department of Neurosurgery, Cedars-Sinai Medical Center, USA

### Abstract

Chordoid glioma is a rare low-grade tumor that arises from the anterior wall or roof of the third ventricle superior to the optic chiasm. Histologically it is suspected to originate from the specialized ependymal cells of the lamina terminalis. This tumor arises from areas adjacent to the hypothalamus and suprasellar region with the usual presentation of an ovoid shape on imaging and histology similar to a chordoma. While descriptions of these tumors in the surgical literature exist, all surgical series report on outcomes following craniotomy and direct transcranial approaches. We now report a case of an individual who underwent endoscopic transsphenoidal and transplanum resection, focusing on surgical details that are unique to this approach.

**Keywords:** Endoscopic skull base surgery; Third ventricle; Glioma

### Case Presentation

A 27-year-old female with a history of type II diabetes and obesity presented to the hospital with headaches. She was found to have a SARS-CoV-2 infection and was admitted to the hospital for observation and respiratory support. Due to her symptoms, a non-contrast head CT was performed, which demonstrated a large suprasellar mass with edema of the surrounding hypothalamus and optic tracts (Figure 1). A subsequent MRI (Figure 2) was performed and the differential diagnosis included craniopharyngioma, pituitaryoma, or other glial tumors. Pre-operative hormonal testing demonstrated normal pituitary axis hormones and visual fields that were grossly normal. The patient recovered from her COVID-19 symptoms, and once she tested negative, the patient underwent an electively planned endoscopic transsphenoidal and transplanum resection of the mass. At the initial surgery, the tumor was found to arise above the pituitary stalk, compressing the stalk and gland anteriorly and inferiorly against the optic nerves. Due to the narrow corridor in the area and in an effort to preserve the stalk, a surgical approach superior to the optic nerves and below the anterior cerebral arteries was taken. The tumor was noted to be gelatinous with a well-circumscribed capsule and relatively minimal vascularity. These features permitted relatively easy resection of the majority of the tumor. A frozen section sent during surgery was determined to be most consistent with pilocytic astrocytoma. The majority of the mass was resected during the initial resection, but gross total resection was not attempted due to concern of potential direct tumor invasion of the optic nerves, optic tracts, or hypothalamus. Post-operatively the patient reported new bitemporal hemianopsia, which was attributed to surgical irritation of the optic chiasm, but this steadily improved over the next several days. Additionally, the patient developed diabetes insipidus which was treated with Desmopressin Acetate (DDAVP) and fluid management, and was maintained on corticosteroid replacement. The final pathology report indicated chordoid glioma. Due to the tumor's resistance to radiation, proclivity to recur without gross total resection, and the patient's young age, the decision was made to perform a second surgery to attempt to clear the tumor remnants in the third ventricle. Five days after the initial surgery, a second surgery was performed in which the tumor was found to be devascularized and soft. A gross total removal was obtained, confirmed both intraoperatively and with post-operative MRI (Figure 3). A multilayered repair with a nasoseptal flap was performed and a lumbar drain was used to divert the CSF for several days. On post-operative day 7, the patient developed hyponatremia attributed to Syndrome of Inappropriate Antidiuretic Hormone (SIADH) with a good response to 3% normal saline, followed by a return of Diabetes Insipidus, requiring DDAVP. The patient was discharged on post-operative day 23 with partially diminished acuity in her left eye and a mild bitemporal hemiopia, with no further complications and with no signs of

### OPEN ACCESS

#### \*Correspondence:

Adam N Mamelak, Department of Neurosurgery, Cedars-Sinai Medical Center, 127 S San Vicente Blvd, #A6600, Los Angeles, CA 90048, USA, E-mail: Adam.Mamelak@cshs.org

**Received Date:** 06 Jan 2021

**Accepted Date:** 03 Feb 2021

**Published Date:** 11 Feb 2021

#### Citation:

Raskin J, Wu AW, Borrelli M, Mamelak AN. Endoscopic Endonasal Transsphenoidal and Transplanum Removal of Chordoid Glioma of the Third Ventricle. *Clin Surg.* 2021; 6: 3060.

**Copyright** © 2021 Adam N Mamelak. This is an open access article distributed under the Creative Commons Attribution License, which permits unrestricted use, distribution, and reproduction in any medium, provided the original work is properly cited.

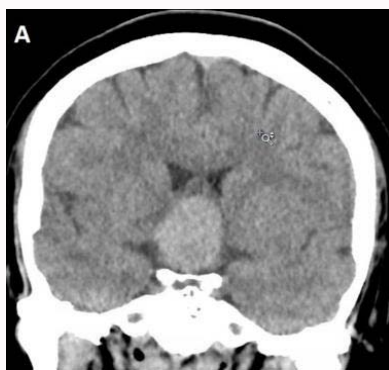


Figure 1: Initial CT: Sella and suprasellar structures.

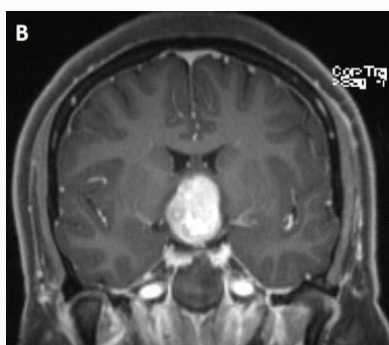


Figure 2: Initial MRI: Sella and suprasellar structures.

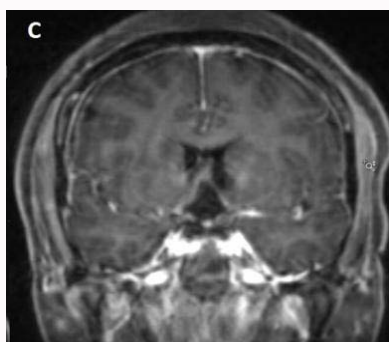


Figure 3: Post-operative MRI: Postoperative tumor assessment after transsphenoidal suprasellar tumor resection.

recurrence to date.

## Discussion

Chordoid glioma of the third ventricle is a rare tumor that is best managed by complete surgical resection due to its proclivity for recurrence and its poor response to radiotherapy [1]. Chordoid gliomas commonly present with vimentin and Glial Fibrillary Acidic Protein (GFAP) that are expressed in cells of the CNS [2,3]. This tumor commonly affects individuals between the ages of 30 and 60, affecting twice as many women as men, and has been designated as a WHO grade II glial neoplasm with a high rate of recurrence and death following subtotal tumor resection [3,4]. According to Ampie et al. [5] subtotal tumor resection resulted in tumor recurrence in 5 out of 34 cases, with the survival rate decreasing with one, three, and five-year follow-ups at 85.2%, 71%, and 35.5% respectively. In contrast, the literature shows that gross total resection provides

the best outcome for tumor control and treatment effectiveness, though the surgical approach determines the rate of postoperative complications, which we show to be minimized with the endonasal transsphenoidal approach [5]. The most common surgical methods reported in the literature to remove a chordoid glioma include a craniotomy via a midline subfrontal; translamina terminalis approach [6]. This method provides early identification of the optic chiasm and access to the superior sections of the tumor [6]. Tumors that contain a large intraventricular section can also be removed through a transcortical or transventricular approach, while lateralized chordoid gliomas have been removed through pterional craniotomy. DeSouza et al. [6] writes that the transsphenoidal approach has been only used in one prior case and theorizes that the approach would be unlikely to offer appropriate access for most tumors, especially given the propensity for chordoid glioma not to cause sellar expansion. In contrast, we found that using the transsphenoidal approaches resulted in the best outcome for the complete tumor resection, with minimal neurological damage in the suprasellar region. Much like many tumors of the suprasellar space extending into the third ventricle, the expanded transsphenoidal approach allowed direct visualization of the midline structures, and rapid identification of the pituitary stalk, optic nerves, and related structures. In this particular case, the transplanum approach also permitted direct access to the inferior portion of the third ventricle without needing to retract any brain tissue. According to Jeswani et al. [7] the endonasal transsphenoidal approach provides for the most direct access and extensive operative area into the infrachiasmatic, olfactory, sub frontal, prepontine, and perimesencephalic regions with minimal brain retraction and neurovasculature movement due to the straight visualization of the skull base, thus decreasing the rate of neurological damage. Additionally, in regard to other tumor types, both the endoscopic transsphenoidal and open transcranial approaches show the same tumor recurrence rate, but the transcranial approach shows considerably more neurological damage at a rate of 41.2%, compared to the endonasal transsphenoidal approach at 15.8%. Furthermore, with the addition of transclival corridors and related modifications, such as removal of the posterior clinoid, dorsum sella, and pituitary transposition, the expanded transsphenoidal approaches provide ideal surgical access to the majority of midline tumors in the parasellar, suprasellar, and third ventricular spaces. There has only been one other reported case of an endoscopic transnasal approach to the resection of the chordoid glioma of the 3<sup>rd</sup> ventricle, which described the complete removal of the tumor. Zeinalizadeh et al. [8] described this technique as the ideal approach to visualize the hypothalamus and undersurface of the optic chiasm. Additionally, the opportunity for a four-handed technique with an assistant can aid in the total resection of the chordoid glioma. We suspect that neurosurgeons who perform a relatively high volume of transsphenoidal skull base surgery would also likely favor this approach, and the lack of cases in the literature is a reflection of the rarity of this tumor rather than drawbacks of this surgical method. The main difference between this operation and our routine expanded endoscopic transsphenoidal surgeries is that we operated *via* a window superior to the optic nerves. This allowed early identification and protection of the optic nerves. Temporary injury did likely occur, but all maneuvers were accomplished with the nerves under direct vision at all times. The disadvantage of this approach was the relatively small working window. In a literature review of chordoid gliomas by DeSouza et al. [6], tumor progression was reported in 5 out of 22 cases with subtotal resection, while 12 patients with subtotal resection had no progression. Moreover, there was no recurrence

in 15 out of 16 patients who had a total resection. Postoperative complications were common, with only 7 out of 39 patients reporting no complications. The most frequent complications included short term memory deficits due to possible fornical damage, and diabetes insipidus. There were 15 postoperative deaths, with five caused by pulmonary embolisms and four caused by infection. Two-thirds of these deaths occurred within the first 4 postoperative weeks. No deaths or similar life-threatening complications were reported in the two transsphenoidal procedures, including our procedure. Radiotherapy for the chordoid glioma tumor has been evaluated in several studies. Iwama et al. [9] compared adjuvant gamma knife therapy to routine external beam radiotherapy. They found that three of their patients who received adjuvant gamma knife therapy had no recurrence, while three other patients that received adjuvant external beam therapy had a recurrence. However, it is likely that patient treatment volumes with radiosurgery alone were significantly smaller, which could be a factor affecting the recurrence rates. In addition, DeSouza et al. [6] found that 3 out of 9 patients who received adjuvant radiotherapy saw a progression in the tumor. All patients who had an incomplete resection of the tumor received conventional radiotherapy. One of these patients received both conventional radiotherapy and gamma knife radiosurgery and had no subsequent recurrence. An additional three patients who had a subtotal resection received gamma knife therapy, showing no subsequent recurrence of the tumor. Two patients received radioactive implants, one showed no recurrence, while the other died from unknown causes. While it is difficult to make broad conclusions on the effectiveness of radiotherapy given the rarity of these tumors, it appears that traditional external beam radiotherapy may be less effective, and, if dealing with either subtotal or incomplete resection, then gamma knife radiotherapy is preferable. Gross total resection remains the prohibitive goal of any surgery, but the sensitive structures in this region make overly aggressive maneuvers potentially life-threatening as demonstrated in the largest review. Komotar et al. [10] states that the endoscopic transsphenoidal approach provides for the greatest opportunity of gross total resections of certain craniopharyngiomas at a rate of 66.9%, compared to the open transcranial resection based techniques that were only successful in 48.3% of gross total resection. Our collective experience can be applied to the rare instances of chordoid glioma, and the endoscopic endonasal transsphenoidal approach offers the most direct route to the 3<sup>rd</sup> ventricle with early identification and protection of the optic nerves.

## References

1. Buccoliero AM, Caldarella A, Gallina P, Di Lorenzo N, Taddei A, Taddei GL. Chordoid glioma: Clinicopathologic profile and differential diagnosis of an uncommon tumor. *Arch Pathol Lab Med.* 2004;128(11):e141-5.
2. Hanbali F, Fuller GN, Leeds NE, Sawaya R. Chordoid plexus cyst and chordoid glioma. Report of two cases. *Neurosurg Focus.* 2001;10(6):E5.
3. Pasquier B, Péoc'h M, Morrison AL, Emmanuel G, Dominique P, Sylvie G, et al. Chordoid glioma of the third ventricle: A report of two new cases, with further evidence supporting an ependymal differentiation, and review of the literature. *Am J Surg Pathol.* 2002;26(10):1330-42.
4. Morais BA, Menendez DFS, Medeiros RSS, Teixeira MJ, Lepski GA. Chordoid glioma: Case report and review of the literature. *Int J Surg Case Rep.* 2015;7C:168-71.
5. Ampie L, Choy W, Lamano JB, Kartik K, Qinwen M, Andrew TP, et al. Prognostic factors for recurrence and complications in the surgical management of primary chordoid gliomas: A systematic review of literature. *Clin Neurol Neurosurg.* 2015;138:129-36.
6. DeSouza R-M, Bodi I, Thomas N, Marsh H, Crocker M. Chordoid glioma: Ten years of a low-grade tumor with high morbidity. *Skull Base.* 2010;20(2):125-38.
7. Jeswani S, Nuño M, Wu A, Vivien B, John DC, Keith LB, et al. Comparative analysis of outcomes following craniotomy and expanded endoscopic endonasal transsphenoidal resection of craniopharyngioma and related tumors: A single-institution study. *J Neurosurg.* 2016;124(3):627-38.
8. Zeinalizadeh M, Sadrehosseini SM, Tayebi Meybodi K, Sharifabadi AH. Expanded Endoscopic Transnasal Approach to the Chordoid Glioma of the Third Ventricle : The First Case Ever Reported. *J Korean Neurosurg Soc.* 2016;59(6):643-6.
9. Iwami K, Arima T, Oooka F, Fukumoto M, Takagi T, Takayasu M. Chordoid glioma with calcification and neurofilament expression: Case report and review of the literature. *Surg Neurol.* 2009;71(1):115-20.
10. Komotar RJ, Starke RM, Raper DMS, Anand VK, Schwartz TH. Endoscopic endonasal compared with microscopic transsphenoidal and open transcranial resection of craniopharyngiomas. *World Neurosurg.* 2012;77(2):329-41.