



Distal Left Main Bronchial Injury after Catheter Ablation for Atrial Fibrillation: Report of Two Cases

Aaron Sparks, Jonathan Kozinn, Alan Wimmer and James R Stewart*

Departments of Surgery, University of Missouri-Kansas City School of Medicine, USA

Mini Abstract

We report two cases of distal left main bronchial injury following catheter based ablation for atrial fibrillation, and discuss each patient's management.

Abstract

We report two patients who developed respiratory complications after catheter ablation for atrial fibrillation seen recently at our institution. The first patient presented with worsening dyspnea. Outpatient bronchoscopy was performed and demonstrated a pin-point opening in the distal left main bronchus 6 months after RF and previous cryothermal ablation. The patient was managed with rigid bronchoscopy, left main bronchial dilatation and silicone stent placement. The second patient presented within 24 h of the procedure at an outside institution with severe prolonged episodes of cough and dyspnea, and acute respiratory failure. He had pneumopericardium in addition to his respiratory symptoms. Fiber optic bronchoscopy was performed and the pericardium was drained surgically. He was found to have a full thickness thermal injury with loss of bronchial integrity immediately before the left main bifurcation, along the anterior surface of the bronchus. He was supported with ventilation, serial bronchoscopic evaluations, hemodynamic and antibiotic support, and eventual tracheostomy. Both patients are improved after treatment. We believe these are the first two reported cases of this complication following radiofrequency catheter ablation. Since its introduction in the 1990's, the indications for catheter ablation of the left atrium for atrial fibrillation have expanded. Certain potential major and minor complications have been recognized. Major complications include periprocedural death (0.15%), esophageal injury with leak, aorto-esophageal fistula (0.04%), cerebral thromboembolic events, TIA and stroke, (0.94%), cardiac perforation with hemorrhage and tamponade (1.31%), pulmonary venous stenosis (0.29%), phrenic nerve injury (0.48%), and arrhythmias. Minor complications have included femoral false aneurysms or thrombosis (0.93%) and arteriovenous fistulas (0.54%). We present two patients with injury to the distal left main bronchus as a consequence of RF and cryoballoon ablation. The first patient presented 6 months after the RFA. He developed progressive dyspnea with minimal exertion. The second patient presented within 24 h of the RFA with severe coughing paroxysms, dyspnea, and respiratory failure. We describe the management of these patients.

Keywords: Atrial fibrillation; Bronchial injury and stenosis; Bronchial stent; Catheter ablation

Case Presentation

Case 1

The patient is a 67-year old man who had symptomatic paroxysmal atrial fibrillation. He failed pharmacologic therapy and cardioversion. He underwent failed left atrial cryoablation with return of atrial fibrillation in 6 weeks. He subsequently underwent a successful RF ablation with resolution of his atrial fibrillation. Six months later, the patient had developed progressive, severe dyspnea. He was admitted to hospital and underwent bronchoscopy demonstrating a small opening in the distal left main bronchus. The patient underwent rigid bronchoscopy, dilatation of the distal left main bronchus and placement of an 8 mm × 13 mm Hood silicone stent. He noted immediate improvement in his symptoms. Approximately 3 weeks later during a coughing episode the stent became dislodged and was expectorated. He underwent CT chest with 3D reconstruction which documented an area of stenosis (Figure 1). He had repeat rigid bronchoscopy and dilatation, with placement of a 10 mm × 13 mm Hood stent. He was discharged home with mild residual dyspnea. Twelve months after initial bronchoscopy the stent was removed and his symptoms are minimal.

OPEN ACCESS

*Correspondence:

James R Stewart, Departments of Surgery, University of Missouri Kansas City School of Medicine, 2301 Holmes Road, Kansas City, MO 64108, USA,

Tel: 816-516-8287;

E-mail: jrs1040@aol.com

Received Date: 20 Aug 2016

Accepted Date: 17 Oct 2017

Published Date: 20 Oct 2017

Citation:

Sparks A, Kozinn J, Wimmer A, Stewart JR. Distal Left Main Bronchial Injury after Catheter Ablation for Atrial Fibrillation: Report of Two Cases. *Clin Surg.* 2017; 2: 1683.

Copyright © 2017 James R Stewart. This is an open access article distributed under the Creative Commons Attribution License, which permits unrestricted use, distribution, and reproduction in any medium, provided the original work is properly cited.

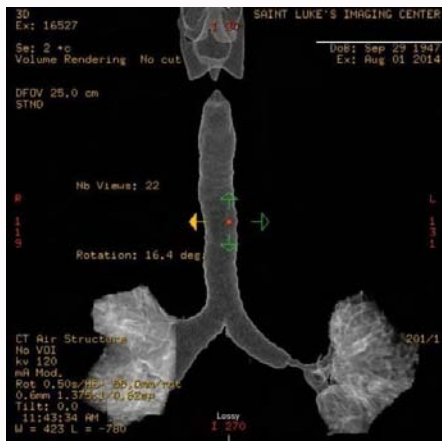


Figure 1: Left main bronchial stenosis after initial dilatation and stent dislodgment. Three dimensional reconstruction of tracheal CT, Case 1.

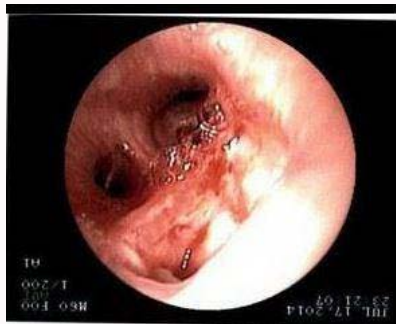

Figure 2A: Bronchoscopy at diagnosis, Case 2.

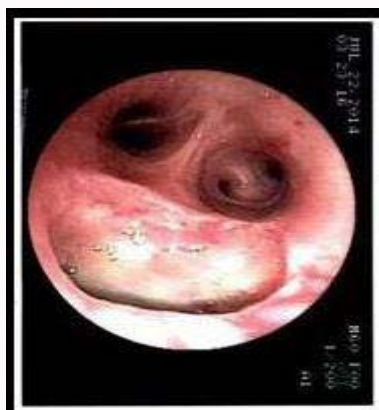


Figure 2B: Bronchoscopy after 11 days, Case 2.

Case 2

The patient is a 34-year-old man with symptomatic paroxysmal atrial fibrillation. He underwent RFA at an outside hospital without apparent complication. The patient was discharged home. The patient returned in 24 h with severe coughing episodes, hypoxemia and dyspnea. Chest radiograph demonstrated pneumopericardium. He was intubated for respiratory failure and transferred to our institution. He was found to be hypotensive and hypoxemic on presentation. The patient was stabilized and taken to the operating room. He underwent bronchoscopy and subxiphoid pericardial drainage with placement of a 24 Fr. Jackson-Pratt drain. At initial presentation, there appeared to be dark, slough on the inferior wall of the distal

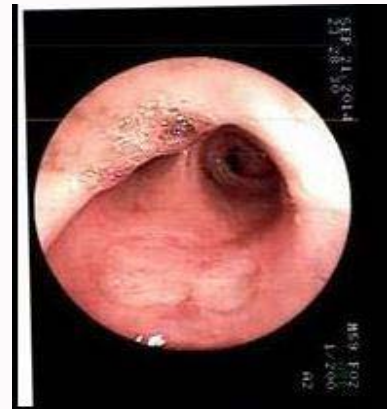

Figure 2C: Bronchoscopy at 60 days, Case 2.

left main bronchus. The patient was treated for respiratory failure and sepsis. He received serial bronchoscopic examinations (Figure 2A-C). On subsequent examination, it was revealed the patient had suffered a bronchial to pericardial fistula secondary to the ablation. The integrity of the left atrium remained intact and with continued support the injury showed signs of healing. The patient improved and stent placement was deferred. A tracheostomy was placed and the patient successfully weaned from ventilator support. He was discharged to a rehabilitation facility. He returned 6 weeks later for repeat bronchoscopy. Bronchoscopy showed nearly complete healing of the injury with no evidence of stenosis and the tracheostomy was removed.

Discussion

The two patients in this report suffered a spectrum of thermal injury to the distal left main bronchus as a consequence of catheter ablation for atrial fibrillation. The first patient had late bronchial stenosis. It was demonstrated on CT scan with 3D reconstruction after stent dislodgment. The imaging occurred before repeat bronchoscopic dilatation and stent replacement. The patient was evaluated for possible left upper pulmonary venous stenosis, by Computed Tomographic Arteriogram (CTA), and found to have narrowing of the left superior pulmonary vein. The second patient was critically ill with a communication between his bronchus and pericardium. The patient had respiratory failure and sepsis likely secondary to aspiration pneumonia. It is fortunate the patient did not have hemorrhage due to communication between the pulmonary vein, the bronchus and pericardium. This patient was screened for pulmonary venous and bronchial stenosis as a consequence of RFA, and has thus far demonstrated no significant narrowing after 9 months. The above complication has been reported after cryoballoon ablation. A recent study suggests that ice formation in the left main stem bronchus during cryoablation is common [1-6]. We are unaware of prior reports of this complication following RF ablation. It is important to keep in mind the proximity of the left atrium and pulmonary veins to important anatomic structures including the esophagus, aorta, distal left main and left upper lobe bronchi, the right pulmonary artery and phrenic nerves. Using caution and greater focus on the surrounding anatomy, it is hoped that these complications can be avoided. If endoscopic therapy had not been helpful in the first patient, an open bronchoplastic procedure may have been necessary. Computer guided ablation systems and esophageal temperature monitoring may help prevent complications. Pre procedural imaging with CT or MRI may provide information to

direct catheter placement in at risk patients.

References

1. Sorgente A, Chierchia GB, de Asmundis C, Sarkozy A, Capulzini L, Brugada P. Complications of atrial fibrillation ablation. When prevention is better than cure. *Europace*. 2011;13(11):1526-32.
2. Van Opstal JM, Timmermans C, Blaauw Y, Pison L. Bronchial erosion and hemoptysis after pulmonary vein isolation by cryoballoon ablation. *Heart Rhythm*. 2011;8:1459.
3. Marti-Almor J, Jauregui-Abularach ME, Benito B, Ermengol Vallès, Victor Bazan, Albert Sánchez-Font, et al. Pulmonary Hemorrhage After Cryoballoon Ablation for Pulmonary Vein Isolation in the Treatment of Atrial Fibrillation. *Chest*. 2014;145(1):156-7.
4. Desai AK, Osahan DS, Undavia MB, Nair GB. Bronchial injury post-cryoablation for atrial fibrillation. *Ann Am Thorac Soc*. 2015;12(7):1103-04.
5. Cuoco F, Sturdivant JL, Wharton JM, Gold MR. Delayed formation of an atrial bronchial fistula following cryoballoon ablation for atrial fibrillation. *Heart Rhythm*. 2016;(1);13 (5):S156.
6. Verma N, Gillespie CT, Argento C, Todd Tomson, Sanjay Dandamudi, Paloma Piña, et al. Bronchial effects of cryoballoon ablation for atrial fibrillation. *Heart Rhythm*. 2017;14:12-6.