



## Difficult Diagnosis and Rare Morphology of Lymphangioliomyomatosis with Giant Cysts

Welter S<sup>1\*</sup>, Thrull P<sup>1</sup>, Westhoff M<sup>1</sup>, Bach P<sup>1</sup>, Popper H<sup>2</sup> and Maschek H<sup>3</sup>

<sup>1</sup>Lung Clinic Hemer, Center for Pneumology and Thoracic Surgery, Germany

<sup>2</sup>Institute of Pathology, Medical University of Graz, Austria

<sup>3</sup>Synlab, Pathology Laboratory, Germany

### Introduction

Diffuse cystic lung disease has many differential diagnoses which can be challenging to establish in some cases. Especially non-characteristic clinical presentation, unusual computed scan morphology and rare histologic findings needs the collaboration of different specialists to identify the underlying disease.

### Case Blog

We report on a 32-year-old woman without relevant pulmonary symptoms in the past. She was transferred into our hospital with a second manifestation of a tension pneumothorax two weeks after external drainage therapy (Figure 1). After immediate chest tube insertion the Computed Tomogram (CT) of the chest revealed multiple bilateral pulmonary cysts with thin walls (Figure 2). The CT examination showed large cystic lesions with small walls with a maximum diameter up to 10 cm distributed all over both lungs. No fluid collections or nodules were present. Between those lesions normal lung parenchyma was present. The patient is a never-smoker and Alpha-1- antitrypsin was within normal ranges. A minimally invasive wedge resection from the right upper lobe followed by a spared talcum poudrage was performed. The postoperative course was prolonged by air leak but finally resolved after one week. Elaborate histologic evaluation showed lung tissue with large cystic spaces partially with smooth muscle structures in the walls including interlobular septa (Figure 3 and 4). Furthermore some walls were covered by a CD31 and sporadic D2-40 positive layer of endothelial cells. CD34 was negative, but rare HMB-45 positive Perivascular Epithelioid Cells (PEC) were found by a reference pathologist. Parts of the cystic walls were fibrosed, and some cysts seem to have lymphatic origin. The final pathologic consensus diagnosis was a lymphangioliomyomatosis. Differential diagnoses like langerhans cell histiocytosis, and Birt Hogg Dube syndrome were excluded by histology and radio morphology. Congenital pulmonary adenomatoid malformation did not match with the case concerning distribution of the cysts. The patient was informed about the diagnosis and moved back into her home country.

### Discussion

The differential diagnoses of diffuse cystic lung diseases include congenital malformations, neoplastic, inflammatory, infectious diseases and emphysema changes from smoking [1]. Large cysts in non-smoking adults are suspicious for Congenital Pulmonary Adenomatoid Malformations

### OPEN ACCESS

#### \*Correspondence:

Welter S, Department of Pneumology and Thoracic Surgery, Lung Clinic Hemer, Center for Pneumology and Thoracic Surgery, Germany, E-mail: Stefan.Welter@lkhemer.de

Received Date: 21 Aug 2018

Accepted Date: 25 Sep 2018

Published Date: 01 Oct 2018

#### Citation:

Welter S, Thrull P, Westhoff M, Bach P, Popper H, Maschek H. Difficult Diagnosis and Rare Morphology of Lymphangioliomyomatosis with Giant Cysts. Clin Surg. 2018; 3: 2128.

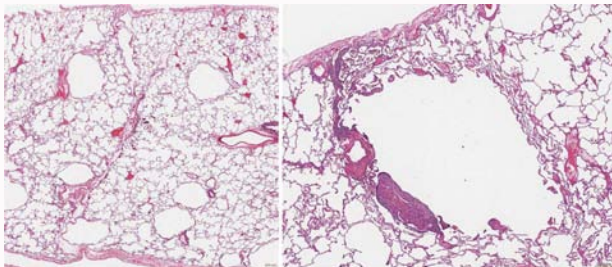
Copyright © 2018 Welter S. This is an open access article distributed under the Creative Commons Attribution License, which permits unrestricted use, distribution, and reproduction in any medium, provided the original work is properly cited.

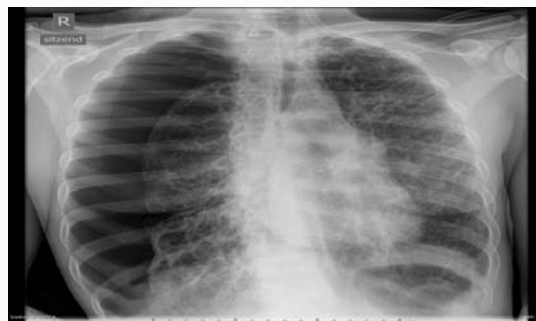
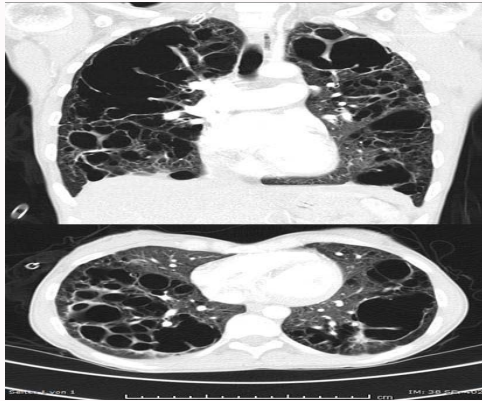
Figure 1: Chest X-ray at the day of admission with a tension pneumothorax on the right side. Emphysematous changes, cysts and fibrous strands are homogeneously distributed over both lungs.



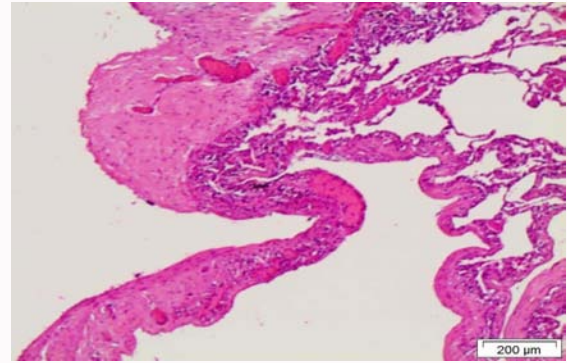
**Figure 2:** Chest CT-scan after insertion of a chest tube demonstrating large bilateral central cysts with thin walls surrounded by unchanged and slightly emphysematous lung tissue.



**Figure 3:** H&E stained section. Left, overview of cystic lesions. Bar 400  $\mu$ m. Right, cystic lesion with pronounced muscular proliferation. Bar 200  $\mu$ m.

(CPAM). The latter ones are usually thin walled multiple cystic masses unilateral in one lobe and the cysts are lined by epithelial cells often able to produce mucus [2,3]. This definition of CPAM does not fit with our case. Because in this case the morphology was unusual for any type of Congenital Cystic Pulmonary Malformation (CPAM) and immunohistochemistry demonstrated a lymphatic origin of the cysts stained by CD31 and D2-40, the preliminary pathologic diagnosis was lymphangiomas. Lymphangiomas usually comes along with collections of chylus, chylothorax or dilated fluid filled lymph vessels [4]. Diffuse pulmonary lymphangiomas is characterized by abnormally dilated or reduplicated lymphatic spaces in the lung and extra thoracic organs [4]. Other authors described lymphangiomas is a rare disease characterized by diffuse infiltration of lymphangiomas in the lung, bone, kidney and other organs [5]. Again, none of these conditions were found in this patient.

Lymphangioleiomyomatosis is characterized as a low-grade, destructive, metastasizing neoplasm, and manifests as the proliferation of abnormal smooth muscle-like cells in the lung stroma. The gold-standard immuno-histochemical diagnostic for LAM is immune positive reaction with HMB-45 antibody. Besides HMB-45, the most commonly used markers in the immuno-histochemical diagnosis of LAM are  $\alpha$ -Smooth Muscle Actin ( $\alpha$ SMA), Estrogen Receptor (ER), and Progesterone Receptor (PR) [6,7].



**Figure 4:** H&E stained section demonstrating large cysts and interstitial fibrosis. Bar 200  $\mu$ m.

## Conclusion

This case illustrates that immunohistochemistry for HMB-45 may be negative, although LAM is present. If clinical suspicion for LAM is high, repeated HMB-45-immunohistochemistry of additional histological sections should be forwarded, because sometimes there may be only scarce HMB-45 positivity. The establishment of a definite LAM-diagnosis has relevant therapeutic implications, especially regarding mTOR-inhibitor-therapy.

## References

- Baldi BG, Carvalho CRR, Dias OM, Marchiori E, Hochhegger B. Diffuse cystic lung diseases: differential diagnosis. *J Bras Pneumol.* 2017;43(2):140-9.
- Stocker JT, Madewell JE, Drake RM. Congenital cystic adenomatoid malformation of the lung. Classification and morphologic spectrum. *Hum Pathol.* 1977;8(2):55-71.
- Kim WS, Lee KS, Kim IO, Suh YL, Im JG, Yeon KM, et al. Congenital cystic adenomatoid malformation of the lung: CT-pathologic correlation. *AJR Am J Roentgenol.* 1997;168(1):47-53.
- Zhao J, Wu R, Gu Y. Pathology analysis of a rare case of diffuse pulmonary lymphangiomas. *Ann Transl Med.* 2016;4(6):114.
- Zhang J, Jin H, Wang Y, Bai C, Han Y. A case of diffuse pulmonary lymphangiomas with unilateral lung invasion. *Oxf Med Case Reports.* 2015;10:346-8.
- Grzegorek I, Lenze D, Chabowski M, Janczak D, Szolkowska M, Langfort R, et al. Immunohistochemical evaluation of pulmonary lymphangioleiomyomatosis. *Anticancer Res.* 2015;35(6):3353-60.
- Johnson SR, Cordier JF, Lazor R, Cottin V, Costabel U, Harari S, et al. European Respiratory Society guidelines for the diagnosis and management of lymphangioleiomyomatosis. *Eur Respir J.* 2010;35(1):14-26.