



Different Synthetic Materials for Brow Suspension of Lid Ptosis

Khaled G Abueleinen*

Department of Ophthalmology, Cairo University, Egypt

Abstract

Purpose: To assess silicone lacrimal tubes for frontalis sling in ptosis repair.

Methods: Single-center, nonrandomized, prospective, interventional case series. Twenty-eight ptotic lids in 18 patients with poor or absent elevator function were scheduled for brow suspension. Silicone lacrimal tubes were used for brow suspension. They were applied in form of Fox pentagon. Main outcome measures were success, infection/granuloma, lagophthalmos and exposure keratitis.

Results: Silicone lacrimal tubes achieved 80% primary success in ptosis repair with good lid closure without lagophthalmos, exposure keratitis, extrusion, infection or granuloma.

Conclusion: Silicone lacrimal tube is a safe synthetic material for brow suspension. Success was comparable to alternative materials.

Keywords: Silicone tubes; Lids; Ptosis; Frontalis sling

Introduction

Frontalis sling or brow suspension is the procedure of choice for surgical management of severe blepharoptosis associated with poor elevator function. Materials used for frontalis sling are either autogenous fascia lata or exogenous synthetic materials. Fascia lata requires thigh dissection and consumes more time and effort during surgery. Also, fascia lata is poorly developed in young children and there are problems associated with its harvest [1-6]. Hence synthetic materials were adopted by most oculoplastic surgeons for ease of application and time sparing. Different materials have been used for eyelid sling; the most popular exogenous ones are silicone rod [7-11], mersilene mesh [12-18], Gore-Tex [19-22,23], monofilament and polyfilament nylon [6,21,23-25] and monofilament polypropylene (Prolene) [21,26]. In the best of our knowledge no previous literature described the use of silicone lacrimal tube as frontalis sling. This study tries to assess silicone lacrimal tubes for frontalis sling regarding success, infection/granuloma, extrusion, lagophthalmos and exposure keratitis.

Subjects and Methods

This study was retrospective, case series. This study included cases operated by the author in the period from June 2003 to January 2009 in Cairo University "Kasr El Aini" Hospital. An informed consent based on the guidelines of the Helsinki protocol was taken from all patients. The ethics committee of the hospital approved the study. The author has no financial/conflicting interests to disclose.

A total of 28 lids were operated, 10 cases had bilateral procedures and 8 unilateral procedures. Cases with unilateral ptosis were operated only on the ptotic lid. The age of the patients ranged from 6 months to 48 years, mean age + SD was 14.4 + 14.5 years. The causes behind ptosis were congenital simple ptosis in 18 lids, traumatic ptosis in 6 lids, blepharophimosis syndrome in 2 lids, and chronic progressive external ophthalmoplegia (CPEO) in 2 lids. Five operations were done for recurrent ptosis. Severity of ptosis and the associated problems of compensatory head posture and occlusion of the visual axis dictated the timing of the surgery in children below the age of 5 years. Cosmetic appearance was the indication of operation above this age. Silicone lacrimal tubes (Length: 300 mm, Diameter: 0.6 mm) were used. The surgical technique was Fox's brow suspension. Three incisions were made at the upper edge of the brow in skin and subcutaneous tissues to reach the frontal periosteum using a #15 scalpel. The medial incision was made on the outer side of an imaginary line perpendicular to the medial canthus and the lateral incision was made on an imaginary line perpendicular to the lateral canthus. After placing a lidplate for protection of the

OPEN ACCESS

*Correspondence:

Khaled G Abueleinen, Department of ophthalmology, Cairo University, 29 Ahmad Orabi street, Agooza, Giza, Cairo, Egypt, Tel:201222385573; E-mail: khaledabueleinen@yahoo.com

Received Date: 21 Jun 2018

Accepted Date: 16 Jul 2018

Published Date: 19 Jul 2018

Citation:

Abueleinen KG. Different Synthetic Materials for Brow Suspension of Lid Ptosis. Clin Surg. 2018; 3: 2048

Copyright © 2018 Khaled G Abueleinen. This is an open access article distributed under the Creative Commons Attribution License, which permits unrestricted use, distribution, and reproduction in any medium, provided the original work is properly cited.

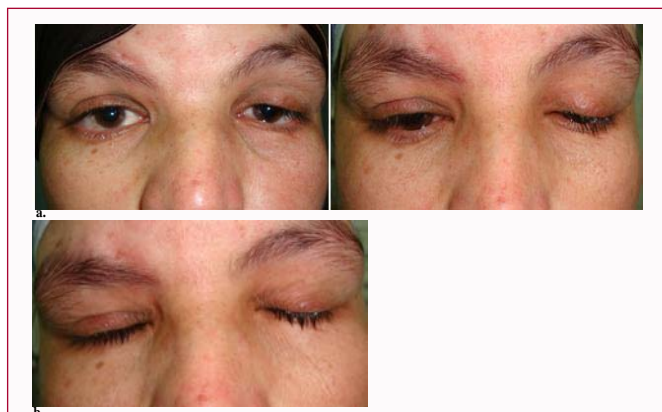

Figure 1: a) Silicone tubes. Left: Repaired right ptosis in primary gaze, notice reformation of crease as compared to the ptotic left eye. Right: 3 days after left frontalis sling using silicone lacrimal tube notice reformation of crease. **b)** Silicone tubes. Left: Lid closure without lagophthalmos. Right: Minimal lid lag without scleral show in down gaze.

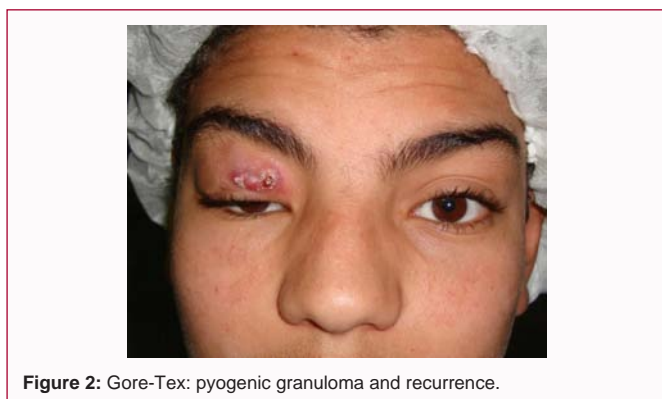

Figure 2: Gore-Tex: pyogenic granuloma and recurrence.

globe, two incisions were made on the upper lid 2 mm above the lid margin reaching the tarsus; the two incisions were centered on the upper lid and separate by about 1 cm. Stringing was performed using Wright's needle or the metal probe attached to the silicone tube as shown in Figure 1. The two ends of the silicone lacrimal tube were tied together in one throw through the central incision above the brow. After adjustment of eyelid height at the limbus, the silicone tube knot was tied with 5-0 Prolene and buried deep in the frontalis muscle and finally the skin was repaired with 6-0 Prolene or vicryl. Lower lid traction suture was taped to the brow and was removed at the first dressing on the second postoperative day. Skin sutures were removed at 1 week. Absorbable sutures were left in uncooperative children. Complications were recorded. These included recurrence, infection, granuloma formation, extrusion, lagophthalmos and exposure keratitis.

Results

Twenty-eight lids were operated; one case with unilateral procedures and one with bilateral procedures dropped from follow up. Follow up period ranged from 11 to 49 months Mean follow up period + SD was 23.4 + 11 months. Silicone lacrimal tubes achieved primary success in 20/25 lids (80%) with perfect lid closure, without lagophthalmos and minimal lid lag in down gaze (Figure 2 and 3). Recurrence was reported in 5 lids, 3 lids with congenital simple ptosis, one lid with traumatic ptosis and one with CPEO. Silicone tubes were readjusted in recurrent cases. The central brow incision was reopened; the silicone tube knot was exposed, pulled out of the

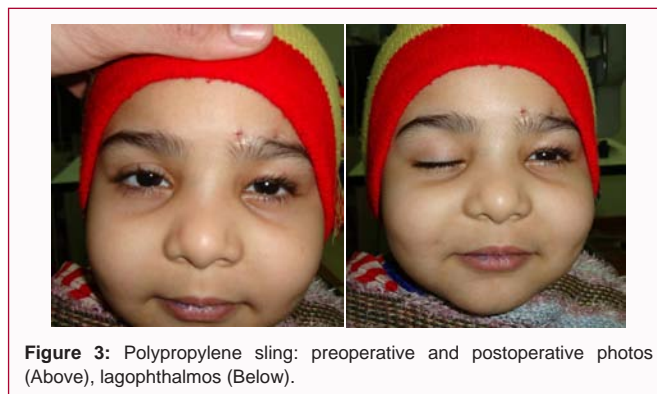


Figure 3: Polypropylene sling: preoperative and postoperative photos (Above), lagophthalmos (Below).

wound. The lid position was readjusted and new prolene knot was tied around silicone tube ends. The knot was deeply buried, and skin was repaired. Infection, inflammatory granuloma or extrusion of silicone tubes did not occur in any case.

Discussion

The use of silicone rods has been described for brow suspension but in the best of our knowledge 0.6 mm silicone lacrimal tubes were not previously reported [7,11]. In this study, silicone lacrimal tubes proved to be easy to apply. Their elasticity gave the lid the chance to close with no or minimal lagophthalmos and reduced lag in down gaze. Lamont et al. [7] found silicone slings comparable to alternative materials in respect of recurrence. He had 19% recurrence that required readjustment of the same silicone sling. Bernardini, Older and Dunne had clear visual axis in all patients affected by myogenic blepharoptosis [9,10]. Carter et al. [11] reported recurrence of ptosis in 4 lids (7%) that required replacement of the silicone rod in 2 lids and revision of the sling in 2 lids.

Using Mersilene mesh, Sharma and Willshaw had recurrence in 4 lids (5.4%) and Mehta had 23% recurrence in 20 lids of children and 25% recurrence in 12 lids of adults [14,15].

Recurrence rate of prolene ranged between 12.5 and 55.6%. The main advantages of the polypropylene suture are the low risk of scarring and soft tissue complications, easy removal, and not interfering with future use of autogenous fascia lata so it is mainly used as a temporary suspension material to prevent amblyopia in young children who are planned to undergo surgery with autogenous fascia lata when they are older [21,26]. Monofilament (Supramid) and polyfilament (Supramid Extra) nylon sutures are also used for temporary suspension [21]. These materials have the same advantages as the polypropylene suture, as well as the high recurrence rate of ptosis (25-69.2%) [6,23-25]. Wasserman et al. [21] reported 31.4% recurrence in a series of 102 cases using autogenous fascia lata, banked fascia lata, monofilament nylon, braided polyester, Gore-Tex, and polypropylene. In this study the recurrence was also comparable (20%).

Lamont et al. [7] found silicone superior to alternative materials in respect of ease of readjustment in failed cases [7]. In this study, silicone tubes allowed easy readjustment of recurrent cases. Readjustment of silicone tubes was simple and easy as it was not complicated with fibrosis or inflammation.

Lamont et al. [7] found silicone slings superior to alternative materials in respect of both granuloma formation and infection. Bernardini et al. [9] found silicone slings safe without occurrence

of granuloma or infection, but they reported one case of exposure keratitis in a series of patients with poor Bell's phenomenon. Several authors reported high rates of extrusion, granuloma formation and infection of the mersilene mesh at the brow skin incision site [12-18]. Hintschich et al. [12] reported a complication rate of 11.6% (9/76 cases) including extrusion, granuloma formation, and infection. Mehta et al. [15] reported 20% soft tissue complications. Mutlu et al. [16] reported a rate of 6.3% for granuloma formation. Ben Simon et al. [23] found Gore-Tex to have the least recurrence but higher incidence of infection. Wasserman et al. [21] 2001 found that 45.5% (5/11) of the frontalis suspension using Gore-Tex required removal of the material because of suspected infection. However, Bajaj et al. [22] found Gore-Tex suture safe and effective sling material for frontalis suspension with higher but statistically insignificant success rate as compared to braided polyester.

References

- Crawford JS. Repair of ptosis using frontalis muscle and fascia lata: a 20-year review. *Ophthalmic Surg.* 1977;8(4):31-40.
- J. S. Crawford, "Frontalis sling operation," *J Pediatr Ophthalmol Strabismus.* 1982;19(5):253-55.
- Beard C. Congenital ptosis. In: *Oculoplastic, Orbital and Reconstructive surgery.* Hornblass A, editor. 1st ed. Williams & Wilkins: Baltimore, PA, 1988;119-41.
- Jordan DR, Anderson RL. Obtaining fascia lata. *Arch Ophthalmol.* 1987;105(8):1139-40.
- Wheatcroft SM, Vardy SJ, Tyers AG. Complications of fascia lata harvesting for ptosis surgery. *Br J Ophthalmol.* 1997;81(7):581-3.
- Wagner RS, Mauriello JA Jr, Nelson LB. Treatment of congenital ptosis with frontalis suspension: a comparison of suspensory materials. *Ophthalmology.* 1984;91(3):245-8.
- Lamont M, Tyers AG. Silicone Sling Allows Adjustable Ptosis Correction in Children and in Adults at Risk of Corneal Exposure. *Orbit.* 2010;29(2):102-5.
- Nerad JA: Surgical correction of eyelid ptosis. Evaluation and treatment of the patient with ptosis. In: *Techniques in Ophthalmic Plastic Surgery: A Personal Tutorial, 1st edn, ch.8, China: Saunders Elsevier, 2010;201-35.*
- Bernardini FP, de Conciliis C, Devoto MH. Frontalis suspension sling using a silicone rod in patients affected by myogenic blepharoptosis. *Orbit.* 2002;21(3):195-8.
- Older JJ, Dunne PB. Silicone Slings for the correction of ptosis associated with progressive external ophthalmoplegia. *Ophthalmic Surg.* 1984;15(5):379-81.
- Carter SR, Meecham WJ, Seiff SR. Silicon frontalis slings for the correction of blepharoptosis. *Ophthalmology.* 1996; 103(4):623-30.
- Hintschich CR, Zurcher M, Collin JRO. Mersilene mesh brow suspension: efficiency and complications. *Br J Ophthalmol.* 1995;79:358-61.
- Kemp EG, Mac Andie K. Mersilene mesh as an alternative to autogenous fascia lata in brow suspension. *Ophthalmic Plast Reconstr Surg.* 2001;17(6):419-22.
- Sharma TK, Willshaw H. Long term follow up of ptosis correction using mersilene mesh. *Eye.* 2003;17(6):759-61.
- Mehta P, Patel P, Olver JM. Functional results and complications of mersilene mesh use for frontalis suspension ptosis surgery. *Br J Ophthalmology.* 2004;88(3):361-4.
- Mutlu FM, Tuncer K, Can C. Extrusion and granuloma formation with mersilene mesh brow suspension. *Ophthalmic Surg Lasers.* 1999;30(1):47-51.
- El-Toukhy E, Salaem M, El-Shewy T, Abou-Steit M, Levine M. Mersilene mesh sling as an alternative to autogenous fascia lata in the management of ptosis. *Eye.* 2001;15(2):178-82.
- Elder MJ. Mersilene mesh and fascia lata in brow suspension: a comparative study. *Ophthalmic Surg.* 1993;24:105-8.
- Zweep HP, Spauwen PHM. Evaluation of expanded polytetrafluoroethylene (e-PTFE) and autogenous fascia lata in frontalis suspension. *Acta ChirPlast.* 1992;34:129-37.
- Steinkogler FJ, Kuchar A, Huber E, Arock-Mettinger E. Gore-Tex soft-tissue patch frontalis suspension technique in congenital ptosis and in blepharophimosis-ptosis syndrome. *Plast Reconstr Surg.* 1993;92(6):1057-60.
- Wasserman BN, Sprunger DT, Helveston EM. Comparison of materials used in frontalis suspension. *Arch Ophthalmol.* 2001;119(5):687-91.
- Bajaj MS, Sastry SS, Ghose S. Evaluation of polytetrafluoroethylene suture for frontalis suspension as compared to polybutylate-coated braided polyester. *Clin Experiment Ophthalmol.* 2004;32(4):415-9.
- Ben Simon GJ, Macedo AA, Schwarcz RM. Frontalis suspension for upper eyelid ptosis: evaluation of different surgical designs and suture material. *Am J Ophthalmol.* 2005;140(5):877-85.
- Saunders RA, Grice CM. Early correction of severe congenital ptosis. *J Pediatr ophthalmology Strabismus.* 1991;28:271-3.
- Katowitz JA. Frontalis suspension in congenital ptosis using a polyfilament, cable-type suture. *Arch Ophthalmol.* 1979;97:1659-63.
- Manners RM, Tyers AG, Morris RJ. The use of prolene as a temporary suspension material for brow suspension in young children. *Eye.* 1994;8(3):346-8.