



## Dermatofibrosarcoma Protuberans. A Rare Occurrence in a Five Years Old Child

Adil Abdelhamed Abbas<sup>1\*</sup>, Majed Nasir Alosaimi<sup>2</sup> and Alaa Mohammed Nour Samkari<sup>3</sup>

<sup>1</sup>Pediatric Hematology/Oncology & BMT, Princess Nourah Oncology Centre, College of Medicine, King Saud Bin Abdulaziz University for Health Sciences, KSA

<sup>2</sup>Department of Surgery, King Saud Bin Abdulaziz University for Health Sciences, King Abdulaziz Medical City, KSA

<sup>3</sup>Department of Laboratory Medicine, King Saud Bin Abdulaziz University for Health Sciences, King Abdulaziz Medical City, KSA

### Abstract

Dermatofibrosarcoma Protuberans (DFSP) is a rare mesenchymal soft tissue sarcoma. The tumor is classified by the World Health Organization as low grade soft tissue sarcoma. DFSP primarily affect the skin and subcutaneous tissue but can invade into deeper tissues. Common sites for the development of the tumor are the head, trunk and extremities. DFSP is very rare in children. Although several histopathological variants of the disease are described, histopathological diagnosis is not so complicated. DFSP carries a diagnostic cytogenetic t(17;22) (q22;q13) which results in the formation in a fusion gene called COL1A1 – PDGFB that promotes the tumor growth in nearly 95% of cases. Complete Surgical Resection (CSR) is the main treatment used however local relapse rates are still high. The Mohs Micrographic Surgery (MMS) is reported to give better results with much less local relapse rates. Tyrosine Kinase Inhibitors (TKI's) such as Imatinib Mesylate (IM) and sorafenib has been used when CSR was not feasible with good results. Here we report a 5-year old girl with localized lower extremity DFSP that was successfully treated with surgery. Although the tumor margins were reported to be microscopically contaminated with the tumor, further surgery was not possible for fears of extensive morbidity. Parents refused the use IM. Although incomplete surgical resection is associated with high-risk disease recurrence, she remains very well one year after surgery with no evidence of disease recurrence.

**Keywords:** Dermatofibrosarcoma protuberans; Soft tissue sarcoma; Mohs micrographic surgery; Histopathological; Sorafenib

### Introduction

DFSP is a rare mesenchymal soft tissue sarcoma of low to intermediate malignancy [1]. The tumor was first described in 1890 by Taylor however, the term DFSP was coined by Hoffman in 1925 [2,3]. DFSP primarily affect the skin and subcutaneous tissue of the trunk, head and neck, abdomen, breast and extremities. DFSP is characterized by exquisite tendency for deep tissue invasion with local growth of highly infiltrative CD34+ spindle cells which in turn makes radical surgical resection very difficult. The tumor is presumed to occur sporadically with no significant predisposing genetic factors. DFSP primarily affect adults of different ages (peak age 20 to 50 years) and is rare in children [4]. The tumor has low incidence (0.4 to 4.1 patients/million/year) and excellent 10-year Overall Survival (OS) of 99.1%. The tumor grows slowly over several months to years and has very low metastatic potential. Most commonly, the tumor appear initially as painless hyper pigmented nodule or plaque and then grow in size. The outcome in children is no different from adults [5,6]. Case reports in children are few [4,7,8]. Clinical diagnosis of DFSP in children is sometimes difficult due to its rarity, similar appearance to benign lesions and occurrence of the disease in unusual sites. Histopathological diagnosis however is not so complicated [7,9]. The tumor was histologically categorized into several subtypes. All subtypes (except the subtype with fibrosarcomatous changes) carry more or less the same prognosis. DFSP carries the diagnostic cytogenetic translocation of chromosomes 17 and 22 that result in the formation of the collagen type I alpha 1 (COL1A1) - Platelet-Derived Growth Factor Beta (PDGFB) fusion gene. Radical Surgical Resection (RSR) is the main treatment used however, local relapse rates are high. The Mohs Micrographic Surgery (MMS) is reported to give the best results. TKI's such as IM and sorafenib has been used in special circumstances with good success [10].

### OPEN ACCESS

#### \*Correspondence:

Adil Abdelhamed Abbas, Pediatric Hematology/Oncology & BMT, Princess Nourah Oncology Centre, College of Medicine, King Abdulaziz Medical City, King Saud bin Abdulaziz University for Health Sciences, P.O. Box: 9515, Jeddah 21423, KSA, Tel: +966566692401;

E-mail: abbasaa@ngha.med.sa

Received Date: 29 Nov 2020

Accepted Date: 21 Jan 2021

Published Date: 27 Jan 2021

#### Citation:

Abbas AA, Alosaimi MN, Samkari AMN. Dermatofibrosarcoma Protuberans. A Rare Occurrence in a Five Years Old Child. *Clin Surg*. 2021; 6: 3043.

**Copyright** © 2021 Adil Abdelhamed Abbas. This is an open access article distributed under the Creative Commons Attribution License, which permits unrestricted use, distribution, and reproduction in any medium, provided the original work is properly cited.

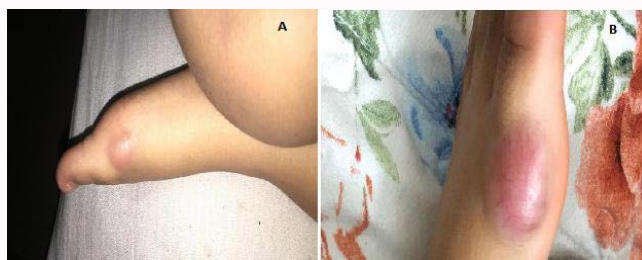
## Case Presentation

A 5-year old female was seen in the orthopedic department in our hospital for a small painless swelling in the medial aspect of her left foot noted to grow over the preceding 6 months. No history of trauma was obtained. She had no other symptoms of note. The child was a product of full term normal delivery after a normal pregnancy. She was diagnosed with congenital hearing loss and bilateral congenital glaucoma soon after birth and had cochlear implant inserted at the age of 10 months. As a result, she was left with significant speech as well as social developmental delay. The cytogenetic and Whole Exome Sequencing (WES) studies revealed no genetic abnormality.

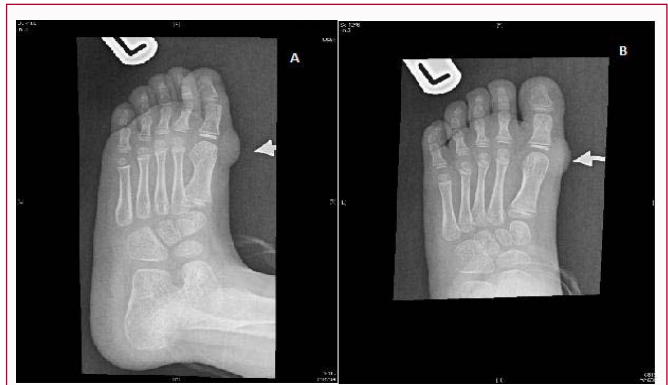
On examination and apart from the mild corneal cloudiness, the patient looked normal with no obvious dysmorphic features and no gait abnormality. A single small swelling (3.0 cm × 2.5 cm) was noted in the superomedial aspect of her left foot overlying the base of the big toe. The lesion was red in color and firm in consistency but not hot or tender. Small superficial blood vessels were seen running in different directions on top of the lesion (Figure 1). Plan X-ray film showed a soft tissue mass (1.8 cm × 1.1 cm) over the superomedial aspect of the left distal metacarpophalangeal joint (Figure 2). Magnetic Resonance Image (MRI) examination was not possible because of incompatibility with her cochlear implant. An Ultrasound (US) examination was arranged instead and showed the superficial soft tissue nodule (2.8 cm × 1.0 cm) with no clear connection to the underlying bones (Figure 3). Computerized Tomography (CT) scan of the chest, abdomen and pelvis showed no metastasis. Tc<sup>99m</sup> nuclear bone scintigraphy (Bone scan) showed no local or distant abnormal bone infiltration (Figure 4). CSR of the tumor was attempted, however and despite the apparent complete resection, histopathological examination showed evidence of tumor infiltration in all resected tumor margins (Figure 5). Molecular Fluorescence *in situ* Hybridization (FISH) confirmed the diagnosis of DFSP (Figure 6). The child made good recovery after surgery and resumed normal activity. The parents refused treatment with IM. After thorough discussion, and because of the risk of excessive morbidity, we decided to wait and watch. Repeat plain X-ray and US scans showed no evidence of tumor recurrence. Although incomplete surgical resection is associated with high-risk of local recurrence, the child remains very well for one year with no evidence of tumor regrowth.

## Discussion

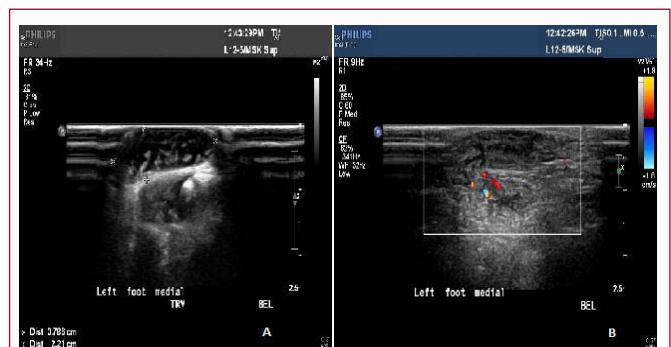
DFSP is a very uncommon sarcoma to us tumor that mainly affect adult patients. The tumor is very rare in children with only few case reports and case series published in the literature [11-13]. Here we



**Figure 1:** Left foot photograph showing the soft tissue lesion in the superior medial aspect of the first metacarpophalangeal joint. The lesion appeared initially small (A) (1 cm × 2 cm) but subsequently increased in size (3 cm × 2.5 cm) and became red, tense but not tender. The skin overlying the lesion showed visible dilated small blood vessels. (B) Shows the same lesion 6 months later.



**Figure 2:** Plain X-ray of the left foot showed the presence of soft tissue nodule measuring 1.8 cm × 1.1 cm superficial and medial to the left first proximal interphalangeal joint with no associated bone or joint changes and no calcifications. No radiopaque foreign body was identified (A & B).

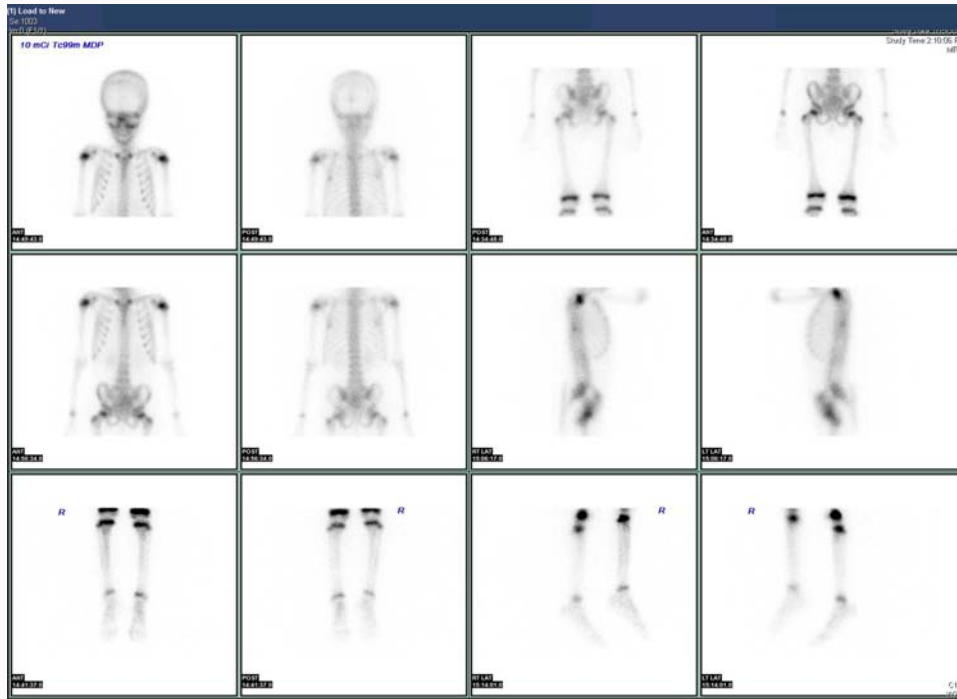


**Figure 3:** US scan of the left foot showed a small (2.8 cm × 1 cm) heterogeneous soft tissue mass overlying the superior medial aspect of the left big toe (A) demonstrating mild vascularity (B).

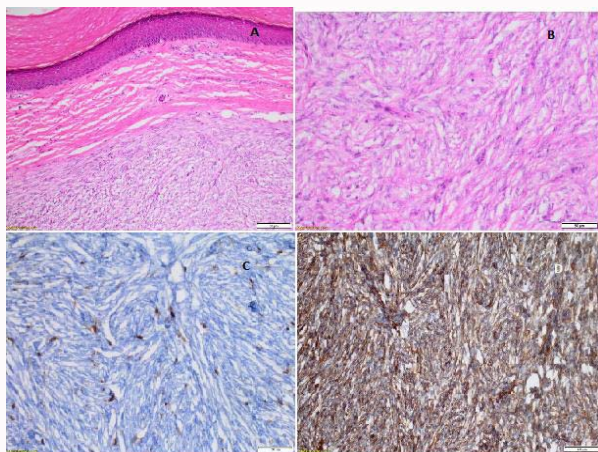
present a 5-year's old female with localized left foot DFSP. She had near total surgical resection of the lesion. Luckily, she remains well with no evidence of relapse one year following surgery.

Lesion of DFSP most commonly appear as indurated dusky lesion and becomes harder and darker in color with time and may develop into multiple nodules. If not removed, lesions may slowly grow into considerable size (>20 cm in diameter). Commonly, the lesion is initially dismissed by the patient, parents and the physician as insignificant. A history of trivial trauma is obtained in most cases. Rarely and in advanced stages, the tumor may invade deeply into the fascia and muscles or metastasize into the local or regional lymph nodes and the lungs [12-14]. CT and MRI scans may show the well circumscribed soft tissue mass that is commonly intensely contrast enhancing. MRI scan may sometimes show the characteristic classical claw sign. DFSP however, is only diagnosed histologically using the excisional biopsy tissue samples and are staged using the Tumor/Node/Metastasis (TNM) staging system used for staging soft tissue sarcomas [15,16].

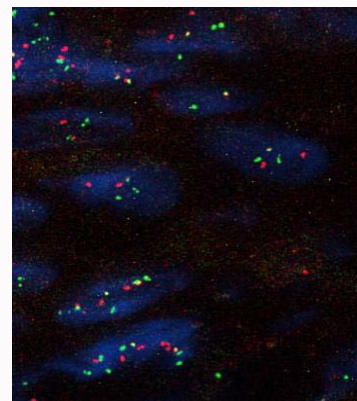
DFSP lesions are basically centered in the dermal layer of the skin and infiltrate through the subcutaneous tissue. Several histopathological types of the disease had been described. The conventional subtype is characterized by the presence of spindle cells with a storiform pattern infiltrating along fibrous bands. The myxoid type is characterized by the presence of infiltrative, often hypocellular, sheet-like, bland spindle cells with pale eosinophilic cytoplasm, spindled nuclei, no pleomorphism. The stroma is



**Figure 4:** Tc<sup>99m</sup> Nuclear bone scintigraphy: Whole body images scan showed normal bio-distribution of radiotracer activity all over the skeleton with no evidence of local or metastatic bone disease.



**Figure 5:** Conventional DFSP: numerous monomorphous spindle cell neoplasm with a storiform pattern is seen infiltrating along the fibrous septa of the dermis and subcutaneous layers of the skin (A) [H&E x20]. The cytoplasm is eosinophilic in reaction (B) [H&E x40]. The nuclei are ovoid and monomorphous with rare mitotic activity. The cells are diffusely positive for CD34 immunomarker (C) and are negative for desmin, smooth muscle actin, S100 and keratin {AE1/AE3} (D) [x40].



**Figure 6:** Color FISH study. Fluorochrome-labeled DNA probes, which hybridize to COL1A1 (red, chromosomal position 17q21) and PDGFB (green, chromosomal position 22q13). The analysis of 50 nuclei revealed that 20 (40%) of the nuclei showed a red/green fusion signal (Threshold: 20%) indicating COL1A1/PDGFB translocation and confirming the diagnosis of DFSP.

myxoid and contains prominent thin walled blood vessels. Juvenile DFSP (also known as giant fibroblastoma) is characterized by the presence of giant spindle tumor cells. This particular type is more common in children and adolescents. DFSP with fibrosarcomatous transformation that mimics undifferentiated pleomorphic sarcoma is a more malignant infiltrative subtype. Except for the presence of the highly malignant fibrosarcomatous changes which is associated with higher risk of recurrence, these histopathological variants have not been shown to carry any prognostic significance [17-19].

Our patient presented at an early age with typical presentation of

a low grade malignant tumor. The tumor appeared in the distal part of her left foot as a small slowly growing non-tender papule without antecedent history of trauma. The patient in addition, had congenital deafness and cochlear implant. The use MRI scan to properly assess the tumor was therefore not possible due to compatibility issues. After discussion with the pediatric radiologist we decided to obtain plain radiograph and US scans only. The orthopedic surgeon was satisfied with the radiological images before surgery. CT and a nuclear bone scans obtained thereafter showed no evidence of metastasis. The child had what appeared to be as CSR at the time of surgery however, histopathology showed contamination of the tumor margins with the tumor. Repeat plain X-ray and US examination after surgery showed mild tissue thickening at the site of the surgery representing post-

surgical changes and luckily these changes have disappeared shortly thereafter.

CSR of the DFSP lesion with negative resection margin remains the main goal as it has been shown reduce the local recurrence rate to <30% [20]. However, the local recurrence rates after incomplete surgical excision is between 26% and 60% [21]. The local recurrence rate in general remains inversely proportional to the degree of surgical resection. MMS has been shown to have results with a lower local recurrence rate of <8% [22,23]. In this type of surgery serial microscopic examinations are performed while the surgical resection is ongoing, until clear margins are reached. Our patient apparently had CSR however, histopathology proved tumor margins contamination. In fact when surgery was planned earlier, surgeons were favoring a benign diagnosis and the diagnosis of DFSP came only as surprise after surgery.

We discussed the possibility of further resection or micrographic surgery however the orthopedic surgeon indicated that second surgery was not possible as they have removed all visible tumor tissue even that attached to the joint capsule. Further surgical resection in that case would only mean amputation of at least the big toe. Therefore, and after discussion with the parents, we decided to watch and wait with frequent clinical and radiological surveillance.

Conventional CTR is rather ineffective. DFSP however, is Radiosensitive and Radiotherapy (RT) is sometimes indicated for tumors with positive margins in adult patients. The effective dose is however large (60 Gy to 70 Gy). The use of RT has become very limited nowadays especially after the discovery of efficacy IM [24]. Recently, the emerging multikinase inhibitors pazopanib and regorafenib have shown very good activity against the disease [25,26].

Confirmation of the presence of the COL1A1-PDGFB fusion gene by FISH is a useful tool to identify patients who may be candidates for treatment with IM and for the differential diagnosis of DFSP with other CD34+ tumors or CD34-DFSP. COL1A1-PDGFB fusion gene is generally identified in nearly 85% of DFSP patients [10].

In patients with inoperable or widely metastatic disease and in patients with residual tumor after surgery, the best option is the use of TKI's. IM have shown impressive clinical results in such situations and is currently the drug of choice [27]. We offered the family this option but after thorough discussion, the parents decided against IM. They were in fact prepared to take the higher risk of local or metastatic relapse than going for further surgery or starting IM. Luckily, the child remains well one year after surgery and without further therapy with no evidence of relapse.

## References

- Doyle LA. Sarcoma classification: An update based on the 2013 World Health Organization Classification of tumors of soft tissue and bone. *Cancer*. 2014;120(12):1763-74.
- Schiff BL, Tye MJ, Kern AB, Moretti G, Ronchese F. Dermatofibrosarcoma protuberans. Review of the literature and report of four cases. *Am J Surg*. 1960;99:301-6.
- Hoffman E. I. Über das knollentreibende Fibrosarkom der Haut (Dermatofibrosarkoma protuberans). *Dermatolgy*. 1925;43:1-28.
- Wollina U, Langner D, Schönlebe J, França K, Lotti T, Tchernev G. Dermatofibrosarcoma Protuberans: Retrospective single center analysis over 16 years. *Open Access Maced J Med Sci*. 2018;6(1):35-7.
- Kreicher KL, Kurlander DE, Gittleman HR, Barnholtz-Sloan JS, Bordeaux JS. Incidence and survival of primary dermatofibrosarcoma protuberans in the United States. *Dermatol Surg*. 2016;42(Suppl 1):S24-31.
- Criscito MC, Martires KJ, Stein JA. Prognostic factors, treatment, and survival in dermatofibrosarcoma protuberans. *JAMA Dermatol*. 2016;152(12):1365-71.
- Goyal P, Sehgal S, Singh S, Rastogi S. Dermatofibrosarcoma protuberans in a child: A Case report. *Case Rep Dermatol Med*. 2012;2012:796818.
- Tanaka R, Inagawa K, Kanomata N, Hata J, Fujimoto W. Photoletter to the editor: Pigmented dermatofibrosarcoma protuberans in a 4-year-old girl and ultrasonographic findings. *J Dermatol Case Rep*. 2015;9(2):52-4.
- Ucak M. A Rare Case of Misdiagnosis: Recurrence of dermatofibrosarcoma protuberans that was treated surgically as a keloid. *Med Arch*. 2018;72(1):74-5.
- Zheng Z, Piao J, Lee JH, Kim SE, Kim SC, Chung KY, et al. Dermatofibrosarcoma protuberans: A study of clinical, pathologic, genetic, and therapeutic features in Korean patients. *Yonsei Med J*. 2015;56(2):440-6.
- Pappo AS, Rao BN, Cain A, Bodner S, Pratt CB. Dermatofibrosarcoma protuberans. The pediatric experience at St. Jude Children's Research Hospital. *Pediatr Hemato Oncol*. 1997;14(6):563-8.
- Taylor HB, Helwig EB. Dermatofibrosarcoma protuberans: A study of 115 cases. *Cancer*. 1962;15:717-25.
- McPeak CJ, Cruz T, Nicastrri AD. Dermatofibrosarcoma protuberans: An analysis of 86 cases-five with metastasis. *Ann Surg*. 1967;166(5):803-16.
- Bendix-Hansen K, Myhre-Jensen O, Kaae S. Dermatofibrosarcoma protuberans. A clinico-pathological study of nineteen cases and review of world literature. *Scand J Plast Reconstr Surg*. 1983;17(3):247-52.
- Zhang L, Liu QY, Cao Y, Zhong JS, Zhang WD. Dermatofibrosarcoma protuberans: Computed tomography and magnetic resonance imaging findings. *Medicine (Baltimore)*. 2015;94(24):e1001.
- Sung TH, Tam AC, Khoo JL. Dermatofibrosarcoma protuberans: A comprehensive review on the spectrum of clinico-radiological presentations. *J Med Imaging Radiat Oncol*. 2017;61(1):9-17.
- Brenner W, Schaeffler K, Chhabra H, Postel A. Dermatofibrosarcoma protuberans metastatic to a regional lymph node. Report of a case and review. *Cancer*. 1975;36(5):1897-902.
- Beham A, Fletcher CD. Dermatofibrosarcoma protuberans with areas resembling giant cell fibroblastoma: Report of two cases. *Histopathology*. 1990;17(2):165-7.
- Calonje E, Fletcher CD. Myoid differentiation in dermatofibrosarcoma protuberans and its fibrosarcomatous variant: Clinicopathologic analysis of 5 cases. *J Cutan Pathol*. 1996;23(1):30-6.
- Bowne WB, Antonescu CR, Leung DH, Katz SC, Hawkins WG, Woodruff JM, et al. Dermatofibrosarcoma protuberans: A clinicopathologic analysis of patients treated and followed at a single institution. *Cancer*. 2000;88(12):2711-20.
- Lemm D, Mügge LO, Mentzel T, Höffken K. Current treatment options in dermatofibrosarcoma protuberans. *J Cancer Res Clin Oncol*. 2009;135(5):653-65.
- Paradisi A, Abeni D, Rusciani A, Cigna E, Wolter M, Scuderi N, et al. Dermatofibrosarcoma protuberans: Wide local excision vs. Mohs micrographic surgery. *Cancer Treat Rev*. 2008;34(8):728-36.
- Roh MR, Bae B, Chung KY. Mohs' micrographic surgery for dermatofibrosarcoma protuberans. *Clin Exp Dermatol*. 2010;35(8):849-52.
- Ugurel S, Kortman RD, Mohr P, Mentzel T, Garbe C, Breuninger H. Short German Guidelines: Dermatofibrosarcoma Protuberans. *J Dtsch Dermatol Ges*. 2008;6(Suppl 1):S17-8.
- Miyagawa T, Kadono T, Kimura T, Saigusa R, Yoshizaki A, Miyagaki T,

- et al. Pazopanib induced a partial response in a patient with metastatic fibrosarcomatous dermatofibrosarcoma protuberans without genetic translocations resistant to mesna, doxorubicin, ifosfamide and dacarbazine chemotherapy and gemcitabine-docetaxel chemotherapy. *J Dermatol.* 2017;44(3):e21-2.
26. Mir O, Brodowicz T, Italiano A, Wallet J, Blay JY, Bertucci F, et al. Safety and efficacy of regorafenib in patients with advanced soft tissue sarcoma (REGOSARC): A randomized, double-blind, placebo-controlled, phase 2 trial. *Lancet Oncol.* 2016;17(12):1732-42.
27. Jeon IK, Kim JH, Kim SE, Kim SC, Roh MR. Successful treatment of unresectable dermatofibrosarcoma protuberans on finger with imatinibmesylate and Mohs microsurgery. *J Dermatol.* 2013;40(4):288-9.