



Degenerative Aneurysms of Chronic Type B Dissection Can be Repaired with Branched Devices Either Using the True, False or Both Lumens of the Dissection

Rodrigues EO, Cunha RC, Ferreira DM, Bicalho GC and Ferreira MV*

Department of Vascular and Endovascular Surgery, SITE Endovascular, Rio de Janeiro, Brazil

Commentary

Aortic dissection is a very challenging and dynamic pathology that may present itself in many forms. The INSTEAD trial has demonstrated that over a period of five years, treating uncomplicated type B dissections with TEVAR (thoracic endovascular repair) has demonstrated better outcomes than best medical treatment. Landmark analysis suggested a benefit of TEVAR for all end points between 2 and 5 y; for example, for all-cause mortality (0% vs. 16.9%; $P=0.0003$), aorta-specific mortality (0% vs. 16.9%; $P=0.0005$), and for progression (4.1% vs. 28.1%; $P=0.004$) [1].

The great discussion is whether sealing the proximal tear is sufficient to promote false lumen thrombosis.

Clinical evidence demonstrated that aneurysm formation in chronic dissections is reported to be present in 35% of the patients with 36% mortality over a period of three years [2].

Over the past years the use of fenestrated and branched stent grafts (F/BEVAR) to exclude the false lumen completely has been proposed with promising early and mid-term results as the only way to avoid late complications [3].

In this article we will demonstrate that not only should we correct the aorta to its full extent, but also that the intentional placement of the endograft into the false lumen is feasible and sometimes necessary in specific cases as the best alternative to promote adequate blood supply to the visceral segment and exclude the dissected aorta.

Since 2012, our group has been routinely using either custom made device (CMD) or over the shelf (OTS) devices to treat late complications of aortic dissection, especially when visceral arteries are involved. The follow up of these patients have demonstrated complete false lumen thrombosis and initially better patency of the visceral branches when compared to aortic aneurysms.

In our experience, the chronic septum between the false lumen and the true lumen, that is believed to be thick and non complacent, does not seem to be an issue. The narrow true, which is seen as an issue in chronic dissections, has neither been a problem to navigate the device or to catheterize the visceral vessels.

The main strategy is to redirect the aortic blood in flow towards target vessels. Many times the visceral vessels are irrigated by both lumens.

The main consideration that should be done is where to land the branched device to allow adequate targets vessels catheterization. This can be done either by using the true lumen, the false lumen or both lumens, as long as the target vessels can be connected to the branches of the device.

The decision to use one or the other relies upon convenience of the surgeon and the presence of the re-entrances between the true lumen and the false lumen, and upon the diameter of the true lumen observed in the angiotomography.

One of the main concerns when treating the aorta to its full extent is the spinal cord ischemia. Ideally we propose staged interventions to allow adequate collateralization. The intra operative strategy to prevent spinal cord injury is to maintain spinal fluid pressure less than 12 mmHg and the mean arterial pressure never below 80 mmHg.

As described by Dr. Griep's work [4] adequate internal iliac and vertebral blood supply should be present to supply the spinal cord blood flow. Whenever necessary subclavian revascularization

OPEN ACCESS

*Correspondence:

Marcelo Ferreira, Department of Vascular and Endovascular Surgery, SITE Endovascular, Rio de Janeiro, Brazil, E-mail: marceloferreira1959@gmail.com

Received Date: 29 Apr 2017

Accepted Date: 06 Jun 2017

Published Date: 13 Jun 2017

Citation:

Rodrigues EO, Cunha RC, Ferreira DM, Bicalho GC, Ferreira MV. Degenerative Aneurysms of Chronic Type B Dissection Can be Repaired with Branched Devices Either Using the True, False or Both Lumens of the Dissection. *Clin Surg*. 2017; 2: 1511.

Copyright © 2017 Ferreira MV. This is an open access article distributed under the Creative Commons Attribution License, which permits unrestricted use, distribution, and reproduction in any medium, provided the original work is properly cited.

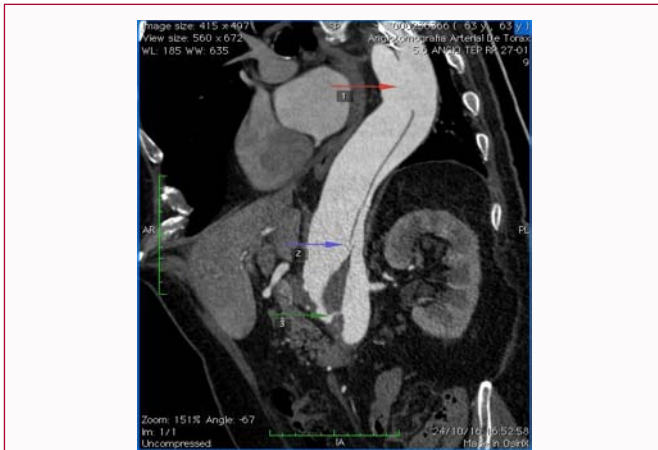

Figure 1: 3D MPR Tomography reconstruction demonstrating main fenestrations between the true lumen and the false lumen (the colored arrows demonstrate the fenestrations).

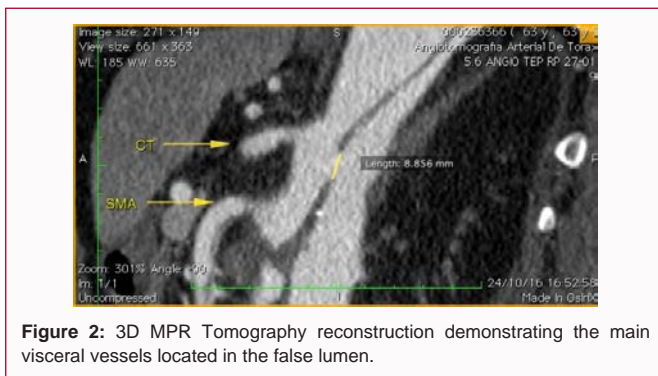


Figure 2: 3D MPR Tomography reconstruction demonstrating the main visceral vessels located in the false lumen.

is advised before deploying the thoracic graft. All internal iliac arteries should be revascularized with branch devices given that they participate in medular perfusion.

When treating these aortic dissection cases, access is also a caveat since most of these patients have been previously submitted to arch corrections with bypasses to the supra aortic trunks. In Figure 1 we see a case of a patient that presented onset of symptoms in 2015 with acute chest pain and was taken to the hospital and submitted to emergency replacement of the arch with a dacron graft bypass to the brachiocephalic trunk and to the left carotid artery, associated to anantegrade deployment of a aortic endograft into the descending aorta.

One year later he developed a chronic dissection with aneurysmal degeneration of the entire descending and thoracoabdominal aorta, with all the visceral vessels except the left renal revascularized from the false lumen. We can observe in the tomography that three main fenestrations connected the false lumen and the true lumen. In some cases as demonstrated in Figure 2, most of the visceral vessels were located within the false lumen except for the left renal. The problem with in this particular case was gaining access due to the previous dacron graft, as demonstrated in Figure 3.

Several intraoperative maneuvers had to be used in order to overcome anatomical challenges:

1- In order to use the T branch, it was necessary to accommodate a thoracic 36-30 mm tapered device to fit the OTS T-branch which has a 34 mm proximal diameter.

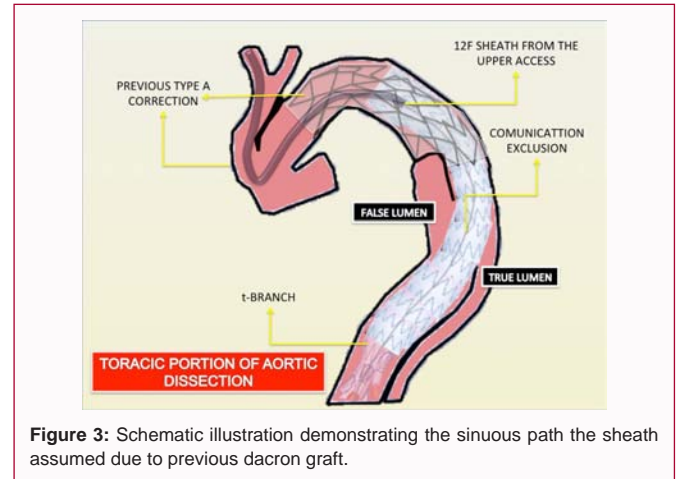


Figure 3: Schematic illustration demonstrating the sinuous path the sheath assumed due to previous dacron graft.

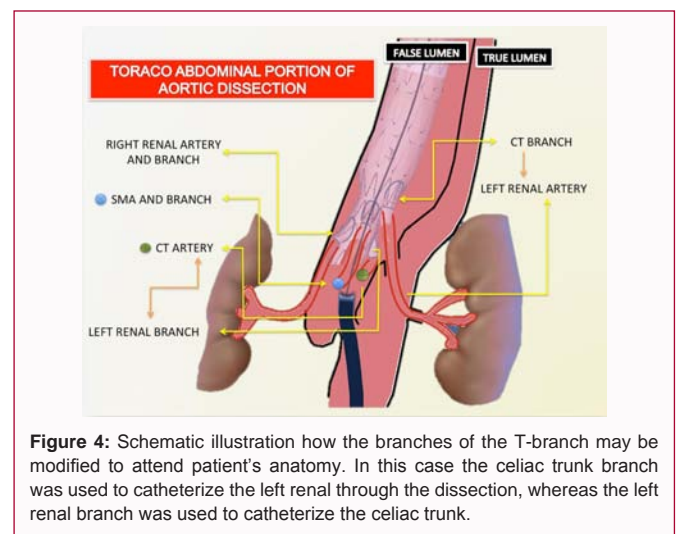


Figure 4: Schematic illustration how the branches of the T-branch may be modified to attend patient's anatomy. In this case the celiac trunk branch was used to catheterize the left renal through the dissection, whereas the left renal branch was used to catheterize the celiac trunk.

2- Access to the false lumen from femoral access to deploy the main graft in the false lumen: It was necessary to use a very small fenestration located below the renal sin order to migrate the device from the true lumen into the false lumen.

3- Previous arch surgery: Visceral branch catheterization from the subclavian into the ascending aorta was very tortuous. It was necessary to use the Tip Driven by the sheath maneuver.

4- Left renal catheterization from a small very narrow communication between the two lumens located in the topography of the celiac trunk. It was necessary to use the Snare ride technique to adequately catheterize the vessel.

T-branch considerations/Possible modifications

The T-branch is an off the shelf (OTS) device developed to attend most of the patient's anatomy. It has four caudally oriented branches positioned according to pre-determined clock positioned CT studies. The celiac trunk branch is positioned at 1:00 o'clock, the superior mesenteric artery 12:00 o'clock, the left renal at 3:00 o'clock and right renal at 9:00 o'clock.

According to Torselo's publication in the Journal of Endovascular Therapy in 2013 the T-branch was able to attend 49% of the patients anatomies. In his own conclusion he wrote that another 14% of the patients could have been suitable for the graft if additional maneuvers had been performed, thus reaching a 63% suitability [4].

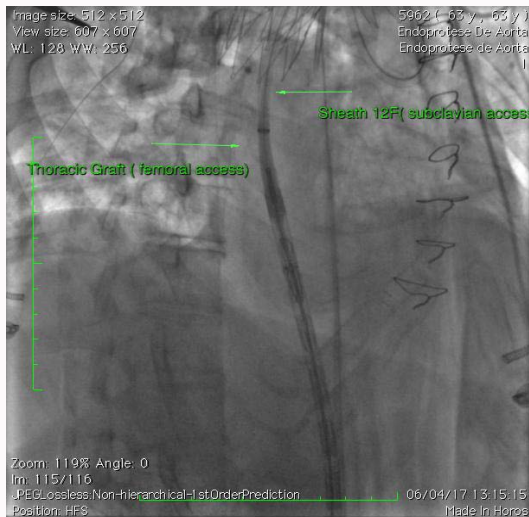


Figure 5: Per-operative angiography demonstrating the Driven by the Sheath maneuver.

In our experience, after adapting and modifying the T-branch, our applicability rates reach 80% of the cases or even more.

Even though the graft originally measures 202 cm, if necessary, both proximal and distal stents can be withdrawn thus diminishing proximal aortic coverage and decreasing the risk of spinal cord ischemia.

In order to facilitate catheterization of the target vessels, staged opening of the T-branch is very helpful. Ideally both the celiac trunk (CT) and superior mesenteric artery (SMA) should be selectively catheterized with a guide wire before placing the stent. Pre catheterization of the CT avoids covering its origin when the SMA Stent is deployed.

Another maneuver that becomes very helpful is to selectively use the 4 branches of the T-branch according to each patient's anatomy. As demonstrated in Figure 4, the celiac branch was used to catheterize the left renal and the left renal branch was used to catheterize the celiac trunk. Although there was a switch in the original configuration the final result demonstrated excellent blood flow in the visceral arteries.

Another important consideration is that any of the four branches can be intentionally occluded with plugs or modified stent grafts with coils. This can be done either during the procedure, or during a second intervention to allow blood flow into the aneurysm sac functioning as a medullary perfusion branch.

Tip driven by the sheath

To facilitate the migration of the branched endograft through tortuous vessels and previous devices the trick is to use the maneuver Driven by the Sheath. It is necessary to use a through and through wire using the femoral and subclavian access. It is also important to place a 12F sheath from the subclavian access as low as possible to position the tip and insert the nose of the device. Once inside the tip of the upper sheath, the nose from the graft remains attached to the device, it moves upward as a unique piece.

The device migrates forward, guided by the tip of the upper access sheath avoiding any contact with the aortic wall or any previous device.

It is necessary to perform a uniform coordinated movement in

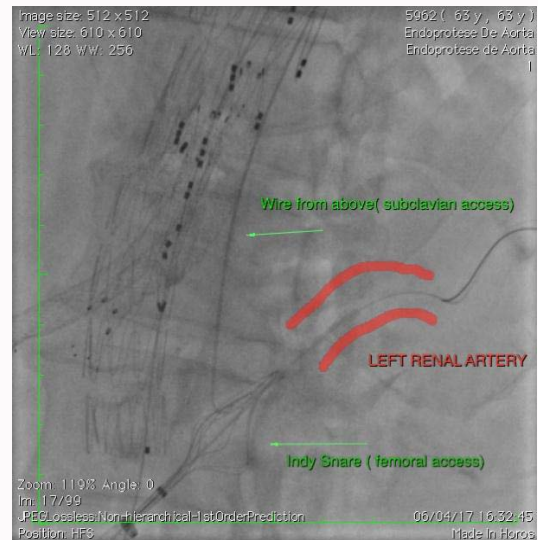

Figure 6: Per operative the Snare Ride Technique.

such a way that the surgeon advances the graft from below while the assistant retrieves the sheath from above as demonstrated in Figure 5.

Snare ride technique

The snare ride originally created by our group in 2016, published in the JEVT (epub ahead from print 2017 DOI: 10.1177/1526602817709465), is a technique that could be used as a bailout technique whenever the target vessel catheterization is difficult, like upward or short renal arteries without enough space to be supported by a single wire. Figure 6 illustrates the technique.

In the example below, the left renal was very difficult to catheterize from above and through the communication because of the distance from the branch and also because it was short with an upward orientation. Using the femoral access within the true lumen, the left renal was catheterized with a cobra 2 catheter over a roadrunner wire and then, once the vessel was catheterized, the catheter was exchanged for an Indy Snare (It is important to note, that to our knowledge, currently the Indy snare is the only snare that works over the wire).

From the subclavian access the communication was catheterized and expanded with regular balloon angioplasty. The roadrunner guide wire was exchanged for a Amplatz extra stiff wire. The Amplatz wire was snared by using the IndySnare (Cook Bloomington USA) and pushed inside the left renal artery. Once inside the artery we opened the connection Stent, in this case a long Fluency (Bard) and then the Snare was carried out. The snare besides helping the catheterization also functioned as an anchor to stabilize stent deployment as demonstrated in Figure 6.

Perspectives

Originally only type A and complicated type B dissections undergone surgical repair. Nowadays, with increasing understanding early repair have been indicated.

Clinical evidence has demonstrated that early repair seems to have greater impact on future aortic remodeling, false lumen thrombosis and lower aneurysm degeneration.

Restoring most, if not all, flow through the true lumen has been a goal of surgical and endovascular treatment.

According to Dr. Chiesa [6], the most common situation

for TEVAR failure requiring conversion to open surgery is false lumen enlargement leading to aneurysmal degeneration and subsequent rupture. This is mainly due to false lumen reperfusion and repressurization, caused by unsuccessful exclusion of the proximal entry tear (i.e Type I-A endoleak or late migration) or distal reperfusion from abdominal re-entry tears (even after successful coverage of the proximal entry tear).

Size mismatch between the distal end of the stent graft and the remarkably small diameter of a compressed distal true lumen (TL) may contribute to relatively excessive oversizing that contributes to distal endoleak or re-dissections, with stent induced distal re-dissection (SIDR) associated with mortality of approximately 25% [7].

Despite the different techniques to promote true lumen expansion, due to the chronicity of the dissection, aortic remodeling does not occur in all cases. Due to this physical phenomenon a shift in paradigm has been proposed and many aortic centers drew their attention toward the residual pressure in the false lumen.

In the past when the primary entry tear was located mainly in the thoracic aorta, besides the correction with a TEVAR, many centers have advocated different techniques to obliterate the false lumen to avoid late retrograde filling.

Mosop and coworker first published a series of patients treated with proximal TEVAR combined with the use of distal bare metal stents. This technique which became known as the PETITCOAT technique [8].

Another proposed technique done to avoid retrograde filling was proposed by Hofferberth and colleagues [9]. They advocated the aggressive expansion and disruption of the intimal membrane to equalize pressures between true and false lumen. This technique which was first described in acute expansions coined the acronym STABILISE which stands for the stent assisted balloon induced intimal disruption and relamination in aortic dissection repair.

The first techniques to induce false lumen thrombosis was coil embolization. Due to the effort and cost needed to treat large patent false lumens with individual embolic coils, many centers used Amplatzer plugs. Due to elevated costs and low effectiveness, both of techniques were soon abandoned.

Kolbel and colleagues proposed the Candy Plug technique that was originally done by a modified thoracic stent graft to plug the false lumen. Later on, the Knickerbocker technique was developed and based on the dilation of the middle part of a large diameter stent graft that is placed in the true lumen to rupture the dissection membrane. A short bulbous segment of the stent graft is forcefully dilated using a compliant balloon to rupture the dissection membrane [10].

Interestingly Dr. Mastracci compiled a chapter review published in 2016 addressing all these techniques used for false lumen embolization. Her conclusion after reviewing literature was that the role of false lumen embolization was not clear and had yet to be defined as a routine protocol for aortic dissections [11].

In 2013 Dr. Greenberg published a ten year review that included 30 patients treated with fenestrated endografts. In order to minimize the risk of paraplegia and to allow for aortic remodeling, staged procedures separated by two months interval were done. His group observed that, aside from the proximal sealing and fixation zone

there exist three regions of potential failures: the intergraft joint the interface between a branch and the distal visceral or brachiocephalic artery and the distal sealing zone [12].

Despite all the difficulties they obtained good results and concluded that FEVAR was feasible and could be used to treat these patients.

The following year, Dr. Verho even demonstrated his initial experience and outcomes of fenestrated/branched endografts in chronic post dissection thoracoabdominal aneurysms. A total of 31 patients (25 male, mean age 65 11.4 years) were treated. Technical success was 93.5% and 30-day mortality 9.6% [3].

Management of the aortic dissection can, however be challenging when several important brachiocephalic or visceral arteries originate from different lumens. Under such circumstances thrombosis of the false lumen may actually disrupt blood flow to vital organs and structures and result in devastating complications such as paraplegia, cerebrovascular lesions, bowel ischemia and renal failure [13].

At all instances access from the false lumen to the proximal landing zone in the true lumen is essential. The rationale for using the false lumen as the route for placement of an endovascular graft in an aortic dissection is based on many factors. The true lumen is smaller in almost all aortic dissections and particularly in chronic stages can be very restrictive. The false lumen will most often allow full extension of the graft [12].

Alternatively, the false lumen intentional placement (FLIP) technique can be used, as demonstrated throughout the chapter [14].

Dr. Watanabe et al. [15] performed repair of a dissecting thoracoabdominal aneurysm with a compressed true lumen by first performing visceral debranching, followed by placement of a bifurcated graft in the false lumen.

Recently published in the annals of vascular surgery, Dr. Kaumann and colleagues published two case reports where the thoracic endograft was intentionally plotted within the false lumen to correct a chronic aortic dissection with satisfactory outcomes [16].

Before performing aortic dissection endovascular corrections, careful planning is fundamental. It is necessary to decide before hand which lumen to look for and was to land your main graft in order to promote adequate visceral perfusion.

Our group have been performing endovascular repair of chronic type B dissections with branched devices since 2012. Recent experience has demonstrated that the OTS T-branch attends most patients' anatomies. Even in patients with narrow true lumens we have implemented the use of OTS devices with good results.

Whenever the patient has a unfavorable anatomy we advocate all the intra operative graft modifications previously mentioned. Even in patients with cephalic oriented branches are suitable for the T-branch.

As previously described the snare ride technique can be used as bail out for cephalic oriented branches as well as those with difficult catheterization. The main advantage of this maneuver is that the Indy snare, allows you to gain extra support to catheterize vessels. It is less morbid than retroperitoneal retrograde catheterization, and is less costly.

Another advantage is that by using the snare ride, you can connect the target vessels through previous fenestrations and is not necessary

to further fenestrate the aorta with perforating devices.

We strongly believe that it's very important to stop all the blood flow to the false lumen to prevent the pressurization and aortic degeneration of it.

In conclusion, the Branched devices either CMD or OTS can be used to repair Degenerative Thoracoabdominal aneurysms after Chronic Dissections. In situations where most visceral vessels are located within the false lumen, and the true lumen is too narrow, the graft can be deployed within the false lumen thus allowing adequate visceral perfusion, eventually both lumens can be used depending on the visceral vessels anatomy after the dissection as we demonstrated in the illustrative case here reported.

The important message is: to avoid blood flow in the false lumen outside the device implanted and exclude all the possible reentries that may result in late aortic degeneration.

References

- Nienaber CA, Kische S, Rousseau H, Eggebrecht H, Rehders TC, Kundt G, et al. Endovascular repair of type B aortic dissection: long-term results of the randomized investigation of stent grafts in aortic dissection trial. *Circ Cardiovasc Interv.* 2013;6(4):407-16.
- Scali ST, Feezor RJ, Chang CK, Stone DH, Hess PJ, Martin TD, et al. Efficacy of thoracic endovascular stent repair for chronic type B aortic dissection with aneurysmal degeneration. *J Vasc Surg.* 2013;58(1):10-7.
- Luozzo GD, Wilderman M, Pawale A, McCullough J, Griep RB. Planned Staged Repair of Thoracoabdominal Aortic Aneurysms to Minimize Spinal Cord Injury: A Proof of Concept. *Aorta (Stamford).* 2015;3(5):177-80.
- Oikonomou K, Kopp R, Katsargyris A, Pfister K, Verhoeven EL, Kasprzak P. Outcomes of fenestrated/branched endografting in post-dissection thoracoabdominal aortic aneurysms. *Eur J Vasc Endovasc Surg.* 2014;48(6):641-8.
- Bisdas T, Donas KP, Bosiers M, Torsello G, Austermann M. Anatomical suitability of the T-branch stent-graft in patients with thoracoabdominal aortic aneurysms treated using custom-made multibranched endografts. *J Endovasc Ther.* 2013;20(5):672-7.
- Chiesa R, Melissano G. Aortic Dissections, Patient true stories and the innovations that saved their lives. 2016:321-337.
- Dong Z, Fu W, Wang Y, Wang C, Yan Z, Guo D, et al. Stent graft- induced new entry after endovascular repair for Stanford type B aortic dissection. *J VascSurg.* 2010;52:1450e7.
- Nienaber CA, Kische S, Zeller T, Rehders TC, Schneider H, Lorenzen B, et al. Provisional extension to induce complete attachment after stent graft placement in type B aortic dissection: the PETTICOAT concept. *Endovasc Ther.* 2006; 13:786-46.
- Hofferberth SC, Foley PT, Newcomb AE, Yap KK, Yii MY, Nixon IK, et al. Combined proximal endografting with distal bare-metal stenting for management of aortic dissection. *Ann Thorac Surg.* 2012;93(1):95-102.
- Kölbl T, Lohrenz C, Kieback A, Diener H, Debus ES, Larena-Avellaneda A. Distal false lumen occlusion in aortic dissection with a homemade extra-large vascular plug: the candy-plug technique. *J Endovasc Ther.* 2013;20(4):484-9.
- Mastracci T. Aortic Dissections, Patient true stories and the innovations that saved their lives. 2016:305-13.
- Kitagawa A, Greenberg RK, Eagleton MJ, Mastracci TM, Roselli EE. Fenestrated and branched endovascular aortic repair for chronic type B aortic dissection with thoracoabdominal aneurysms. *J Vascular Surgery.* 2013;58:625-34.
- Urbanski PP, Bougioukakis P, Deja MA, Diegeler A, Irimie V, Lenos A, et al. Open aortic arch surgery in chronic dissection with visceral arteries originating from different lumens. *Eur J Cardiothorac Surg.* 2016;49(5):1382-90.
- Quinones-Baldrich W, Saleem T. Aortic Dissections, Patient true stories and the innovations that saved their lives. 2016:349-56.
- Watanabe Y, Kuratani T, Shirakawa Y, Torikai K, Shimamura K, Sawa Y. Hybrid Endovascular repair of dissecting thoracoabdominal aortic aneurysm with stent graft implantation through the false lumen. *J Vasc Surg.* 2014;59:264-7.
- Kamman AV, William DM, Patel HJ. Thoracic Endovascular Aortic Repair into the false lumen in chronic aortic dissection. *Ann Vasc Surg.* 2017.