



## Decompressive Craniectomy Following Severe Traumatic Brain Injury with an Initial Glasgow Coma Scale Score of 3 or 4

Afif AFIF\*

Department of Neurosurgery and Anatomy, Pierre Wertheimer Hospital, France

### Abstract

**Background:** Decompressive craniectomy is a surgical management option for severe Traumatic Brain Injury (TBI). However, few studies have followed patients with TBI who have a Glasgow Coma Scale (GCS) score of 3 or 4 (out of 15). Decompressive craniectomy has been avoided in such patients owing to poor outcomes and poor functional recoveries in previous cases of treatment using this method.

**Clinical Presentation:** Two patients are presented in our case series. The first suffered severe TBI following an aggression, with a GCS score of 3 and bilaterally dilated unreactive pupils. Brains CT scan showed right frontal fracture, bifrontal hematoma contusion, a fronto-temporo-parietal acute Subdural Hematoma (SDH) with a thickness of 14 mm on the right side, traumatic subarachnoid hemorrhage, with 20 mm of midline shift to the left side, and diffuses brain edema. The second presented with severe TBI following an automobile accident, with a GCS score of 4 and iso-reactive pupils. A brain CT scan showed bilateral fronto-temporal fracture, diffuse brain hematoma contusion, traumatic subarachnoid hemorrhage, right Extradural Hematoma (EDH) and bilateral fronto-temporo-parietal acute SDH that was more pronounced on the right side.

**Conclusion:** Follow-up after the operations showed an Extended Glasgow Outcome Scale (EGOS) score of 8 and a very good functional recovery for both patients. Our case series suggests that in patients with severe TBI and a GCS score of 3 or 4; decompressive craniectomy can be performed with good long-term neurological outcomes. The speed with which a decision of surgical indication is made may affect neurological outcomes.

**Keywords:** Decompressive craniectomy; Functional recovery; Glasgow coma scale; Traumatic brain injury; Extended glasgow outcome scale

### Abbreviations

TBI: Traumatic Brain Injury; GCS: Glasgow Coma Scale; SDH: Subdural Hematoma; EGOS: Extended Glasgow Outcome Scale; EDH: Extradural Hematoma; ICU: Intensive Care Unit

### Background

Decompressive craniectomy has been used as a treatment option for severe Traumatic Brain Injury (TBI) since 1971 [1]. Early outcomes of decompressive craniectomy were predictably poor, with high mortality and poor functional outcome rates in survivors [1-3]. However, several studies report good outcomes and reduced mortality when decompressive craniectomy is performed early following traumatic brain injury [4-6]. Other studies have demonstrated that clinical outcomes of decompressive craniectomy are worse in patients with poor Glasgow Coma Scale (GCS) scores ( $\leq 8$  out of 15). Few studies have followed patients with TBI and a GCS score of 3 or 4 [7,8]. Tien et al., [9] reported an overall mortality rate of 100% in patients with a GCS score of 3 who had fixed and dilated pupils. Cooper et al., [10] reported that decompressive craniectomy in patients with severe TBI and bilateral non-reactive pupils were associated with poor outcomes and death. Decompressive craniectomy has been avoided in patients with the most severe injuries (GCS score of 3 or 4) owing to the very poor outcomes and functional recoveries reported previously [11]. The two cases presented here demonstrate that decompressive craniectomy can be performed in the management of patients with GCS scores of 3 or 4, with good neurological outcomes and good functional recoveries. Informed consent was obtained from both patients.

### OPEN ACCESS

#### \*Correspondence:

Afif AFIF, Department of Neurosurgery and Anatomy, INSERM U 1028, Pain center, Pierre Wertheimer Hospital, Hospices Civils de Lyon, Lyon 1 University, France,  
E-mail: [afif\\_acc@hotmail.com](mailto:afif_acc@hotmail.com)

Received Date: 30 May 2019

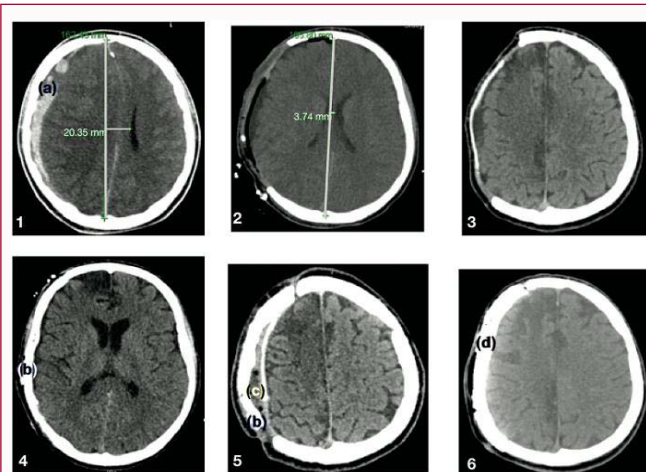
Accepted Date: 25 Jun 2019

Published Date: 03 Jul 2019

#### Citation:

Afif AFIF. Decompressive Craniectomy Following Severe Traumatic Brain Injury with an Initial Glasgow Coma Scale Score of 3 or 4. *Clin Surg*. 2019; 4: 2503.

**Copyright** © 2019 Afif AFIF. This is an open access article distributed under the Creative Commons Attribution License, which permits unrestricted use, distribution, and reproduction in any medium, provided the original work is properly cited.



**Figure 1:** Cerebral CT-scan of the first patient. 1) Initial CT-scan, (a) acute Subdural Hematoma (SDH); 2 and 3) Postoperative CT-scan; 4) Postoperative replace of the cranial flap (b); 5) CT-scan shows the cranial flap infection: (c) extradural collection, (b) cranial flap infected; 6) Cranial flap was replaced by artificial flap (d).

## Case Presentations

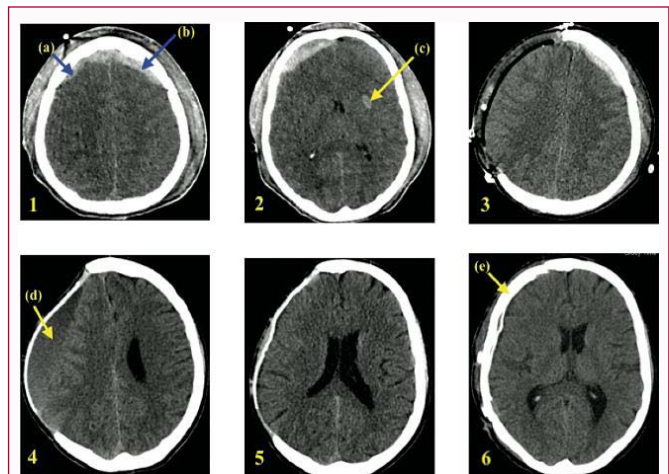
### Case 1

A 20-year-old man (S.M.) suffered severe TBI following a blow to the head with a cane. The clinical evaluation by emergency physicians before intubation was a GCS score of 4 with decerebrate response to stimulations. Soon afterwards, clinical aggravation led to a GCS of 3 and bilaterally dilated unreactive pupils, no blood toxic and alcoholism were found. The patient was intubated and sedated by emergency physicians before arrival at the hospital. Initial vital signs were systolic blood pressure of 100 mmHg, pulse of 45 beats per min, before intubation oxygen saturation of 99% and body temperature of 37.3°C. Initial blood analyses were glucose of 6.5 mmol/L, serum sodium of 137 mmol/L, and serum potassium of 3.5 mmol/L. After intubation oxygen saturation was 100%. A brain CT scan performed in the hospital's emergency department showed right frontal fracture, bifrontal hematoma contusion, a fronto-temporo-parietal acute Subdural Hematoma (SDH) with a thickness of 14 mm on the right side, traumatic subarachnoid hemorrhage, with 20 mm of midline shift to the left side, diffuse brain edema with effacement of adjacent cortical sulci and basal cisterns, and start of engagement of the cerebellar tonsils (Figure 1.1). Intracranial Doppler echocardiography showed a large decrease in blood flow on the right side of the brain. The surgical indication was proposed and the patient was transported to the operating room and operated 4 h after the assault and 30 min after the neurological hospital admission. The patient underwent a wide right fronto-temporo-parietal decompressive craniectomy and right SDH evacuation and wide duroplasty (with a Gore-tex graft) (Figures 1.2 and 1.3). After the operation, immediate regression of the bilateral pupil dilation was noted, and the patient was transferred to the Intensive Care Unit (ICU). A follow-up brain CT scan, 8 hours after the operation, showed the disappearance of the right acute SDH, reduction of the edema, and stability of the brain contusion (Figures 1.2 and 1.3). Sedation was stopped 36 h after of the surgery, and extubation was performed 12 days after the operation. 36 days after the operation, the patient was transferred to the neurosurgery department, with a GCS score of 15, partial quadriplegia and spasticity that was more pronounced on the left side. The patient was then transferred to a rehabilitation department. Three months

later, the patient showed good recovery of the muscular force in all four limbs, and in relation to memory and intellectual capacity (the patient was able to walk unaided, to write a letter, and to pose and answer questions). Replacement of the cranial flap was performed 4 months after the initial operation (Figure 1.4). Three weeks later, the cranial flap became infected with *Staphylococcus aureus*, and a brain CT scan showed the collection of pus in the extradural space and flap fragmentation (Figure 1.5). The patient therefore underwent a further operation to remove the infected flap, and treatment with antibiotics was continued for 6 weeks. The removed cranial flap was replaced a few months later by an artificial flap (Figure 1.6). A follow-up 31 months after the operation showed an Extended Glasgow Outcome Scale (EGOS) score of 8 and a very good functional recovery [12].

### Case 2

A 20-year-old man (P.K.) presented with severe TBI following an automobile accident, the clinical evaluation by emergency physicians before intubation was a GCS score of 4 with iso-reactive pupils, and was found to have blood alcohol of 1.2 g/L, no blood toxic found. Initial vital signs were blood pressure of 132/64 mmHg, pulse 90 beats per min, before intubation oxygen saturation of 100% and body temperature of 37.6°C. Initial blood analysis were glucose of 6 mmol/L, serum sodium of 141 mmol/L, serum potassium of 3.7 mmol/L and measured serum osmolality of 279 mosm/kg. The patient was intubated and sedated by emergency physicians before arrival at the hospital. After intubation oxygen saturation was 100%. A brain CT scan was performed in the emergency department, and showed bilateral fronto-temporal fracture, diffuse brain hematoma contusion, traumatic subarachnoid hemorrhage, right extradural hematoma and bilateral fronto-temporo-parietal acute SDH that was more pronounced on the right side (Figures 2.1 and 2.2). No midline shift was reported. X-rays showed a right clavicle fracture. A transcranial Doppler echocardiogram showed a decrease in blood flow especially on the right side. The patient was transported to the operating room and operated 7 h after the accident and 2 h after the neurological hospital admission. The patient underwent a wide right fronto-temporo-parietal decompressive craniectomy, right frontal extradural hematoma evacuation and right SDH evacuation and wide duroplasty (with a Gore-tex graft) (Figure 2.3). After the operation,



**Figure 2:** Cerebral CT-scan of the second patient. 1) Initial CT-scan. (a) Extradural Hematoma (EDH), (b) acute Subdural Hematoma (SDH); 2) Intra capsular hematoma contusion (c); 3) Postoperative (decompressive craniectomy) CT-Scan; 4) CT-scan, three months postoperative, shows a right chronic hematoma (d); 5) CT-Scan post chronic subdural hematoma evacuation; 6) CT-scan, post replace of the cranial flap (e).

the patient was transferred to the hospital's ICU.

A follow-up brain CT scan, 14 h after the operation, showed disappearance of both the right acute SDH and right acute extradural hematoma, a reduction of the edema, and stability of the brain contusion. The extubation was performed 9 days after the operation. A *Staphylococcal* pneumonia was treated with antibiotics in the ICU. The patient was transferred to the neurosurgery department 24 days after the operation, with aphasia, hypotonic voice, kinetic hypotonia, a GCS score of 11 and right central facial paralysis. One week later, the patient was transferred to a rehabilitation department, with a GCS score of 15. Post repeated falls, a follow-up brain CT scan was carried out 3 months after the operation. This showed a right chronic SDH (Figure 2.4), and therefore evacuation of this hematoma was performed. A follow-up brain CT scan 1 month later showed the disappearance of the right chronic SDH (Figure 2.5). Replacement of the cranial flap was performed 7 months after the initial operation, without complications (Figure 2.6). The patient showed good recovery of the movement of the four limbs and of the right side of the face, and in terms of intellectual capacity. A follow-up 26 months after the operation showed the disappearance of aphasia and right central facial paralysis, and an EGOS score of 8 with a good functional recovery.

## Discussion

Decompressive craniectomy is used in the management of patients who suffer from severe TBI. Several studies report good outcomes and reduced mortality when decompressive craniectomy is performed early following TBI [3-5]. However, previous studies have reported that decompressive craniectomy results in good long-term neurological outcomes only in patients with an initial GCS score of >5 [13]. Other studies have demonstrated poor clinical outcomes (very high morbidity and mortality rates) for patients who have undergone decompressive craniectomy who had poor initial GCS scores ( $\leq 8$ ) [7,8]. Tien et al., [11] reported that the mortality rate was 100% in patients with a GCS score of 3 and with bilaterally unreactive pupils. Severe TBI with a GCS score of 3 or 4 has been considered an extreme challenge in terms of both neurosurgery and intensive care for both child and adult patients. Therefore, surgical treatment by decompressive craniectomy has often been avoided owing to the very poor outcomes and low chance of functional recovery that have been reported [11]. Our cases series demonstrates that surgical treatment with a wide decompressive craniectomy, hematoma evacuation (if present) and a wide duroplasty can be performed and can be beneficial (after 4 h or 7 h in the cases presented here), in patients with severe TBI with a GCS score of <5. In contrast with a previous study, good neurological outcomes were obtained (at follow-up at 24 and 19 months for case 1 and 2, respectively) in these patients with a GCS score of 3, a midline shift exceeding 20 mm and bilaterally dilated unreactive pupils (in the first case) [7]. At follow-up, EGOS scores were 8, with a good functional recovery. The good neurological outcomes in the two cases raise the question of the reliability of the GCS in the surgical indication decision for severe TBI with a GCS score of <5, particularly in young patients (less than 40 years). A wide unilateral fronto-temporo-parietal decompressive craniectomy, and perhaps also hematoma evacuation if necessary, can be used to rapidly reduce intracranial edema and pressure, and to improve the blood flow in the brain. This is in contrast to previous studies that reported no differences in the clinical outcomes of those undergoing immediate decompressive craniectomy and those in

whom decompressive craniectomy was delayed [8,14,15]. Our case series seems to suggest that the factors that have a crucial role in good long-term neurological outcomes of severe TBI treated with surgery are: 1) The early performance after injury of presurgical and surgical procedures; 2) Adequately wide fronto-temporo-parietal decompressive craniectomy, hematoma evacuation (if a hematoma is present) and a wide duroplasty; 3) Good experience of care in a neurological intensive care unit.

## Conclusion

The data in our case series demonstrate that surgical treatment by adequately wide fronto-temporo-parietal decompressive craniectomy, hematoma evacuation and a wide duroplasty can be beneficial in patients with severe TBI with a GCS score of 3 or 4. An appropriate and rapid decision regarding surgical indication standard of care in the ICU and good physical rehabilitation may play a very important part in improving long-term neurological outcomes. The results may enable neurosurgeons and ICUs to improve management procedures for, and hence neurological outcomes in severe TBI. However, further and larger studies are required to address the inclusion criteria of the surgery indication, and to better understand long-term outcomes of severe TBI treated with decompressive craniectomy.

## Consent for Publication

Written informed consent was obtained from the patients for publication of this case report and any accompanying images. A copy of the written consent is available for review by the Editor-in-Chief of this journal.

## Acknowledgment

The author would like to thank the emergency team, the operating team and the intensive care unit of the neurological hospital, and the rehabilitation services in Lyon (France) and in Bale (Switzerland). They have played a very important part in these successful cases.

## References

1. Ransohoff J, Benjamin MV, Gage EL Jr, Epstein F. Hemicraniectomy in the management of acute subdural hematoma. *J Neurosurg.* 1971;34(1):70-6.
2. Kjellberg RN, Prieto A Jr. Bifrontal decompressive craniotomy for massive cerebral edema. *J Neuro-surg.* 1971;34(4):488-93.
3. Venes JL, Collins WF. Bifrontal decompressive craniectomy in the management of head trauma. *J Neurosurg.* 1975;42(4):429-33.
4. Aarabi B, Hesdorffer DC, Ahn ES, Aresco C, Scalea TM, Eisenberg HM. Outcome following decompressive craniectomy for malignant swelling due to severe head injury. *J Neurosurg.* 2006;104(4):469-79.
5. Qiu W, Guo C, Shen H, Chen K, Wen L, Huang H, et al. Effects of unilateral decompressive craniectomy on patients with unilateral acute post-traumatic brain swelling after severe traumatic brain injury. *Crit Care.* 2009;13(6):R185.
6. Chibbaro S, Di Rocco F, Mirone G, Fricia M, Makiese O, Di Emidio P, et al. Decompressive craniectomy and early cranioplasty for the management of severe head injury: a prospective multi-center study on 147 patients. *World Neurosurg.* 2010;75(3-4):558-62.
7. Ban SP, Son YJ, Yang HJ, Chung YS, Lee SH, Han DH. Analysis of Complications Following Decompressive Craniectomy for Traumatic Brain Injury. *J Korean Neurosurg Soc.* 2010;48(3):244-50.
8. Grindlinger GA, Skavdahl DH, Ecker RD, Sanborn MR. Decompressive craniectomy for severe traumatic brain injury: clinical study, literature review and meta-analysis. *SpringerPlus.* 2016;5(1):1605.

9. Tien HC, Cunha JR, Wu SN, Chughtai T, Tremblay LN, Brenneman FD, et al. Do trauma patients with a Glasgow Coma Scale score of 3 and bilateral fixed and dilated pupils have any chance of survival? *J Trauma*. 2006;60(2):274-8.
10. Cooper DJ, Rosenfeld JV, Murray L, Arabi YM, Davies AR, D'Urso P, et al. Decompressive craniectomy in diffuse traumatic brain injury. *N Engl J Med*. 2011;364(16):1493-502.
11. Fulkerson DH, White IK, Rees JM, Baumanis MM, Smith JL, Ackerman LL, et al. Analysis of long-term (median 10.5 years) outcomes in children presenting with traumatic brain injury and an initial Glasgow Coma Scale score of 3 or 4. *J Neurosurg Pediatr*. 2015;16(4):410-9.
12. Wilson JT, Pettigrew LE, Teasdale GM. Structured interviews for the Glasgow Outcome Scale and the extended Glasgow Outcome Scale: guidelines for their use. *J Neurotrauma*. 1998;15(8):573-85.
13. Gouello G, Hamel O, Aschnoune K, Bord E, Robert R, Buffenoir K. Study of the long-term results of de-compressive craniectomy after severe traumatic brain injury base on a series of 60 consecutive cases. *Sci World J*. 2014;2014:1-10.
14. Zhang K, Jiang W, Ma T, Wu H. Comparison of early and late decompressive craniectomy on the long-term outcome in patients with moderate and severe traumatic brain injury: a meta-analysis. *Br J Neurosurg*. 2016;30(2):251-7.
15. Rossi-Mossuti F, Fisch U, Schoettker P, Gugliotta M, Morard M, Schucht P, et al. Surgical Treatment of Severe Traumatic Brain Injury in Switzerland: Results from a Multicenter Study. *J Neurol Surg A Cent Eur Neurosurg*. 2016;77(1):36-45.