



Debranching Technique Combined with Renal Transplantation for the Treatment of Thoracoabdominal Aortic Aneurysm

Kun Ye¹, Min Xu² and Shengyun Wan^{1*}

¹Department of Vascular Surgery, 2nd Affiliated Hospital of Anhui Medical University, China

²Department of Anesthesiology, Anhui Province Hospital, China

Abstract

Thoracoabdominal aortic aneurysms are rarely treated with the debranching technique and renal autotransplantation. We report the case of a 44-year-old male with a ruptured thoracoabdominal aortic aneurysm involving the celiac artery, left renal artery and superior mesenteric artery. A hybrid operation was performed, first reconstructing the superior mesenteric artery and the right renal artery and then completely excluding the thoracoabdominal aortic aneurysm with an endovascular approach. This hybrid operation is a cost-effective and safe option for treating thoracoabdominal aortic aneurysms, with good short-term results.

Case Presentation

The patient was a 44-year-old male without a history of hypertension who was admitted to the hospital with thoracic and back pain for two months. No pulsatile mass was discovered in the abdomen, and there was no pain or rebound pain in the whole abdomen. Bowel sounds were not hyperactive after physical examination. A Computed Tomography Angiogram (CTA) showed that a thoracoabdominal aortic aneurysm involving the celiac artery, left renal artery and superior mesenteric artery had ruptured on the level of the T12-L1 centrum (Figure 1). There was also severe stenosis at the celiac trunk and slight stenosis at the beginning of the superior mesenteric artery and left renal artery. The right renal artery was divided into two branches shortly after diverting from the abdominal aorta, and both were fine. The patient was diagnosed with type IV Crawford thoracoabdominal aortic aneurysm at this point. A multidisciplinary discussion was conducted on the following topics: vascular surgery, general surgery and urologic surgery. Considering that open surgery is traumatic and completely endovascular surgery is expensive, we decided to perform a staging operation after discussion.

Firstly, we made a superior mesenteric artery and left common iliac artery bypass using a straight artificial blood vessel with rings (Terumo Corporation) to ensure the intestinal blood supply, meanwhile we performed right renal autotransplantation to ensure the renal blood supply under general anesthesia. We observed that the right renal artery and vein were both divided into two branches not far away from their starting point. The maximum diameter of the right renal artery was 4 mm, so it was very difficult to anastomose the vessels; we decided to transfer the right renal artery to the right fossa iliaca finally.

The Kocher technique was used to turn the ascending colon and pancreatic head to the left to clearly reveal the entire right renal artery and vein. We cut off the right renal artery and vein from the root and made Right Renal Artery (RRA) and Right Internal Iliac Artery (RIIA) anastomoses, Right Renal Vein (RRV) and Right Common Iliac Vein (RCIV) anastomoses. The Treitz ligament was then cut off, and the ascending duodenal portion was turned to the right. We also exposed the superior mesenteric artery at the root of the mesenteriolum. We made a Superior Mesenteric Artery (SMA)-Left Common Iliac Artery (LCIA) bypass, and we ligated the root of the SMA in case of a type II endoleak (Figure 2). All anastomoses were performed by end-to-side anastomosis.

One week later, we performed a secondary Endovascular Aortic Repair (EVAR). The hepatic and splenic arteries were well visualized by angiography via the patent artificial blood vessel; we thus preserved the inferior mesenteric artery and excluded the celiac artery, SMA and left renal artery by placing a covered stent.

OPEN ACCESS

*Correspondence:

Shengyun Wan, Department of Vascular Surgery, The 2nd Affiliated Hospital of Anhui Medical University, No. 678 Furong Road, Hefei City, Anhui Province, 230601, China, Tel: +86-0551-63869593, +86-13956013063; E-mail: wshy63@sina.com

Received Date: 18 Jun 2018

Accepted Date: 11 Jul 2018

Published Date: 14 Jul 2018

Citation:

Kun Ye, Xu M, Wan S. Debranching Technique Combined with Renal Transplantation for the Treatment of Thoracoabdominal Aortic Aneurysm. Clin Surg. 2018; 3: 2023.

Copyright © 2018 Shengyun Wan. This is an open access article distributed under the Creative Commons Attribution License, which permits unrestricted use, distribution, and reproduction in any medium, provided the original work is properly cited.

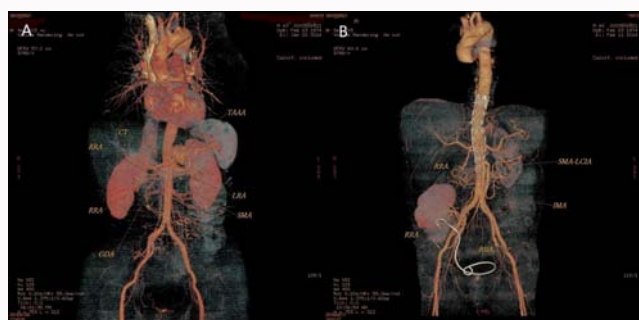

Figure 1: (A) Preoperative CT scan of the thoracoabdominal aortic aneurysm. (B) CT scan performed 3 days after the operation revealing good exclusion of the thoracoabdominal aortic aneurysm.

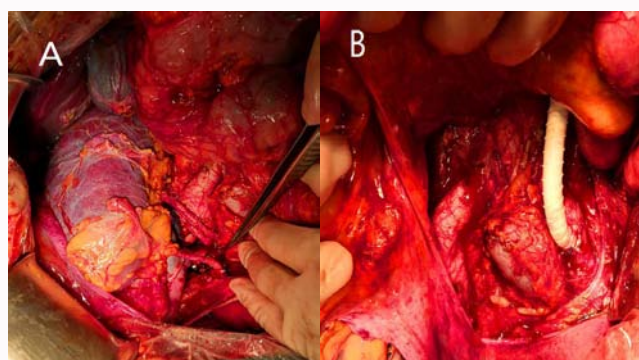


Figure 2: (A) Intraoperative photo showing the iliac-renal arterial anastomosis. (B) Intraoperative photo showing an artificial blood vessel anastomosed to the left common iliac artery.

The postoperative CTA showed that the aortic stent was unobstructed at the level of the T10-L3 centrum, and arteriography showed that the visceral arteries developed well, except for the left renal artery; however, the left renal artery had a good blood supply because of the inferior mesenteric artery. The patient experienced a transient rise in alanine transaminase, impairment of renal function, edema of the lower limbs, nausea and vomiting after the operation. Alanine transaminase levels decreased and renal function recovered 1 week after the first operation; the other symptoms disappeared 1 week after the second operation. The patient was discharged with no abdominal or retroperitoneal bleeding, urinary fistula, uronephrosis, multiple organ failure or other serious complications. The CTA at 1 month after surgery showed that the aortic stent was unobstructed and that the visceral arteries developed well (Figure 3).

Discussion

Thoracoabdominal aortic aneurysm refers to an aortic aneurysm that involves both the thoracic and abdominal aortic arteries as well as aneurysms that involve the abdominal aortic segment above the renal artery. According to previous reports, the mortality rate is as high as 76% among patients with thoracoabdominal aortic aneurysms who remain untreated after two years. The main cause of death is rupture of the aneurysm [1]. To date, there have been several reports on the debranching technique combined with renal transplantation for the treatment of thoracoabdominal aortic aneurysm. It was previously reported that among 1914 cases of thoracic abdominal aneurysm repaired by Dr. Coselli, arterial media degeneration accounted for 73.4%, aortic dissection accounted for 26.6%, Marfan syndrome accounted for 6.8%, infection accounted for 0.6%, aorto-arteritis

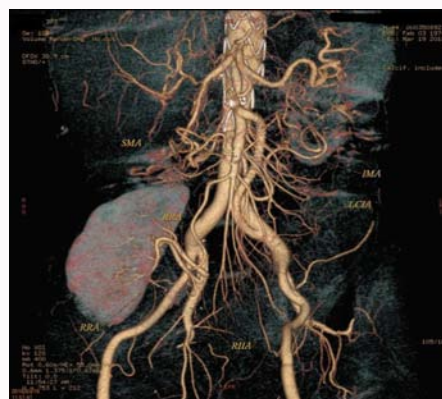

Figure 3: CT scan performed 1 month after the operation revealing that extensive collateral circulation was established.

accounted for 0.4%, and Ehlers-Danlos syndrome accounted for only 0.1% of the cases [2]. At present, there are three treatment methods for thoracoabdominal aortic aneurysms: 1) Open surgery, which requires a thoracoabdominal incision as well as extracorporeal circulation for visceral artery perfusion. It also requires good cardiopulmonary function but has a high mortality rate. The main complications of open surgery include paraplegia, renal failure and cardiopulmonary-related complications [3,4]. Patients with type II Crawford aneurysms have a mortality rate of 10% to 42% and paraplegia incidence of 7% to 32%, which are significantly higher than those in patients with type III and type IV thoracoabdominal aortic aneurysm [5]. 2) Completely endovascular treatment, which requires technologies such as fenestrated stent-graft technology, multiple side branch stent grafts, and “chimney”, “sandwich” or “octopus” technologies that have advantages of reduced trauma and low mortality rates. However, completely endovascular treatment requires customized approaches, advanced technology and high cost [6,7]. In addition, according to the literature, there is a complication of occlusion between the branches and the main stent during long-term follow-up [8,9]. Moreover, the efficacy of this treatment modality remains to be confirmed. 3) Reconstruction of visceral arteries combined with endovascular treatment, which is a hybrid operation with a definite effect, reduced trauma and low medical costs; thus, it is a cost-effective treatment option. It was found that a proper anatomical approach and a proper debranching strategy are the keys to success in this case. We accumulated more experience in the treatment of thoracoabdominal aortic aneurysm, such as realizing that the SMA Root can be better exposed when the posterior peritoneum at the pancreas edge is opened and the pancreas is lifted up. By this method the position of the anastomosis can be raised. We also avoided type I endoleak by sacrificing the involved left renal artery and preserved the inferior mesenteric artery in order to maximize the protection of the visceral blood supply. We then cut the renal arteries and veins from the root for ease of exposure and a more convenient vascular anastomosis with Kocher's technique.

References

1. Crawford ES, DeNatale RW. Thoracoabdominal aortic aneurysm: observations regarding the natural course of the disease. *J Vasc Surg.* 1986;3(4):578-82.
2. Coselli JS, Bozinovski J, LeMaire SA. Open surgical repair of 2286 thoracoabdominal aortic aneurysms. *Ann Thorac Surg.* 2007;83(2):S862-4.
3. Black SA, Wolfe JH, Clark M, Hamady M, Cheshire NJ, Jenkins MP.

- Complex thoracoabdominal aortic aneurysms: endovascular exclusion with visceral revascularization. *J Vasc Surg.* 2006;43(6):1081-9.
4. Conrad MF, Cambria RP. Contemporary management of descending thoracic and thoracoabdominal aortic aneurysms: endovascular versus open. *Circulation.* 2008;117(6):841-52.
 5. Conrad MF, Crawford RS, Davison JK, Cambria RP. Thoracoabdominal aneurysm repair: a 20-year perspective. *Ann Thorac Surg.* 2007;83(2):S856-61.
 6. Greenberg RK, Lytle B. Endovascular repair of thoracoabdominal aneurysms. *Circulation.* 2008;117(17):2288-96.
 7. Chuter TA, Rapp JH, Hiramoto JS, Schneider DB, Howell B, Reilly LM. Endovascular treatment of thoracoabdominal aortic aneurysms. *J Vasc Surg.* 2008;47(1):6-16.
 8. Greenberg R, Eagleton M, Mastracci T. Branched endografts for thoracoabdominal aneurysms. *J Thorac Cardiovasc Surg.* 2010;140(6):S171-8.
 9. Heyer K, Tang GL, Resnick SA, Eskandari MK. Hybrid thoracoabdominal aortic aneurysm repair: visceral revascularization combined with endovascular abdominal and thoracic aneurysm repair. *J Vasc Interv Radiol.* 2010;21(5):735-7.