



Current Surgical Management of Giant Congenital Melanocytic Nevi of the Upper Extremity

Fang Wang, Huifeng Song, Minghuo Xu*, Quanwen Gao, Baoguo Chen, Shuai Chen, Jiang Wu and Jue Wang

Department of Burns Surgery, The Forth Medical Center of People's Liberation Army General Hospital, China

Abstract

Congenital Melanocytic Nevi (CMN) is advised excised because of the possibility of it degenerating into a malignant or for aesthetic concerns. With the progress of the times and the development of science and technology, treating giant congenital melanocytic nevi of the upper extremity requires comprehensive measures. A 22-old-girl with giant congenital melanocytic nevi from the left shoulder joint to the elbow joint in our hospital, we make a clinical route for her treatment. There were 5 stages to the surgical procedure. First stage, the endoscopic placement of tissue expander was inserted into the subcutaneous pocket; second stage, partial excision of the nevus and direct closure of the defect. Third stage, the expander was removed, lesions or scars were excised, and the wound of the upper extremity was placed into the pocket to delay healing. Hyperbaric Oxygen (HBO₂) therapy was initiated for post-reconstructive flap; forth stage, the residual lesion was excised and the pedicle was removed, the pedicle flap was then unfolded to resurface the wound, HBO₂ therapy was initiated as the second stage; fifth stage, hypertrophic scar of the upper extremity was treated with ultra pulse CO₂ fractional laser. Optimal aesthetic and functional result was obtained in the right upper extremity.

Keywords: Upper extremities; Reconstruction; Flap; Endoscopic assisted; Tissue expansion; Hyperbaric oxygen; Ultra pulse CO₂ fractional laser

Introduction

Congenital Melanocytic Nevi (CMN) is hematomas compromising of a surplus of nevocytes, penetrating each layer of the skin. The definition of giant congenital melanocytic nevi is a lesion affecting 2% of TBSA in newborns and toddlers, or a diameter larger than 20 cm in older children and teenagers [1,2]. Because of the possibility of it degenerating into a malignant or for aesthetic concerns [4-6]. Various approaches are used for the treatment of nevi including serial excision, skin grafting, and tissue expansion, laser therapy and so on, with the development of science and technology, endoscopic assisted, hyperbaric oxygen, and ultra-pulse CO₂ fractional laser are used in the treatment of the congenital melanocytic nevi. Here we describe a case of a giant circumferential nevus from the left shoulder joint to the elbow joint to present the surgical process with new therapies.

Case Presentation

The patient was a 22-year-old girl presenting in 2017 with a giant circumferential nevus from the left shoulder joint to the elbow joint. The hyper-pigmented and hairy lesion occupied approximately 3% of the total body surface area (Figure 1).

Surgery

A clinical route of comprehensive measures for the treatment of giant congenital melanocytic nevi from the left shoulder joint to the elbow joint was made. There were 5 stages to the surgical procedure. First stage: Endoscopic-assisted tissue expander insertion into the back region of the torso. Two expanders (600 cc × 2) were inserted in the appropriate position of the back of the patient where the upper limb lesion was against, using the appropriate size expander, slightly longer than the lesion length. The inflation process was usually initiated at 12 days after expander insertion and the injections were repeated on a 7 day basis and continued for a total of 4 moths (Figure 2). Second stage: 1 month later, the central area of the congenital melanocytic nevi is excised and the wound is direct closed in the stage (Figure 3). Third stage; about 3 months later, tissue expander removal from pocket, circumferential excision of nevus. Removal of the expander was always the first step before

OPEN ACCESS

*Correspondence:

Minghuo Xu, Department of Burns Surgery, The Forth Medical Center of People's Liberation Army General Hospital, China, Tel: 010-66867304; E-mail: wangfang108719@163.com

Received Date: 29 Oct 2019

Accepted Date: 14 Dec 2019

Published Date: 18 Dec 2019

Citation:

Wang F, Song H, Xu M, Gao Q, Chen B, Chen S, et al. Current Surgical Management of Giant Congenital Melanocytic Nevi of the Upper Extremity. *Clin Surg.* 2019; 4: 2688.

Copyright © 2019 Minghuo Xu. This is an open access article distributed under the Creative Commons Attribution License, which permits unrestricted use, distribution, and reproduction in any medium, provided the original work is properly cited.

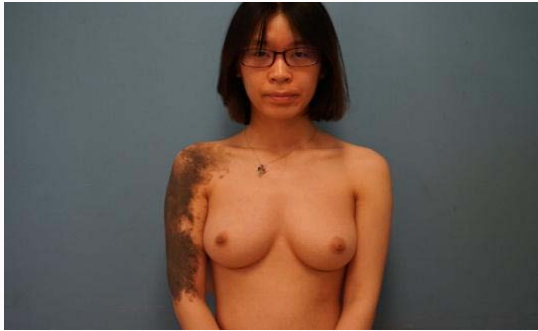

Figure 1: The patient was a 22 year-old girl presenting in 2017 with a giant circumferential nevus from the left shoulder joint to the elbow joint.

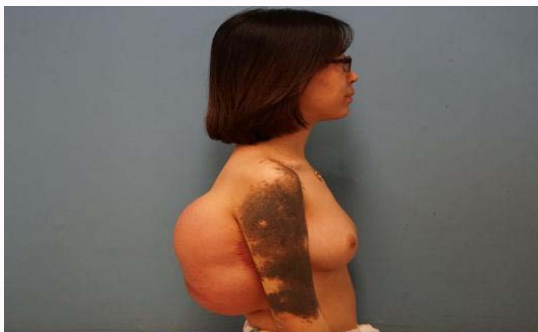

Figure 2: The 2 expanders were inserted into the subcutaneous pocket.

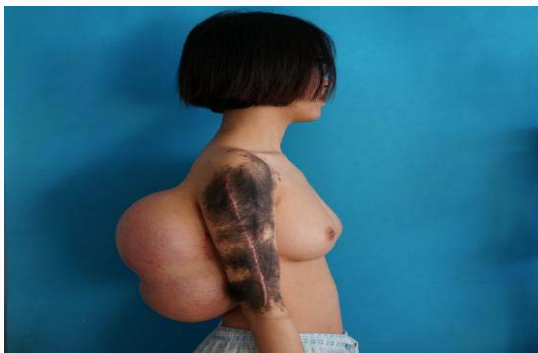


Figure 3: Partial excision for the large congenital melanocytic nevus.

the nevus excision. The expanded pedicle flap was then created for a tension-free donor-site closure before nevus removal. The width of the flap was designed on the basis of the length of the nevus, and the length of the flap was arm circumference. The expanded flap with a random pattern was at the width-to-length ratio of more than 1:3. The flap pedicles were placed on the side of the back when the flaps were used to resurface the posterior extremity. Three days after the surgery, the patient was treated with HBO₂ once a day for 5 days. The each HBO₂ treatment is at 2.46 atmospheres absolute (45 feet of sea water) for 90 min (Figure 4). Forth stage; flap separation and closure of skin around the extremity. The pedicle flap was separated from the trunk at 20 days after transfer. Then the patient was treated with HBO₂ as before (Figure 5). Fifth stage; the patient was treated with Ultra pulse CO₂ (carbon dioxide) fractional laser 3 times at 3-month intervals. Post-treatment wound utilizes moist exposed burn ointment. The skin in the surgical area was soft in the texture with flat scars (Figure 6). The patient was satisfied with the results of the procedures.

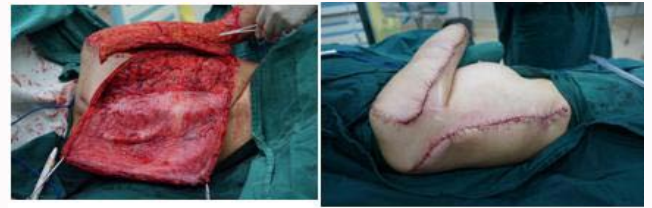

Figure 4: The expanded flaps were transferred to reconstruct the defect resulting from nevus removal.

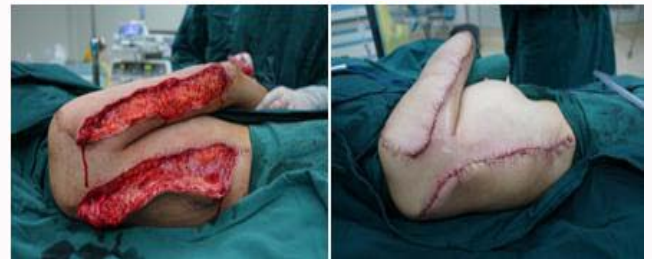

Figure 5: The pedicle flap was separated from the trunk and closure of skin around the extremity.

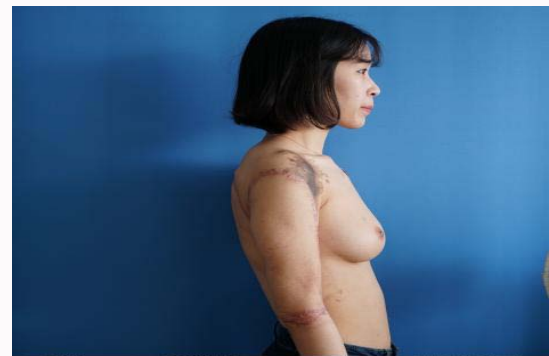

Figure 6: The hypertrophic scar of the upper extremity was treated with ultra-pulse CO₂ fractional laser.

Discussion

Techniques to remove Congenital Melanocytic Nevi (CMN) include serial excision, skin grafting, and tissue expansion, laser therapy and so on. With the development of science and technology, endoscopic assisted, hyperbaric oxygen, and ultra pulse CO₂ fractional laser are used in the treatment of the congenital melanocytic nevi [7-17], so treating giant congenital melanocytic nevi of the upper extremity requires careful planning and often multiple stages. The aim of this study was to present the surgical process and preferred technique for treating such upper extremity nevi. Tissue expansion has emerged as the primary treatment of giant congenital nevi because it enables the body to produce extra skin with excellent texture, better color match, less severe donor-site deformity and repeated usage of an expanding donor-site. However, the technique discussed does have some limitations. The traditional approach in placement of a tissue expander reconstruction is challenging due to high complication rates. In Recent years, endoscopy has shown promise in reconstructive surgeries using tissue expander placement [7-11]. We use an endoscopic approach in placement of tissue expanders. With the help of the endoscopy, first, the surgery has improved visualization inside the pocket area during the operation allowing good hemostasis and homogenous dissection of the

expander pocket. Second, the smaller access incision in a remote site from the expander pocket resulted in earlier initiation of the tissue expansion and reduced time to achieve full expansion. At the same time, we combined partial nevus excision with skin expansion in the surgery process, which is a good method for rapid treatment of giant congenital melanocytic nevi it shortens the treatment time effectively. During the fourth stage and the fifth stage, we used hyperbaric oxygen treatments. A number of studies have shown that HBO₂ treatment can increased the pressure, answered the oxygen demand of the skin flap, and promoted oxygen diffusing to anoxic tissue, improved the micro-circulation of the skin flaps, preservation of tissue viability in ischemic areas and increased the blood flow of skin flaps. Studies show the efficacy of HBO₂ on enhancement of flap and graft survival in many experimental and clinical situations [12-14]. So hyperbaric oxygen therapy is a routine treatment in our flap surgery. In recent years, the fractional CO₂ laser therapy has become very popular for treating scars [15-17]. Fractional CO₂ lasers produce a matrix-shaped micro-thermal injury, stimulating the skin to initiate the basic repair process which results in skin regeneration and repair, with effects in both the epidermis and in the dermis. Ultra pulse CO₂ fractional laser for treatment of scars are safe, effective, and feasible with fewer complications. In the fifth stage, we used the fractional CO₂ laser; the skin in the surgical area was soft in the texture with flat scars.

Conclusion

Treating giant congenital melanocytic nevi of the upper extremity requires comprehensive measures. On the other hand, devise a clinical route for giant congenital melanocytic nevi of the upper extremity removal.

References

- Lorentzen M, Pers M, Bretteville-Jensen G. The incidence of malignant transformation in giant pigmented nevi. *Scand J Plast Reconstr Surg.* 1977;11(12):163-7.
- Quaba AA, Wallace AF. The incidence of malignant melanoma (0 to 15 years of age) arising in "large" congenital nevocellular nevi. *Plast Reconstr Surg.* 1986;78(2):174-81.
- Yovino J, Thaller S. Potential for Development of Malignant Melanoma with Congenital Melanocytic Nevi. *J Craniofac Surg.* 2005;16(5):871-3.
- Arneja JS, Gosain AK. Giant congenital melanocytic nevi. *Plast Reconstr Surg.* 2009;124(2):1-13.
- Pearson GD, Goodman M, Sadove AM. Congenital nevus: the Indiana University's approach to treatment. *J Craniofac Surg.* 2005;16(5):915-20.
- Watt AJ, Kotsis SV, Chung KC. Risk of melanoma arising in large congenital melanocytic nevi: a systematic review. *Plast Reconstr Surg.* 2004;113(7):1968-74.
- Elshaer WM, Enab AA, Elmanawi HM. Endoscopic tissue expansion placement in face and neck burn scar reconstruction. *Burns.* 2011;37(3):474-9.
- Toronto JD, Yu D, Cederna PS. Endoscopic versus Open Tissue-Expander Placement: is Less Invasive Better? *Plast Reconstr Surg.* 2007;119(3):894-906.
- Levi B, Brown DL, Cederna PS. A comparative analysis of tissue expander reconstruction of burned and unburned chest and breasts using endoscopic and open techniques. *Plast Reconstr Surg.* 2010;125(2):547-56.
- As'adi K, Salehi SH, Shoar S, Hashemian SJ, Moradi M. Endoscopic-Assisted Neck Tissue Expansion in Reconstruction of Facial Burn Injuries. *J Craniofac Surg.* 2014;25(2):455-9.
- As'adi K, Emami SA, Salehi SH, Shoar S. A Randomized Controlled Trial Comparing Endoscopic-Assisted Versus Open Neck Tissue Expander Placement in Reconstruction of Post-Burn Facial Scar Deformities. *Aesthetic Plast Surg.* 2016;40(4):1-9.
- Thom SR. Hyperbaric oxygen: its mechanisms and efficacy. *Plast Reconstr Surg.* 2011;127(1):131-41.
- Friedman HI, Fitzmaurice M, Lefavre JF, Vecchiolla T, Clarke D. An Evidence-Based Appraisal of the Use of Hyperbaric Oxygen on Flaps and Grafts. *Plast Reconstr Surg.* 2006;117(7):175-190.
- Feldmeier JJ. Hyperbaric oxygen 2003: indications and results: the Hyperbaric Oxygen Therapy Committee report. Kensington, Undersea and Hyperbaric Medical Society. 2003:101-7.
- Lei Y, Li SF, Yu YL, Tan J, Gold MH. Clinical efficacy of utilizing Ultra pulse CO₂, combined with fractional CO₂, laser for the treatment of hypertrophic scars in Asians-A prospective clinical evaluation. *J Cosmet Dermatol.* 2017;16(2):210-216.
- Manstein D, Herron GS, Sink RK, Tanner H, Anderson RR. Fractional photothermolysis: a new concept for cutaneous remodeling using microscopic patterns of thermal injury. *Laser Surg Med.* 2004;34(5):426-38.
- Gold MH, Biron JA. Combined superficial & deep fractional skin treatment for photo damaged skin-a prospective clinical trial. *Lasers Surg Med.* 2004;34(5):426-38.