



Correction of Inverted Breast Nipple by Using Serdev Suture

Munir Alam*, MBBS (KE), FRCS (Ire), FRCS (Ed), FCPS (Plastic Surgery), Int/European Board Certified Cosmetic Surgeon

Department of Plastic Surgery, Faisal Hospital, Faisalabad, Pakistan

Abstract

Background: Inverted breast nipples are classified into 3 grades according to severity of inversion. There are various procedures described for correction of all the grades. For grade II and III correction, the techniques like multiple deepithelialized dermal flaps have high complications rate and results are inconsistent. The diversity of procedures supports the lack of a consistently reliable method.

I present a minimal invasive parenchymal release under local anesthetic and a single purse string suture using “Serdev Suture” methodology with semi-elastic antimicrobial absorbable polycapromide thread “polycorn” which is slowly absorbable (1.5 to 2 years) that guaranties stable results and avoid the collapse of the nipple.

Purpose of Study: To evaluate the effectiveness of Serdev suture methodology for inverted nipple correction.

Setting: Dundrum Medical Cosmetic Clinic, Dublin 16, Ireland. Faisal Hospital, Peoples Colony, Faisalabad, Pakistan.

Material and Methods: Two years from March 2009 to Feb 2011 & one year from January 2016 to December 2016, totaling 3 years study period.

Total number of patients were 22 in this study of 3 years duration. Thirteen (59%) patients had one side and 9 (41%) patients had bilateral breast nipple correction.

Type of Study: Prospective cross sectional case analytic study.

Results: Thirteen patients had one side and 9 patients had bilateral breast nipple correction. Twenty one patients were female and one male. There were no late complications noted such as nipple ischemia, infection or re inversion etc. The satisfaction level achieved with this innovative technique for patient and surgeon by using visual analogue scoring system was in the range of 70% to 95%.

Conclusion: Therefore, I recommend this procedure for grade II and grade III inverted breast nipple correction because of its simplicity, reliable, quick, leave no visible scars and easy to learn.

Keywords: Breast; Nipple; Inverted; Serdev Suture

Introduction

Inverted breast nipples are congenital or acquired, and are classified by Han and Hong into 3 grades according to severity of inversion [1]. In grade I, the nipple is easily pulled out manually and maintains its projection quite well. The grade II nipples can be pulled out but cannot maintain projection and tend to go back again. In grade III, the nipple can hardly be pulled out manually [2]. The occurrence of inverted and flat nipples is not uncommon in the practice of newborn care. It was estimated by Alexander et al. [3] that about 10% of pregnant women have inverted or non-projectile nipples.

Most commonly patient present for inverted nipple correction for its unacceptable aesthetic appearance. In addition, its abnormal appearance may cause psychological distress.

Various methods to correct flat and inverted nipples with varying degrees of success and complications have been reported in the literature. Some of them were prenatal exercises like Hoffman’s exercise [4], nipple stimulation techniques [5], and postnatal use of the Niplette (Philips Avent, Andover, MA) [6] as well as using breast shells to make the nipple prominent for grade I nipple.

OPEN ACCESS

*Correspondence:

Munir Alam, Department of Plastic Surgery, Faisal Hospital, Independent Medical College, 46 University Town, Millat Road, Faisalabad, Pakistan, Tel: +92-3217711360;

E-mail: mrmuniralam@gmail.com

Received Date: 26 Aug 2019

Accepted Date: 19 Sep 2019

Published Date: 25 Sep 2019

Citation:

Alam M. Correction of Inverted Breast Nipple by Using Serdev Suture. Clin Surg. 2019; 4: 2590.

Copyright © 2019 Munir Alam. This is an open access article distributed under the Creative Commons Attribution License, which permits unrestricted use, distribution, and reproduction in any medium, provided the original work is properly cited.





TYPES OF NIPPLES		INTERPRETATION
	POINTED	NORMAL
	FLAT	INVERTED NIPPLE Grade -1 deformity
	INDENTED	INVERTED NIPPLE Grade -2 deformity
	TUCKED-IN	INVERTED NIPPLE Grade -3 deformity

Table 1: Classification of inverted breast nipple.



The grading system is useful for patient classification and analysis, systematic planning, and application of the proper surgical procedures Table 1. As the normal aesthetic appearance of the nipple is pointed. Grade II and grade III required surgical procedures for an aesthetical normal looking breast nipple (Table 1). Several different techniques have been developed and currently are in use for correction of the inverted nipple. The diversity of techniques indicates the lack of a good, sustainable, and durable solution for this quite common problem. The surgical techniques used for grade II and III nipple are multiple deepithelialized dermal flaps, areolar dermal flap [7] modified star flap [8], periductal dermofibrous flap [9], piercing method [10], antenna flap [11] parenchymal release of breast nipple, various suture techniques or combination of technique with inconsistent results and re inversion of the breast nipple sooner or later [7,12].

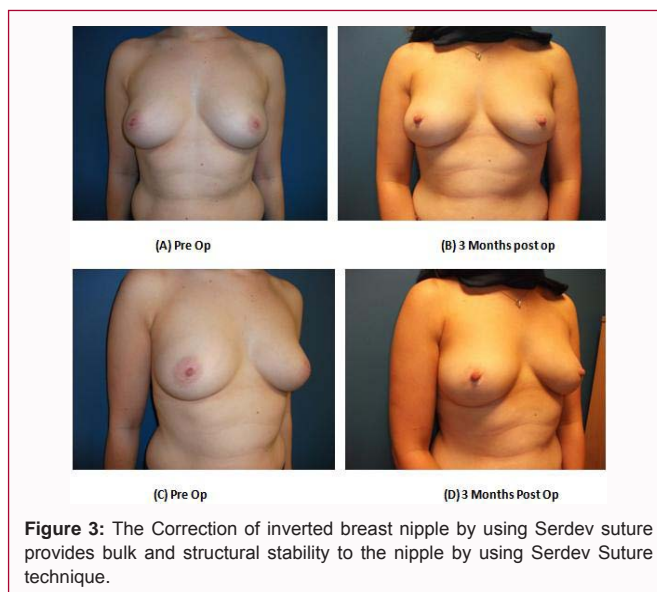
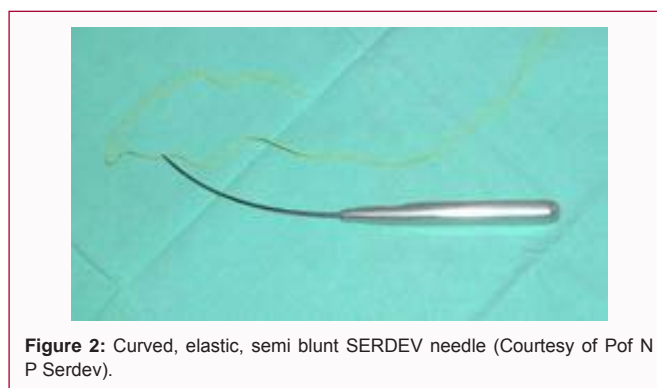
The researchers describe the technique of correcting inverted breast nipple with the use of especially designed Serdev Suture and Serdev instruments.

Material and Methods

The total number of patients were 22 in this study. Twenty one nipples were congenital and one patient had scarred flat nipple due to previous nipple sparing mastectomy. The age range from 21 years to 56 years with a mean age 34 ± 7 years. There were 21 (95%) female and one (5%) male patient. Thirteen (59%) patients had unilateral inverted breast nipple and nine (41%) patients had bilateral inverted breast nipple treated with Serdev Suture technique. The Serdev suture and instrument used for the correction of inverted breast nipple as shown in Figure 1 and 2.

The inclusion criteria were all the patients desired to have correction for inverted breast nipple of any age or gender.

The exclusion criteria include nipple discharge, lactating females,



breast cancer patients, certain medications with co morbid disease.

Results

There were no early or late complications reported such as infection, nipple ischemia, ulceration, and re-inversion etc. in this study for all the 22 patients with three months follow up period. The patient and surgeon satisfaction level achieved with this innovative technique were in the range of 70% to 95% by using visual analogue scoring system.

Discussion

Inverted nipple is a relatively common aesthetic problem presenting to a plastic surgeon. Along with the functional problems; recurrent inflammation/infection and an inability to nurse, most patients seek intervention because of the abnormal appearance. Many different surgical techniques have been described, suggesting that no one technique is universally successful. Most techniques employ, either individually or in combination.

The prevalence of inverted breast nipple is not that common, the report by Heung Sik Park et al. [13] reported the prevalence of 3.26% between the age of 19 and 26 years of age, the condition was bilateral in 86.79% and unilateral in 13.21%. Almost 32 surgical techniques have been proposed for correcting inverted nipples. Crestinu J [14] reported the large number of techniques accounted for considerable frequency of such malformations. Crestinu J [14] also describes the previous surgical techniques and the reason for failure of these

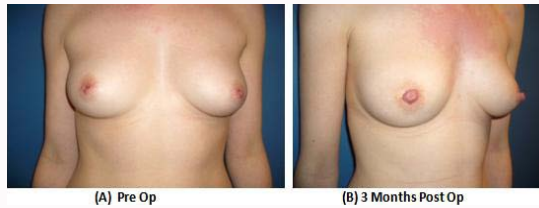


Figure 4: The Correction of inverted breast nipple by using Serdev suture provides bulk and structural stability to the nipple by using Serdev Suture technique.

techniques. The complications include with these techniques recurrence, lactation problems, hypopigmented scar formation in the areola, and loss of sensation.

The best simple method for the treatment of grade I treatment had been reported by Kesaree et al. [15] is the inverted syringe method to pull out the flat or retracted nipple.

A multicentric study of the different methods showed that sustained improvement is more common in the untreated group [16] and that the difference in the shell/no shell was 52% vs. 60%, which is not significant.

The Correction of inverted breast nipple by using Serdev suture provides bulk and structural stability to the nipple by using Serdev Suture technique (Figure 3 and 4). The blood supply to the nipple flap is reliable through the dermal and subdermal plexus from the remaining non-incised site of the nipple and areola region. The Serdev sutures are slowly absorbed over the period of 2 to 3 years, maintaining the lifting effect of nipple and keep the breast nipple everted and the effect stays permanent after the healing is complete. Previously described purse string sutures either non absorbable result in cut through effect of the soft tissue or absorbable sutures in few weeks resulting in collapse of the breast nipple [17]. To ensure the reliability of the result, various other techniques are described by Bracaglia et al. [18]. Kurihara et al. [19] described the use of tendon graft for correction of the inverted nipple.

Surgical Technique

The inverted nipple is lifted by two skin hooks. After infiltration of the area around nipple, three stab incisions at 12, 4 and 9 O'clock position made with number 11 blades. The fibrotic bands are widely dissected by to and fro motion in vertical plane with number 11 blade avoiding damage to the lactiferous ducts. The surgical releases were carried out until the inversion did not recur after releasing the traction. The purse-string suture used. The stab incision site covered with non adhesive dressing.

Conclusion

The correction of inverted breast nipple with Serdev suture technique is simple, reliable, time efficient, scarless and is easy to learn. It provides long lasting results as compared to the traditional techniques with or without commonly used sutures. Therefore, I recommend this technique for correction of Grade 2 and 3 inverted breast nipple.

References

- Han EH, Karypis G. Centroid-Based Document Classification: Analysis and Experimental Results. In: Zighed DA, Komorowski J, Żytkow J, editors. Principles of Data Mining and Knowledge Discovery. PKDD 2000. Lecture Notes in Computer Science, volume 1910. Berlin: Springer; 2002. p. 424-31.
- Han S, Hang YG. The inverted nipple: its grading and surgical correction. *Plast Reconstr Surg.* 1999;104(2):389-95.
- Alexander JM, Grant AM, Cambell MJ. Randomised controlled trial of breast shells and Hoffman's exercises for inverted and non-proctacile nipples. *BMJ.* 1992;304(6833):1030-2.
- Hoffman JB. A suggested treatment for inverted nipples. *Am J Obstet Gynecol.* 1953;66:346-8.
- Neifert MR, Seacat JM. A guide to successful breastfeeding. *Contemp Pediatr.* 1986;2:6-20.
- McGeorge DD. The "Niplette": An instrument for the nonsurgical correction of inverted nipples. *Br J Plast Surg.* 1994;47(1):46-9.
- Kim DY, Jeong EC, Eo SR, Kim KS, Lee SY, Cho BH. Correction of inverted nipple: an alternative method using two triangular areolar dermal flaps. *Ann Plast Surg.* 2003;51(6):636-40.
- Yamamoto Y, Sugihara T. Correction of inverted nipple with modified star flap technique. *Aesth Plast Surg.* 1997;21(3):193-5.
- Huang WC. A new method for correction of inverted nipple with three periductal dermofibrous flaps. *Aesthetic Plast Surg.* 2003;27(4):301-4.
- Tal MG. Correction of inverted nipple using piercing. *Plast Reconstr Surg.* 2003;112(4):1178-9.
- Karacaoglu E. Correction of recurrent grade III inverted nipple with antenna dermo adipose flap: case report. *Aesth Plast Surg.* 2009;33(6):843-8.
- Zhou H, Tan Q, Wu J, Zheng DF, Zhou HR, Xu P, et al. Correction of inverted nipple with bilateral areolar rhomboid dermal flaps. *J Plast Reconstr Aesthet Surg.* 2011;64(6):e159-61.
- Park HS, Yoon CH, Kim HJ. The prevalence of congenital inverted nipple. *Aesth Plast Surg.* 1999;23(2):144-6.
- Crestinu, J. The correction of inverted nipples without scars: 17 years' experience, 452 operations. *Aesth Plast Surg.* 2002;24(1):52-7.
- Kesaree N, Banapurmath CR, Banapurmath S, Shamanur K. Treatment of inverted nipples using a disposable syringe. *J Hum Lact.* 1993;9(1):27-9.
- Lawrence RA. Breastfeeding: a guide for the medical profession, 4th ed. St. Louis: Mosby, USA; 1994.
- Peled IJ. Purse-string suture for nipple projection. *Plast Reconstr Surg.* 1999;103(5):1480-2.
- Bracaglia R, Tambasco D, Gentileschi S, D'Ettoire M. Recurrent inverted nipple: a reliable technique for the most difficult cases. *Ann Plast Surg.* 2012;69(1):24-6.
- Kurihara K, Maezawa N, Yanagawa H, Imai T. Surgical correction of the inverted nipple with a tendon graft: hammock procedure. *Plast Reconstr Surg.* 1990;86(5):999-1003.