



## Composite Titanium Mesh and Sternohyoid Myocutaneous Flap for Laryngotracheal Reconstruction in Two Patients with Relapsing Polychondritis

Wenxian Chen\*, Limei Zhong, Yanyan Ruan, Yabin Zhang and Ka Bian\*

Department of Otorhinolaryngology, The Fourth Military Medical University, China

### Abstract

**Objectives:** To investigate and treat the long segment severe laryngotracheal malacia and stenosis due to relapsing polychondritis with composite titanium mesh and sternohyoid myocutaneous flap.

**Methods:** Between years 2008 and 2015, two patients with severe long segment laryngotracheal malacia and stenosis due to relapsing polychondritis were reconstructed with composite a rotary door sternohyoid myocutaneous flap for internal lining and titanium mesh as a framework to support the flap for airway augmentation and preventing the mesh exposure into the lumen, one or two-stage procedure was retrospectively analyzed.

**Results:** The two patients were decannulated successfully from nine months to two years postoperatively with good exercise tolerance and adequate voice production. There were no surgical complications during operation. Follow-up of four to eight years, all patients were breathing spontaneously and leading normal life.

**Conclusion:** Reconstruction of long segment severe laryngotracheal malacia and stenosis due to relapsing polychondritis with composite titanium mesh and rotary door sternohyoid myocutaneous flap is a safe and effective surgical option.

**Level of Evidence:** A retrospective clinical study.

**Keywords:** Relapsing polychondritis; Laryngotracheal stenosis; Titanium mesh; Myocutaneous flap

### Introduction

Relapsing Polychondritis (RP) is an uncommon multisystem inflammatory disease affecting proteoglycan-rich structures and cartilaginous tissues. It is characterized by recurrent, wide spread chondritis of the auricular, nasal, laryngotracheal, and bronchial tree cartilage. It can also present with audio vestibular dysfunction, ocular inflammation, vasculitis, myocarditis and non-erosive arthritis. The clinical features include recurrent painful swell in the external ear and nose, which may result in permanent deformation of these structures due to loss of cartilage. The respiratory tract is involved in approximately half of the patients with clinical symptoms of dysphonia, cough, stridor, dyspnea, and recurrent pulmonary infections. The airway distress due to inflammation and degeneration of cartilage and fibrosis can lead to laryngeal, tracheobronchial malacia, collapse and stenosis. Diagnosis of RP is mainly based on clinical features and physical examination including an imaging evaluation of affected sites [1-3]. Treatment is based on clinical presentation and severity of disease progression. Anti-inflammatory drugs and glucocorticoid agents can be used in early and mild forms of disease. Immunosuppressive agents are used as the first line treatment in patients with severe respiratory or vascular involvement and secondary in those with steroid dependency or resistance. In patients with acute dyspnea tracheotomy is preferable until the disease process has stabilized. Then various surgical options include endoscopic dilatations, laser incisions, local steroid injections, noninvasive positive pressure ventilation, intra-luminal stenting or open laryngotracheal reconstruction [4-6]. In this paper, we report our experience with reconstruction of severe long segment laryngotracheal malacia and stenosis due to RP in two cases.

### Materials and Methods

#### Patients

**Case 1:** A 25-year-old man who was diagnosed with RP four years previously. He presented

### OPEN ACCESS

#### \*Correspondence:

Wenxian Chen, Department of Otorhinolaryngology, Tangdu Hospital, The Forth Military Medical University, Xian 710038, Shanxi, China, E-mail: chenwx@fmmu.edu.cn

Ka Bian, Department of Otorhinolaryngology, Tangdu Hospital, The Forth Military Medical University, Xian 710038, Shanxi, China, E-mail: kabian@fmmu.edu.cn

Received Date: 22 Apr 2019

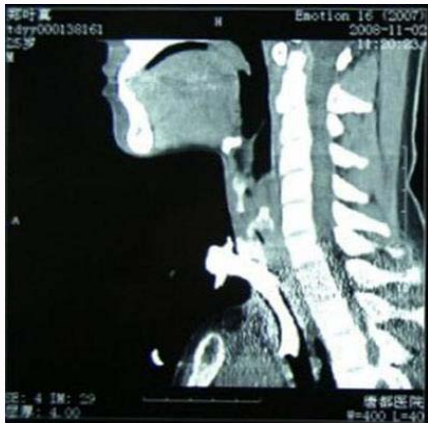Accepted Date: 06 Jun 2019

Published Date: 11 Jun 2019

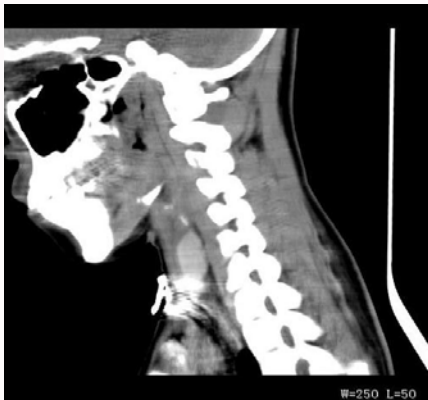#### Citation:

Chen W, Zhong L, Ruan Y, Zhang Y, Bian K. Composite Titanium Mesh and Sternohyoid Myocutaneous Flap for Laryngotracheal Reconstruction in Two Patients with Relapsing Polychondritis. Clin Surg. 2019;4:2466.

**Copyright** © 2019 Wenxian Chen and Ka Bian. This is an open access article distributed under the Creative Commons Attribution License, which permits unrestricted use, distribution, and reproduction in any medium, provided the original work is properly cited.



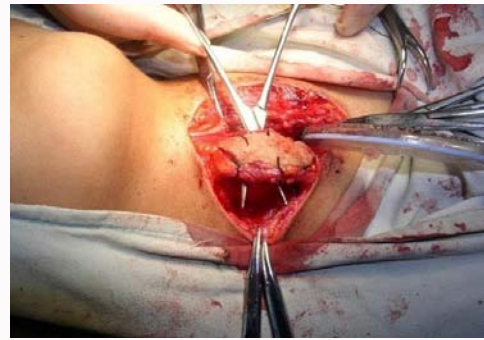**Figure 1:** Case 1: preoperative CT scan. Laryngotracheal lumen from thyroid to first thoracic vertebra severely stenosed with focal calcification.



**Figure 2:** Case 2: CT scan. The laryngotracheal lumen was closed with diffuse calcifications and some laryngotracheal cartilage was destroyed.

with rheumatic arthritis, chronic cough, hoarseness, recurrent pneumonia, and dyspnea, then underwent tracheotomy and treated with prednisolone and antibiotic agents. He was admitted to our hospital for laryngotracheal reconstruction on November 2, 2008. The flexible bronchoscopy examination showed that mobility of bilateral arytenoid cartilages was reduced and that glottis was severely narrowed (<3.0 mm). The subglottis and cervical trachea had malacia and stenosis about 5.5 cm in length. The distal trachea was normal. The neck and chest X-ray and CT scans showed that the laryngotracheal lumen from thyroid cartilage to the level of the first thoracic vertebra was severely stenosis with focal calcification (Figure 1). Histological analysis of subglottic scar tissues presented chronic inflammation of mucosa, fibrous tissue proliferation and lymphocytic infiltration. The patient underwent laryngotracheal reconstruction by two stages. On November 7, 2008 stage one was performed with a rotary door sternohyoid myocutaneous flap, that the flap consisted of the sternohyoid muscle with corresponding overly skin (6.0 cm × 1.5 cm) for airway augmentation. Stage two was performed on November 25, 2008, when the laryngotracheal lumen was reinforced with two arch titanium meshes (diameter: 3.0 cm, width: 1.3 cm) as framework covered and sutured onto the sternohyoid muscle that was the previously made up rotary door sternohyoid myocutaneous flap.

**Case 2:** A 20-year-old woman presented with recurrent pharyngolaryngitis, nasal obstruction, headache, pneumonia and dyspnea prompted tracheotomy and who was diagnosed with RP

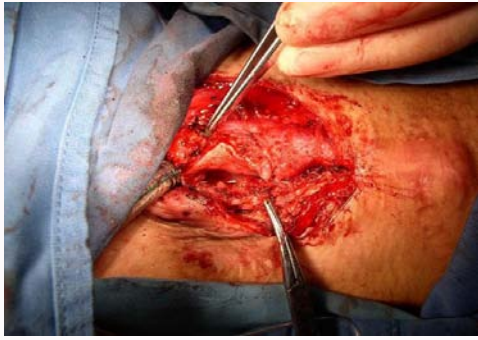

**Figure 3:** Laryngotracheal reconstruction with rotary door sternohyoid myocutaneous flap. The sternohyoid muscle was elevated and its amphipedicles were preserved.

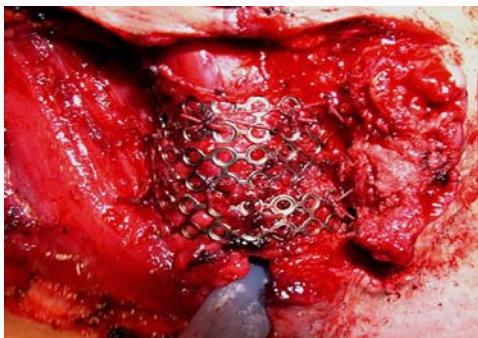
two years ago. On August 7, 2012, she was transferred to our hospital for laryngotracheal stenosis. The physical examination showed that she had a “saddle nose” and tracheostoma. Flexible bronchoscopy presented loss of motion of both vocal cords, glottic stenosis, subglottic to cervical trachea swelled and collapsed about 6.0 cm in length with little granulation tissue. Distal trachea appeared normal. Histological analysis of subglottic mucosa and granulation tissue showed severe chronic mucositis, submucosal edema, and lymphocytic infiltration. X-ray and CT scans of the neck and chest showed that laryngotracheal cartilages were destroyed and that supraglottic to subglottic lumen was closed with diffuse calcifications (Figure 2). On August 11, 2012, she underwent laryngotracheal reconstruction with composite of three arch titanium mesh (two mesh were 4.0 cm in diameter, 0.5 cm wide; one mesh was 4.0 cm in diameter, 0.2 cm wide) and rotary door sternohyoid myocutaneous flap.

### Operation

Laryngotracheal reconstruction was performed under general anesthesia by means of a flexible anesthesia tube placed through the existing tracheostoma. A vertical midline skin incision was made from below the hyoid bone to the tracheostoma and the muscles separated in the midline. The anterior laryngotracheal wall was exposed. It showed collapse and distortion as most of the laryngotracheal cartilages were replaced by scar tissue in the two cases. The laryngotracheal lumen was split at the midline from the thyroid cartilage to tracheostoma. In case 1, both arytenoid cartilages lacked mobility and that glottis was severely narrowed. The subglottis and cervical trachea had malacia and stenosis about 5.5 cm in length. In case 2, both vocal cords had loss of motion in nearly middle position and the laryngotracheal lumen was occluded for about 6.0 cm in length with scar tissue. Then arytenoidectomy and vocal cord lateralization was performed on one side and the scar tissue was dissected completely along the involved laryngotracheal lumen with preservation of as much lateral and posterior mucosa and cartilaginous structures as possible. An absorbable sutures was placed to anchor the flap out laterally and was fixed to the deep cervical soft tissue as for laterally as possible. These lateral sutures markedly displace the stenotic walls of the laryngotracheal for widen the lumen. Along the left side of the laryngotracheal defect, a vertical para-median a bipediced sternohyoid myocutaneous flap was outlined over the sternohyoid muscle. The flap consisted of the sternohyoid muscle with corresponding overly skin. The skin would lie at the proper level and be of sufficient length and width to repair the laryngotracheal stenosis defect (In case 1: 6.0 cm × 1.5 cm and



**Figure 4:** The sternohyoid myocutaneous flap was 180 degree rotation to cover the defect, and sutured to margins of the defect.

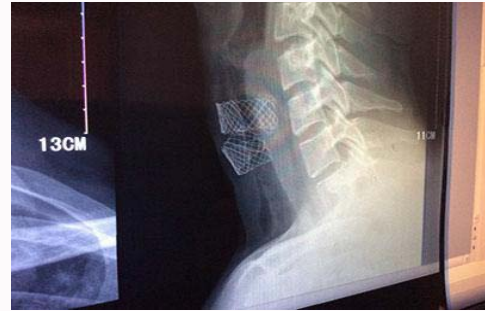


**Figure 5:** The titanium mesh was placed on the surface of the myocutaneous flap and sutured tightly on the flap. Both ends of the titanium mesh were fixed on the bilateral of the trachea.

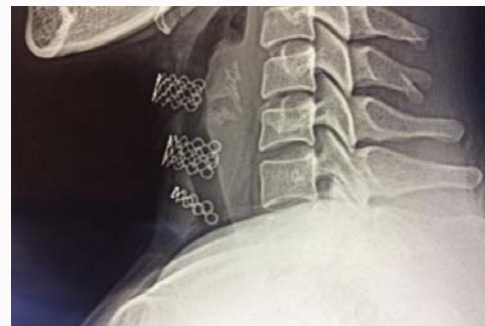in case 2: 6.5 cm × 1.5 cm). The sternohyoid muscle was elevated from its sternum attachment and hyoid bone insertion and its amphi-pedicles were preserved (Figure 3). The vessels were carefully dissected and preserved. Release of tension permitted 180-degree rotation of the flap to cover the defect of airway. Then the skin of flap was sutured to the bilateral margins of the defect. A novel silicone T-tube (a round silicone T-tube with blind upper end) was inserted into the laryngotracheal lumen for stabilization and enlargement of the lumen (Figure 4). Based on the length of the narrowed segment, case 1 with two titanium meshes (diameter: 3.0 cm, width: 1.3 cm) were separated covering and interrupted sutures onto the previously made sternohyoid myocutaneous flap (on stage 2); in case 2 with three titanium meshes (two mesh were 4.0 cm in diameter, 0.5 cm wide; one mesh was 4.0 cm in diameter, 0.2 cm wide) were separated covering and interrupted sutures onto the sternohyoid muscle to suspend the rotary sternohyoid myocutaneous flap. Then both ends of the titanium mesh were fixed on the bilateral of the trachea (Figure 5). Bilateral cervical skin was undermined and advanced medially to cover the composite titanium mesh and sternohyoid myocutaneous flap. Then the composite flap was sutured to the subcutaneous region of the cervical skin. The cervical skin was closed in layers. An antibiotic dressing was placed on the wound and a pressure dressing was applied for one week.

### Postoperative care

A nasogastric tube feeding, prophylactic aerosols of antibiotic steroid solution were used in all patients for 7 to 14 days. The neck wound healed one week postoperatively. There were no complications. The patients were followed up at least once with flexible bronchoscopy and X-ray to detect potential restenosis and



**Figure 6:** Case 1: X-ray at 6 years post-operation. The positioning of titanium mesh was good and the laryngotracheal lumen was wide.



**Figure 7:** Case 2: X-ray at two year post-operation. The positioning of titanium mesh was good and the laryngotracheal lumen was wide.

complications in outpatients. The T-tube was removed from nine months to two years postoperatively.

## Results

### Case 1

On September 26, 2010, after two years post-operation, the patient was admitted to our hospital. The T-tube was removed, and a tracheotomy tube was placed and corked. The flexible bronchoscopy and X-ray of the neck and chest showed that the position of titanium mesh was good and laryngotracheal lumen was wide with no granulation tissue formation (Figure 6). The patient was decannulated successfully one month later. He had normal exercise tolerance and an effective voice. During eight years follow-up visit, patient's respiration is good. He lives a normal life and works as an engineer.

### Case 2

On October 21, 2014, two years post-surgery, the T-tube in the patient was removed and a tracheotomy tube was placed and corked. She was decannulated one month later. The flexible bronchoscopy and X-ray showed that the laryngotracheal lumen was wide, smooth and had no granulation tissue formed (Figure 7). With four years follow-up, the patient had good exercise tolerance and an effective voice.

## Discussion

Relapsing Polychondritis (RP) is a multi-system autoimmune disease. It is characterized by progressive inflammation and degeneration of cartilage and connective tissues. Airway involvement in RP is seen about 50% of these patients. Airway recurrent inflammation and degeneration of cartilage leads to laryngeal, tracheobronchial malacia, collapse and stenosis. It is the most severe complication and therapeutic challenge for surgeon. For

acute airway distress tracheotomy is preferable. Once the disease is stabilized, laryngotracheal reconstruction may be performed. The laryngotracheal reconstruction for RP patients should be based on clinical presentation and severity of disease.

Titanium mesh has been used for laryngotracheal reconstruction for one or two stages and has been found to be a good alternative for augmentation of the anterior laryngotracheal wall [7,8]. However, the titanium mesh, as the sole transplant material for reconstruction, may lead to risk of erosion in the external or internal tissues of laryngotracheal induced granulation formation or dislocation. Yener et al., [9] reported an animal study using titanium mesh in laryngotracheal reconstruction. The study illustrated that the titanium mesh achieved a stable and airtight airway under physiologic and supra-physiologic conditions. But there are severe complications that may cause problems like pronounced granulation, edema and obstruction in the long-term prognosis of the case. The material is not flexible with rigid edges, since when the laryngotracheal is dynamic followed the respiration and swallow; the rigid edges may irritate the implanted region. This causes more granulation and inflammation. Therefore, the author suggested that an application of titanium mesh composed with larger skin grafts may avert this complication. Janssen et al., [10] implanted porous titanium in combination with mucosal grafts into rabbits and nude mice. Their experiments showed that porous titanium, in combination with viable auto-tissues, is a good alternative for tracheal reconstruction, especially in regards to larger and circular defects. Nobukiyo et al., [11] described a 58-year-old man with RP with epiglottis deformity and impairment of the movement of both vocal cords. This patient had 5 cm of the trachea in length collapse reaching 3 cm above the main carina. Bilateral bronchi walls were diffused with focal calcifications. A tracheotomy was performed, and a silicon T-tube was placed. In addition, 2 expandable metallic stents were placed from the trachea to the bilateral main bronchi. This dilated the airway lumen, resulting in the complete disappearance of dyspnea. However, 18 months later, a sudden massive hemorrhage occurred through the tracheotomy, and the patient died from respiratory failure. Autopsy showed a tracheoinnominate artery fistula. Based on this patient, Nobukiyo suggested that the used of an expandable metallic stent should not be optioned for the management of benign tracheobroncheal obstruction, such as RP or long-term placement. Our previous report thirteen patients with laryngotracheal stenosis or tracheoesophageal fistula secondary to insertion of the nickel-titanium alloy stent for treatment of laryngotracheal, bronchial or esophageal stenosis [12]. Of the 13 total patients, 9 had one stent placed, and 4 had two stents placed. The late complication were glottic and/or subglottic extension of cervical tracheal stenosis (n=6), new stricture of the thoracic trachea (n=4), severe left bronchial stricture with massive left pulmonary collapse (n=1), and cervical tracheoesophageal fistula (n=2). Among them a patient with tracheoesophageal fistula died from massive hemorrhage and asphyxiation induced by the stent which had not been removed. These results suggested the nickel-titanium alloy stent should not be used in the patients with benign laryngotracheal, bronchia or esophageal stenosis. Balasubramanian et al., [13] reported a patient with papillary carcinoma of the thyroid, who had a defect in the trachea measuring 6 cm in length and involved part of the cricoid cartilage and upper four tracheal rings after carcinoma excision. The defect was reconstructed using a free radial forearm flap with the fascia suspended on a titanium mesh. At the six-month follow-up, the patients exhibited normal nasal breath and voice.

In our two patients with long-segment severe laryngotracheal stenosis and loss of cartilage framework, we adopted titanium mesh as the laryngotracheal scaffolding and the rotary door sternohyoid myocutaneous flap for internal lining and enlargement of the laryngotracheal lumen. The mesh was covered and interrupted sutures onto the sternohyoid myocutaneous flap to prevent possible complications of granulation and inflammation in the laryngotracheal lumen. Then, the cervical wound was closed in layers. Flexible bronchoscopy and X-ray before decannulation were performed on the two patients. The examination showed that the laryngotracheal lumen was wide, smooth and had no granulation tissues, and successful decannulation. The follow-up period ranged from four to eight years. The two patients showed a stable airway, adequate vocal function and lead normal lives and work.

## Conclusion

Our results suggest that using a composite of titanium mesh and rotary door sternohyoid myocutaneous flap is a safe, effective treatment option for the reconstruction of long segment severe laryngotracheal malacia and stenosis due to RP patients.

## Acknowledgment

We would like to thank Mr. Leonid Yermakov and Dr. Luping Huang for editing the article.

## References

- Vitale A, Sota J, Rigante D, Lopalco G, Molinaro F, Messina M, et al. Relapsing polychondritis: an update on pathogenesis clinical feature, diagnostic tools, and therapeutic perspectives. *Curr Rheumatol Rep.* 2016;18 (1):3.
- Horváth A, Páll N, Molnár K, Kováts T, Surján G, Vicsek T, et al. A nationwide study of the epidemiology of relapsing polychondritis. *Clin Epidemiol.* 2016;8:211-30.
- Anchan SV, Garag SS, J S A, Prasad KC, Sharma PV. An interesting case of relapsing polychondritis in a young girl. *J Clin Diagn Res.* 2013;7(12):2976-7.
- Puechal X, Terrier B, Mouthon L, Costedoat-Chalumeau N, Guillemin L, Le Jeune C. Relapsing polychondritis. *Joint Bone Spine.* 2014;81(2):118-24.
- Yamaguchi H, Komase Y, Ono A, Morita A, Ishida A. Successful treatment with noninvasive positive-pressure ventilation based on the prediction of disease onset using CT and respiratory function tests in an elderly patient with relapsing polychondritis. *Intern Med.* 2013;52(10):1085-9.
- Childs LF, Rickert S, Wengerman OC, Lebovics R, Blitzer A. Laryngeal manifestations of relapsing polychondritis and a novel treatment option. *J Voice.* 2012;26(5):587-9.
- Daneshi A, Mohammadi S, Hassannia F. Delayed laryngotracheal reconstruction with titanium plate: report of 10 cases. *J Voice.* 2010;24(6):755-7.
- Gaafar AA, El-Daly AA, Gaafar HA. Laryngotracheal augmentation using titanium mesh. *J Laryngol Otol.* 2008;122(4):391-6.
- Yener M, Acar GO, Cansiz H, Oz B, Cigeriogullari E, Seymen O. Use of titanium mesh in laryngotracheal reconstruction: an experimental study on rabbits. *Eur Arch Otorhinolaryngol.* 2010;267(8):1247-53.
- Janssen LM, van Osch GJ, Li JP, Kops N, de Groot K, Von den Hoff JW, et al. Tracheal reconstruction: mucosal survival on porous titanium. *Arch Otolaryngol Head Neck Surg.* 2009;135(5):472-8.
- Nobukiyo S, Iwatake H, Watanabe S, Akao I, Tomisawa H, Koizuka I. A case of relapsing polychondritis involving placement of an expandable metallic stent. *Auris Nassus Larynx.* 2003;30:S141-4.

12. Chen W, Ruan Y. Late complications of nickel-titanium alloy stent in tracheal stenosis. *Laryngoscope*. 2012;122(4):817-20.
13. Balasubramanian D, Thankappan K, Shetty S, Jayaprasad K, Mathew J, Iyer S. Cricotracheal reconstruction with free radial forearm flap and titanium mesh. *Head Neck*. 2013;35(6):E178-80.