



Comparison of One-Stage Versus Two-Stage Procedure for Management of Patients with Rotator Cuff Tear and Concomitant Shoulder Stiffness

Hongwu Zhuo*

Department of Sports Medicine, Fuzhou Second Hospital, Fuzhou, China

Abstract

Purpose: To compare the clinical outcomes of one-stage and two-stage procedure for management of patients with rotator cuff tear and concomitant shoulder stiffness.

Methods: From December 2013 to June 2016, we recruited 42 consecutive patients with rotator cuff tear and concomitant shoulder stiffness. Twenty-two patients underwent one-stage procedure including arthroscopic capsule release and concomitant rotator cuff repair within 2 weeks of the diagnosis. For the remaining twenty patients, conservative treatment for the recovery of ROM was initially performed before arthroscopic rotator cuff repair. The range of motion (ROM), VAS, American Shoulder and Elbow Surgeons (ASES) score, Constant-Murley score and satisfaction rate were assessed preoperatively; 3, 6, 12, 24 months after surgery; and at final follow-up.

Results: The mean follow-up period was 26.3 months (range, 24-33 months). There were no significant differences in preoperative demographic data between the groups ($P>0.05$). After treatment, there was significant improvement in ROM and functional scores in both groups ($P<0.05$). At 3 months postoperatively, the two-stage group exhibited significantly improved forward flexion and internal rotator compared with the one-stage group ($P=0.001$ and $P=0.038$, respectively). There was no significant difference in ROM between the 2 groups at any other time point ($P>0.05$). In addition, no significant difference was found in functional scores and satisfaction rate between the 2 groups at final follow-up ($P>0.05$).

Conclusion: In the treatment of rotator cuff tear with concomitant stiffness, even though the recovery of ROM took longer in patients who underwent one-stage procedure, satisfactory results can be achieved either by one-stage procedure or two-stage procedure at final follow-up.

Study Design: Retrospective comparative study; Level of evidence, 3.

Keywords: Rotator cuff; Repair; Stiffness; Arthroscopic surgery; Capsular release; Conservative treatment

Introduction

Rotator cuff tear is a common condition that causes shoulder pain and dysfunction in daily life [1-3]. For many patients with rotator cuff tear, they might also have concomitant shoulder stiffness, with a reported incidence of up to more than 40% [4,5].

The optimal management of patients with rotator cuff tear and concomitant shoulder stiffness still remains controversial [6-13]. Traditionally, when a patient had a rotator cuff tear with concomitant shoulder stiffness, the stiffness should be addressed initially through conservative treatment before rotator cuff repair because the repair is a “shoulder-tightening” procedure and might increase stiffness postoperatively [9-11]. However, this two-stage procedure would prolong the patient’s suffering owing to the delay of surgery and the rotator cuff tear may extend during the treatment of the stiffness [6-8,12-14]. Recently, an one-stage procedure has been proposed for the management of patients with rotator cuff tears and concomitant stiffness [7,12,13]. However, to our knowledge, there is limited data comparing the clinical outcomes of one-stage and two-stage procedure for treatment of patients with rotator cuff tear and concomitant stiffness.

The purpose of the present study was to compare the clinical outcomes of one-stage and two-stage procedure for rotator cuff tear and concomitant stiffness. We hypothesized that there would

OPEN ACCESS

*Correspondence:

Hongwu Zhuo, Department of Sports Medicine, Fuzhou Second Hospital, Fuzhou, China,

E-mail: zhuohongwu@foxmail.com

Received Date: 16 Aug 2018

Accepted Date: 14 Sep 2018

Published Date: 18 Sep 2018

Citation:

Zhuo H. Comparison of One-Stage Versus Two-Stage Procedure for Management of Patients with Rotator Cuff Tear and Concomitant Shoulder Stiffness. *Clin Surg*. 2018; 3: 2115.

Copyright © 2018 Hongwu Zhuo. This is an open access article distributed under the Creative Commons Attribution License, which permits unrestricted use, distribution, and reproduction in any medium, provided the original work is properly cited.

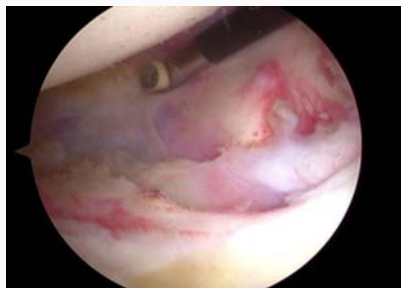


Figure 1: Capsular release was performed using a radiofrequency device.

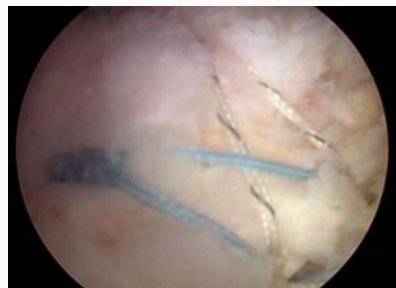

Figure 3: Suture bridge technique.

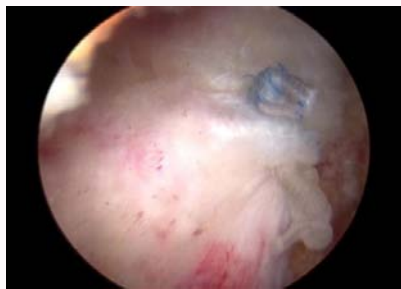

Figure 2: Single-row technique.

be no difference between these two groups in ROM, functional scores and satisfaction rate at final follow-up.

Materials and Methods

Study population

This was a retrospective study. From December 2013 to June 2016, fifty-six consecutive patients with rotator cuff tear and concomitant shoulder stiffness underwent either one-stage or two-stage procedure for treatment in our institution. The inclusion criteria were the following: (1) patients with a small-sized (tear size <1 cm) or medium-sized (tear size 1~3 cm) full-thickness rotator cuff tear; (2) patients with a concomitant limited passive ROM: forward flexion was less than 100° passively, external rotation with the arm at the side was less than 30° passively, internal rotation of a vertebral level where the thumb reached was lower than the first lumbar spine junction passively; (3) patients with a minimum follow-up period of 2 years. Patients who had previous shoulder fractures or previous surgical procedures on the ipsilateral joint were excluded. Patients with concomitant shoulder lesions such as arthritis in the glenohumeral joint or labral lesions were also excluded.

According to the criteria, forty-two patients were included in this study. The one-stage group consisted 22 patients (6 men, 16 women) and the two-stage group consisted 20 patients (4 men, 16 women). Approval of the study was obtained through the institutional review board at our institution. All patients had provided signed informed consent to allow their clinical and radiologic data to be used for research programs.

Assessment

Demographic data that could affect the outcomes of arthroscopic rotator cuff repair, including patient's age, sex, hand dominance, history of diabetes mellitus, duration of symptoms, fatty infiltration of the rotator cuff muscles, tear size, repair technique, and concomitant procedures (such as biceps tenotomy or tenodesis, acromioplasty, distal clavicle resection), were collected from

our database. Fatty infiltration of the rotator cuff muscles was evaluated using preoperative MRI (3.0-T MR System, Signa Excite; GE Medical Systems, Waukesha, Wisconsin, USA) and classified according to the criteria established by Goutallier et al. [15] and modified by Fuchs [16]. Scans were evaluated at the level where the scapular spine and body form a Y-shape in the oblique sagittal view. The tear size of rotator cuff was measured intraoperatively under direct arthroscopic visualization with a calibrated probe and classified according to the criteria established by DeOrto et al. [17]. The patients were routinely followed at 1, 3, 6, 12 and 24 months after surgery.

ROM

For all patients, passive ROM including forward flexion, external rotation with the arm at the side and internal rotation was evaluated preoperatively; 3, 6, 12, 24 months after surgery; and at final follow-up. Forward flexion and external rotation were evaluated with a goniometer with patients in the supine position. Internal rotation, which was measured in the seated position, was evaluated by the tip of the thumb reaching the vertebral level. For statistical analysis, internal rotation up to the level of the sacrum was designated as 0 point, and 1 point was added for each level above this. All the assessment data were collected by a clinical researcher who was blinded to this study.

Functional and satisfaction assessments

At final follow-up, functional assessment was performed using Visual Analogue Scale (VAS), American Shoulder and Elbow Surgeons (ASES) score and Constant-Murley score. The VAS was scored on a scale of 0 to 10, with 10 indicating the highest level of pain. The ASES score consisted of a score summation using a 100-point system (50 points for daily function and 50 points for pain). Patients were additionally asked about their satisfaction regarding their clinical outcomes (i.e., very satisfied, satisfied, neutral, or not satisfied). The proportion of very satisfied and satisfied patients was defined as the satisfaction rate.

Surgical procedure

All of the surgeries were performed by our senior author who had performed nearly 300 shoulder arthroscopic surgeries per year for the last 6 years.

One-stage group

In this group, all the patients underwent one-stage procedure including arthroscopic capsule release and concomitant rotator cuff repair within 2 weeks of the diagnosis. After induction of general anesthesia, each patient was positioned in a lateral decubitus position with the involved arm suspended to an arm-holding device using 10 to 15 pounds of suspension. A routine arthroscopic glenohumeral examination was performed through the standard posterior and anterior portals. After confirmation of synovial hypertrophy and

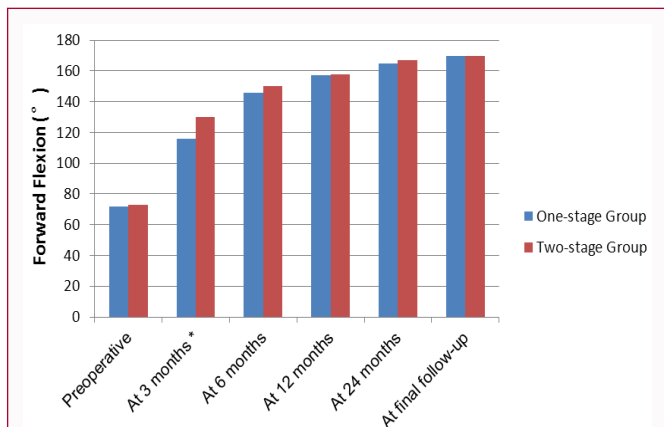


Figure 4: The mean changes in forward elevation. At 3 months postoperatively, the two-stage group exhibited significantly improved forward flexion compared with the one-stage group ($P=0.001$). No significant differences between groups were seen at any other time point ($P>0.05$).

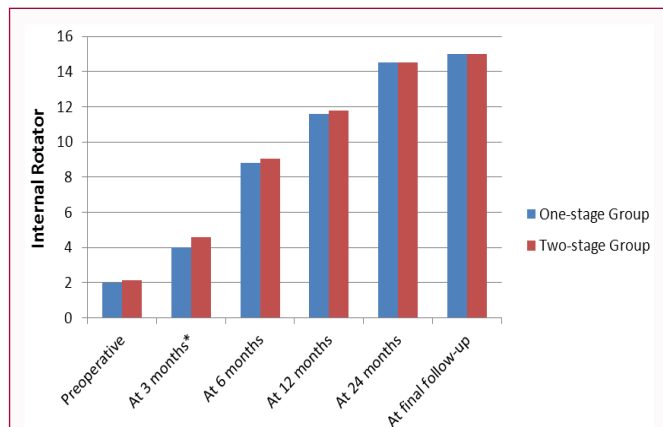


Figure 6: The mean changes in internal rotator. At 3 months postoperatively, the two-stage group exhibited significantly improved internal rotator compared with the one-stage group ($P=0.038$). No significant differences between groups were seen at any other time point ($P>0.05$).

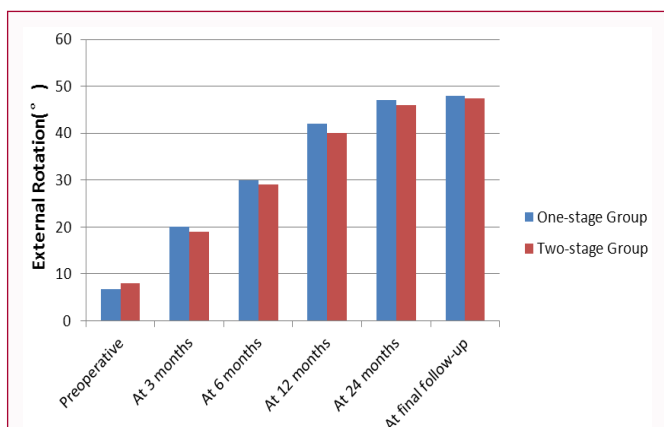


Figure 5: The mean changes in external rotator. No significant differences between groups were seen at any time point ($P>0.05$).

capsular thickening, sequential release of the rotator interval and anterior, inferior, and posterior capsules using a radiofrequency device (Arthrocare, Sunnyvale, California, USA) was performed (Figure 1). Capsular release was done just off the glenoid rim so as to avoid damaging the axillary nerve. The arthroscope was then placed in the subacromial space and lateral portals were established as the working portal. After removal of residual bursa and debridement of degenerated tendon edges, the rotator cuff tear was accessed using a calibrated probe. For small-sized rotator cuff tears, the repair was conducted by single-row technique (Figure 2). For medium-sized rotator cuff tears, a suture bridge technique was applied (Figure 3).

Two-stage group

In this group, conservative treatment for the recovery of ROM was initially performed before arthroscopic rotator cuff repair. Conservative treatment included Nonsteroidal Anti-Inflammatory Medications (NSAIDs), corticosteroid injections, and rehabilitative therapy. Rehabilitative therapy consisted of pendulum circumduction, passive shoulder stretching in forward flexion, external rotation, horizontal adduction, and internal rotation. Patients were instructed to stretch the shoulder to the point of tolerable discomfort and hold the position for 3 seconds. Rehabilitative therapy was performed 3 times every day and each session last at least 15 minutes. Nonsteroidal anti-inflammatory drugs were prescribed when necessary. Rehabilitative therapy was continued for 3 months and subsequent surgery for

rotator cuff repair was performed.

Postoperative rehabilitation

The postoperative rehabilitation protocol was identical in both groups. Immobilization was maintained with an abduction brace at 30° for 6 weeks. From the first day after surgery, all patients engaged in pendulum, passive forward flexion and external rotation exercises. Active exercises were not allowed until 6 weeks postoperatively. Muscle strengthening exercises were usually initiated at 3 months postoperatively. A return to recreational activity with heavy demands on the shoulder or to manual labor was delayed for 6 months.

Statistical analyses

All statistical analyses were performed using SPSS software (IBM-SPSS statistics 19.0; New York, USA). The data were presented as means and standard deviations for description. Paired *t* test was used to compare the preoperative and postoperative results including ROM and functional scores. Unpaired *t* test was used to compare the continuous variables between the 2 groups. A chi-square analysis was used to determine the differences in patient’s sex, side and satisfaction rate. The significance level was set to 0.05.

Results

Demographic data

Forty-two patients met the inclusion criteria and were included in this study. There were 10 male and 32 female with a mean age of 54.1 years (range, 47 - 69 years). The mean follow-up period was 26.3 months (range, 24 - 33 months). The demographic data of the patients are summarized in table 1. The one-stage group consisted 22 patients and the two-stage group consisted 20 patients. Overall, there were no statistically significant differences in the demographic data between the 2 groups ($P>0.05$, Table 1).

ROM

Before treatment, no significant differences were found between the 2 groups in ROM ($P>0.05$, Figures 4-6). In two-stage group, six patients with drawn from rehabilitative therapy because of severe pain and underwent surgery in advance. However, the remaining 14 patients exhibited significant improved forward flexion and internal rotation after rehabilitative therapy ($72.50^\circ \pm 10.35^\circ$ to $104.50^\circ \pm 12.90^\circ$, $P<0.05$; 2.07 ± 0.98 to 3.15 ± 0.86 , $P<0.05$). And two patients didn’t have subsequent surgery because of significant improvement

Table 1: Demographic Data.

	Two-stage Group (n=20)	One-stage Group (n=22)	P Value
Age, y	52.90 ± 5.87	55.22 ± 6.32	0.165
Sex (male/female)	4/16	6/16	0.580
Dominant/nondominant	6/14	8/14	0.662
Diabetes mellitus	3	2	0.716
Duration of symptoms, mo	11.05 ± 3.74	9.57 ± 2.93	0.152
Fatty infiltration ^b	0.70 ± 0.57	0.68 ± 0.56	0.912
Tear size, small/medium ^c	3/17	4/18	0.782
Repair technique (single-row/suture bridge)	3/17	4/18	0.782
Concomitant procedures			
Acromioplasty	14	12	0.303
Biceps tenodesis	3	5	0.524
Biceps tenotomy	5	6	0.867
Mean follow-up period, mo	25.35 ± 2.13	27.36 ± 4.98	0.102

^aValues presented as mean ± standard deviation.

^bGraded according to the criteria established by Goutallier et al. [8] and modified by Fuchs [7].

^cGraded according to the criteria established by DeOrio et al. [5].

in pain relieve and ROM.

At 3 months postoperatively, the two-stage group exhibited significantly improved forward flexion and internal rotation compared with the one-stage group ($P=0.001$ and $P=0.038$, respectively, Figure 4, 6). However, no significant difference was found between the 2 groups in external rotation ($P>0.05$, Figure 5). However, there were no significant differences in ROM between the 2 groups at 6, 12, 24 months and final follow-up ($P>0.05$). In addition, both groups achieved significantly improved ROM at final follow-up compared with ROM before treatment (Figures 4-6).

Functional outcomes

Both groups had significant improvements in the VAS score, ASES score and Constant score at final follow-up ($P=0.001$). No significant differences were found between the 2 groups regarding the VAS score, ASES score and Constant score at any period after surgery ($P>0.05$, Table 2). The satisfaction rate was 90.5% in one-stage group and 68.2% in two-stage group. There was no significant difference in satisfaction rate between the 2 groups ($P=0.085$, Table 2).

Discussion

The principal findings of the present study were that overall satisfactory clinical outcomes could be achieved in both patients after one-stage procedure or two-stage procedure for rotator cuff tear and concomitant shoulder stiffness. At 3 months, the two-stage group exhibited significantly improved forward flexion and internal rotator compared with the one-stage group. However, there was no significant difference in ROM between the 2 groups at any other time point ($P>0.05$). In addition, no significant difference was found in functional scores and satisfaction rate between the 2 groups at final follow-up ($P>0.05$).

Factors leading to shoulder stiffness in patients with rotator cuff tear

Several studies have reported that patients with rotator cuff tear could also have shoulder stiffness [4,5]. Tauro et al. [4] reported on a cohort of 72 patients who underwent rotator cuff repair and found that 40% of the patients had concomitant shoulder stiffness. According to the published literature [4-6,12,18], the factors leading to shoulder

Table 2: Comparison of Clinical Outcomes Between the Two Groups.

	Two-stage Group (n=20)	One-stage Group (n=22)	P Value
VAS			
Preoperative	5.60 ± 0.75	5.72 ± 0.93	0.632
At final follow-up	1.65 ± 0.74	1.40 ± 0.79	0.319
P Value	0.001	0.001	
ASES			
Preoperative	41.95 ± 10.58	40.10 ± 9.61	0.557
At final follow-up	81.27 ± 6.94	83.75 ± 8.11	0.529
P Value	0.001	0.001	
Constant-Murley			
Preoperative	36.85 ± 8.08	39.40 ± 6.59	0.266
At final follow-up	79.50 ± 7.77	78.59 ± 7.95	0.711
P Value	0.001	0.001	
Satisfaction rate	90.0%	68.2%	0.085

Abbreviations: VAS: Visual Analogue Scale; ASES: American Shoulder and Elbow Surgeons Score

stiffness in patients with rotator cuff tear include the following: (1) the pain from rotator cuff tears results in joint disuse, contracture of the joint capsule and secondary muscular weakness which would finally facilitate the joint stiffness; (2) secondary adhesive capsulitis, which is precipitated by inflammation from the rotator cuff tear, could also be a contributor to joint stiffness.

Management of patients with rotator cuff tear and concomitant stiffness

The optimal management of patients with rotator cuff tears and concomitant shoulder stiffness still remains controversial [6-14]. The main concern about one-stage procedure is the high risk of developing postoperative stiffness [9-11]. Huberty et al. [11] reported on a cohort of 489 patients who underwent rotator cuff repair. They found that 24 patients (4.9%) developed postoperative stiffness and the patients with preoperative shoulder stiffness were associated with a significantly increased incidence of 15.6% for postoperative stiffness. In the current study, we also found the patients who underwent one-

stage procedure exhibited significantly lower forward flexion and internal rotator at 3 months postoperatively.

Nevertheless, the two-stage procedure also has its own inherent disadvantages, including the following: (1) the two-stage procedure would prolong the patient's suffering owing to the delay of surgery. In the current study, six patients refused to tolerate the remaining rehabilitation period because of severe pain during stretching exercises. In another study by Kim [12], the author also reported on a series of 33 patients who underwent conservative treatment before rotator cuff repair and six patients (18.2%) with drawn because of severe pain during rehabilitation; (2) nonsurgical treatment for shoulder stiffness may be insufficient, especially in the presence of rotator cuff lesions [1,19,20]; (3) in addition, inappropriate exercise could lead to fatigue accumulation in the damaged tendon which might actually worsen the rotator cuff injury [12].

The clinical outcomes of surgical treatment for rotator cuff tear and concomitant shoulder stiffness

Recently, several studies have reported overall satisfactory clinical outcomes of surgical treatment for rotator cuff tears and concomitant stiffness [6,7,9,10,12,13]. Ho et al. [9] reported on a cohort of 211 patients who underwent rotator cuff repair. Forty-three patients had severe concomitant shoulder stiffness and underwent 1-stage arthroscopic capsular release and rotator cuff repair. They found the clinical outcomes of the stiffness group were statistically the same as those in the non-stiffness group. Oh et al. [13] reported a retrospective comparative study of 125 patients who underwent rotator cuff repair. Thirty patients had concomitant moderate shoulder stiffness at the time of the repair. They found that differences in ROM and functional scores did not reach statistical significance after 6 months of operation if arthroscopic capsular release with manipulation is added to the cuff repair procedure. Cho and Rhee [6] reported on a cohort of 45 patients and they also determined good clinical outcomes after rotator cuff repair with concomitant manipulation for treatment of rotator cuff tears with stiffness.

However, the weakness of these studies is that there is no data about the clinical outcomes after two-stage procedure for treatment of rotator cuff tears and concomitant stiffness, which makes it impossible to determine either one-stage procedure or two-stage procedure is associated with better clinical outcomes. Recently, Kim et al. [13] reported on a cohort of 63 patients with rotator cuff tears and stiffness to compare the clinical outcomes of immediate rotator cuff repair with capsular release and those of rotator cuff repair after the stiffness was treated with rehabilitative therapy. The author found improved results in both groups after 6 months postoperatively and the effect was maintained until 12 months postoperatively. In the present study, we further confirmed that similar satisfactory clinical outcomes could be maintained until 24 months postoperatively.

Limitations

There are some limitations to our study. First, this was a retrospective study that included all of the inherent limitations of this study design. Second, our study involved a relatively small number of patients. Third, the length of the follow-up was relatively short, and longer-term evaluations are required to compare the clinical outcomes of one-stage and two-stage procedure for rotator cuff tear and concomitant stiffness.

Conclusion

In the treatment of rotator cuff tear with concomitant stiffness,

even though the recovery of ROM took longer in patients who underwent one-stage procedure, satisfactory results can be achieved either by one-stage procedure or two-stage procedure at final follow-up. To avoid unnecessary rehabilitation, one-stage procedure may be a helpful option for patients with rotator cuff tear and concomitant stiffness.

References

1. Baums MH, Spahn G, Nozaki M, Steckel H, Schultz W, Klinger HM. Functional outcome and general health status in patients after arthroscopic release in adhesive capsulitis. *Knee Surg Sports Traumatol Arthrosc.* 2007 May;15(5):638-644.
2. Chung SW, Huong CB, Kim SH, Oh JH. Shoulder stiffness after rotator cuff repair: risk factors and influence on outcome. *Arthroscopy.* 2013;29(2):290-300.
3. Schmidt CC, Morrey BF. Management of full-thickness rotator cuff tears: appropriate use criteria. *J Shoulder Elbow Surg.* 2015;24(12):1860-7.
4. Seo SS, Choi JS, An KC, Kim JH, Kim SB. The factors affecting stiffness occurring with rotator cuff tear. *J Shoulder Elbow Surg.* 2012;21(3):304-9.
5. Tauro JC. Stiffness and rotator cuff tears: incidence, arthroscopic findings, and treatment results. *Arthroscopy.* 2006;22(6):581-586.
6. Cho NS, Rhee YG. Functional outcome of arthroscopic repair with concomitant manipulation in rotator cuff tears with stiff shoulder. *Am J Sports Med.* 2008;36(7):1323-9.
7. Chuang TY, Ho WP, Chen CH, Lee CH, Liao JJ, Huang CH. Arthroscopic treatment of rotator cuff tears with shoulder stiffness: A comparison of functional outcomes with and without capsular release. *Am J Sports Med.* 2012;40(9):2121-7.
8. Eljabu W, Klinger HM, von Knoch M. Prognostic factors and therapeutic options for treatment of frozen shoulder: a systematic review. *Arch Orthop Trauma Surg.* 2016;136(1):1-7.
9. Ho WP, Huang CH, Chiu CC, Lee CH, Chen CH, Leu TH, et al. One-stage arthroscopic repair of rotator cuff tears with shoulder stiffness. *Arthroscopy.* 2013;29(8):1283-91.
10. Hsu SL, Ko JY, Chen SH, Wu RW, Chou WY, Wang CJ. Surgical results in rotator cuff tears with shoulder stiffness. *J Formos Med Assoc.* 2007;106(6):452-61.
11. Huberty DP, Schoolfield JD, Brady PC, Vadala AP, Arrigoni P, Burkhart SS. Incidence and treatment of postoperative stiffness following arthroscopic rotator cuff repair. *Arthroscopy.* 2009;25(8):880-90.
12. Kim YS, Lee HJ, Park I, Im JH, Park KS, Lee SB. Are Delayed Operations Effective for Patients with Rotator Cuff Tears and Concomitant Stiffness? An Analysis of Immediate Versus Delayed Surgery on Outcomes. *Arthroscopy.* 2015;31(2):197-204.
13. Oh JH, Kim SH, Lee HK, Jo KH, Bin SW, Gong HS. Moderate preoperative shoulder stiffness does not alter the clinical outcome of rotator cuff repair with arthroscopic release and manipulation. *Arthroscopy.* 2008;24(9):983-91.
14. Weber SC, Abrams JS, Nottage WM. Complications associated with arthroscopic shoulder surgery. *Arthroscopy.* 2002;18(2 Suppl 1):88-95.
15. Goutallier D, Postel JM, Bernageau J, Lavau L, Voisin MC. Fatty muscle degeneration in cuff ruptures: pre- and postoperative evaluation by CT scan. *Clin Orthop Relat Res.* 1994;(304):78-83.
16. Fuchs B, Weishaupt D, Zanetti M, Hodler J, Gerber C. Fatty degeneration of the muscles of the rotator cuff: assessment by computed tomography versus magnetic resonance imaging. *J Shoulder Elbow Surg.* 1999;8(6):599-605.
17. DeOrto JK, Cofield RH. Results of a second attempt at surgical repair of a failed initial rotator-cuff repair. *J Bone Joint Surg Am.* 1984;66(4):563-7.

18. Klinger HM, Otte S, Baums MH, Haerer T. Early arthroscopic release in refractory shoulder stiffness. *Arch Orthop Trauma Surg.* 2002;122(4):200-3.
19. Loew M, Heichel TO, Lehner B. Intraarticular lesions in primary frozen shoulder after manipulation under general anesthesia. *J Shoulder Elbow Surg.* 2005;14(1):16-21.
20. Snow M, Boutros I, Funk L. Posterior arthroscopic capsular release in frozen shoulder. *Arthroscopy.* 2009;25(1):19-23.