



Comparison of Modified Cortical Bone Trajectory Screw and Pedicle Screw for Spinal Reconstruction Surgery

Ivan Gonchar¹, Yoshihisa Kotani^{1*} and Norimasa Iwasaki²

¹Department of Orthopedic Surgery, Steel Memorial Muroan Hospital, Japan

²Department of Orthopedic Surgery, Hokkaido University Graduate School of Medicine, Japan

Abstract

Object: Cortical Bone Trajectory (CBT) is a novel instrumentation technique quickly gaining popularity that offers high screw pullout strength and thus might be a solution to the problem of screw loosening in osteoporotic spine. Original method utilizes short small diameter screws compromising anterior load-sharing and screw strength. We modified CBT (mCBT) to use thicker longer screws for better anchor strength. We report the results of 160 consecutive spine reconstruction cases using mCBT and compare them to Pedicle Screw (PS) outcomes in a cohort of 220 patients with minimum follow-up period of two years.

Methods: A 160 mCBT cases (mean age 71) and 60 PS cases (mean age 66) with 2-year minimum follow-up were included. Pathology included degenerative spine, deformity, osteoporotic collapse, trauma, infection etc. for mCBT and PS groups alike. All patients were operated by the single surgeon. Surgery included MIS-PLF, MIS-TLIF and deformity correction with various MIS techniques. The bone grafts were performed with either iliac bone or local bone mixed with HA granules. The clinical outcomes were assessed with Japanese Orthopedic Association Back Pain Evaluation Questionnaire (JOABPEQ) and VAS scoring. We also evaluated the fusion rates and screw loosening using plain X-rays and CT scans.

Results: All cases were followed for 24 months or more. Mean number of segments fixed per case was 1.9 in mCBT and 2.1 in PS group. Overall 919 mCBTs and 388 PSs were inserted. Mean operation time was 157 min in mCBT and 177 min in PS group. Mean intraoperative bleeding was 167 ml in CBT and 334 ml in PS group. Both groups had significant improvement of JOABPEQ and VAS values at follow-up without significant difference between groups. There was only one case of mCBT loosening (0.6%) and 16 cases of PS loosening (25%). There was one pseudarthrosis in mCBT (fusion rate 99%) and 6 in PS (fusion rate 90%, 3 cases re-operated with mCBT). There were 2 cases of 4.75 mm diameter CBT screw breakage (both successfully fused). There were no cases of screw breakage since we started to insert mCBT screws 5.5 mm or larger diameter.

Conclusion: We introduced CBT to improve anchor strength in osteoporotic spine. We endeavor to improve the bone purchase of original CBT by using thicker and longer screws. Compared to traditional PS, our modified CBT technique demonstrated significantly better fusion rate and significantly less screw loosening. We recommend the use of screws 5.5 mm diameter or larger and greater length. The mCBT was a reliable instrumentation technique for various spinal disorders such as osteoporotic spine, revision surgery, and spinal deformity correction.

Keywords: CBT; PS; JOABPEQ; Spinal deformity correction; Minimally invasive spine stabilization (MIS); Spinal reconstruction; Minimally invasive surgery (MIS)

Introduction

Cortical Bone Trajectory (CBT) is a novel concept in spine instrumentation that is quickly gaining popularity. CBT was developed to increase the pullout strength of posterior vertebral instrumentation in osteoporotic spine [1,2]. However, the strength of CBT screws leads to disproportionate load centering on the pars and the screw insertion point near the base of the spinous process which in clinical practice might lead to pars or pedicle fracture because of the long lever arm acting on the middle and posterior column from the anterior column unsupported by short CBT screws. Thus many experienced surgeons with good understanding of spine biomechanics are reluctant to introduce traditional CBT especially for procedures creating high degrees of mechanical load on the final construction such as deformity correction or PF.

OPEN ACCESS

*Correspondence:

Yoshihisa Kotani, Spine and Spinal Cord Center, Department of Orthopedic Surgery, Steel Memorial Muroan Hospital, Chiribetsu-cho 1-chome 45, Muroan, 0500076, Japan, Tel: +81 0143 44 4650; Fax: +81 0143 47 4354; E-mail: yoshi96k@ja2.so-net.ne.jp

Received Date: 03 Dec 2018

Accepted Date: 26 Dec 2018

Published Date: 28 Dec 2018

Citation:

Gonchar I, Kotani Y, Iwasaki N. Comparison of Modified Cortical Bone Trajectory Screw and Pedicle Screw for Spinal Reconstruction Surgery. Clin Surg. 2018; 3: 2276.

Copyright © 2018 Yoshihisa Kotani. This is an open access article distributed under the Creative Commons Attribution License, which permits unrestricted use, distribution, and reproduction in any medium, provided the original work is properly cited.

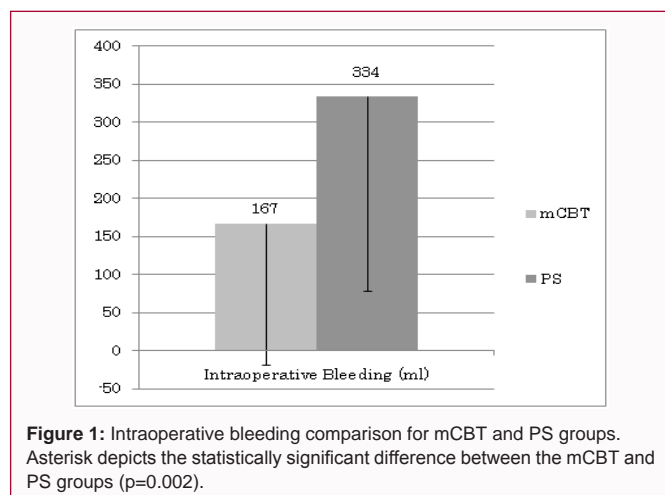


Figure 1: Intraoperative bleeding comparison for mCBT and PS groups. Asterisk depicts the statistically significant difference between the mCBT and PS groups ($p=0.002$).

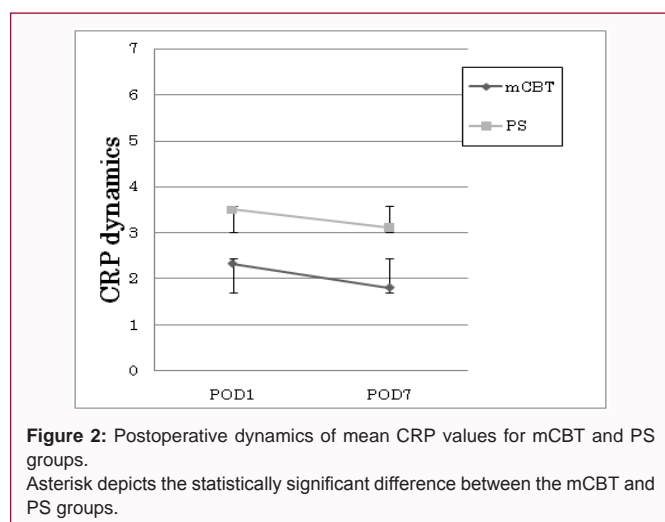


Figure 2: Postoperative dynamics of mean CRP values for mCBT and PS groups. Asterisk depicts the statistically significant difference between the mCBT and PS groups.

The original CBT technique was established for use under C-arm guidance [3,4]. It employs short and small diameter screws to avoid pars fracture and violation of neural foramina by screws. The use of intraoperative CT guided navigation allows to safely inserting long screws of larger diameter to improve anterior load sharing thus increasing reliability of CBT anchors and final construct stability. This modification allowed the authors to successfully utilize CBT anchors for deformity correction and PF.

We report the results of our modified CBT technique in a series of 160 cases including degenerative disease, deformity correction; osteoporotic vertebral collapse etc. The authors prospectively compared indicators of surgical invasiveness, clinical outcomes and rates of screw loosening and pseudarthrosis in our modified CBT series and compared them to traditional PS technique outcomes.

Materials and Methods

Patient demographics: From December 2012 to December 2014, more than two hundred-fifty surgeries for degenerative spine disease, spine deformity, and osteoporotic vertebral collapse, infection of the spine, trauma and metastatic spine tumor were performed at our center with modified CBT technique. Out of this cohort 160 patients with follow-up of at least two years were selected for this study. There were 84 Degenerative Spondylolisthesis (DS), 25 adult deformity cases, 12 Foraminal Stenosis (FS) cases, 6 Lumbar Canal Stenosis

(LCS), 6 Isthmic Spondylolisthesis (IS), 6 osteoporotic vertebral body collapse, 4 cases of trauma, 2 cases of discitis in remission, 2 metastatic tumors, and etc.

Sixty consecutive cases operated with PS during the same period were selected as a control group. The pathology was 16 DS, 13 IS, 12 LCS, 5 adult deformity cases, 5 osteoporotic collapse, 2 FS, 2 disc hernias, 2 infection cases and etc. Both groups were matched for mean age, BMI, previous lumbar surgery, Charlson age corrected comorbidity index, duration of symptoms and PLF/TLIF ratio [5]. There was no significant difference in smoker/nonsmoker ratio between the two groups (Table 1).

Surgical procedures: All surgeries were performed at the same facility by a single surgeon (YK). The single-level lumbar fusion with CBT was performed through a single midline 4 cm incision with neural decompression by bilateral medial facetectomies. The screw insertion starting point was chosen on the medial aspect of pars interarticularis in the area of maximal bone density as visualized on intraoperative CT. Insertion points were also adjusted to alleviate rod application. After the starting point was created with a 3mm surgical burr, the polyaxial CBT screws were inserted through a cranio-lateral trajectory as described by Santoni and Mobbs [3,4]. The trajectory was chosen so that the screw tip would lodge in the upper corner of the vertebral body. In cases of significant instability or foraminal stenosis, we proceeded to perform TLIF with a PEEK cage after applying distraction directly to the CBT screw heads (MIDLf). This was followed by titanium rod application and final screw tightening in compression. Cobalt-chromium rods were used for multilevel cases to prevent loss of correction. The morcellated local bone mixed with artificial bone was then grafted.

Deformity cases underwent anterior release through OLIF approach with lordotic PEEK cage insertion with bone graft followed by posterior instrumentation with mCBT. In most cases, the lumbosacral area was opened allowing L5/S1 TLIF and cantilever correction technique combined with percutaneous mCBT fixation in upper levels (Hybrid PF). To enhance the deformity correction, Sagittal Adjusting Screw (SAS) CBTs were used, in which the direct lordotic correction was performed to gain the effective sagittal plane correction. When pelvic anchors were needed S2 Alar Iliac Screws (S2AIS) were used. The single-level MIS lumbar fusion with PS was performed as we previously reported [6]. In deformity cases posterior open approach was used. In 3 cases sublaminar taping was added for anchor augmentation. One case required HA stick augmentation of the screw tract.

Quantitative analyses of outcomes: The parameters of surgery evaluation included operation time and intraoperative blood loss. Postoperative course was evaluated using CRP and CPK values on POD1 and POD7. The Japanese Orthopedic Association Back Pain Evaluation Questionnaire (JOABPEQ), Back Pain VAS, Lower Extremities Pain VAS, Lower Extremities Paresthesia VAS were used for clinical outcome appraisal [7]. All the questionnaires were filled out by the patients without supervision by a physician. The JOABPEQ and VAS scores were evaluated at preoperatively and 12 months of follow up. The postoperative complications, length of hospital stay in days and discharge destination (home or rehabilitation facility) were registered for all cases. Screw loosening and fusion rates were evaluated by reviewing follow up X-rays and further scrutinized with CT scans.

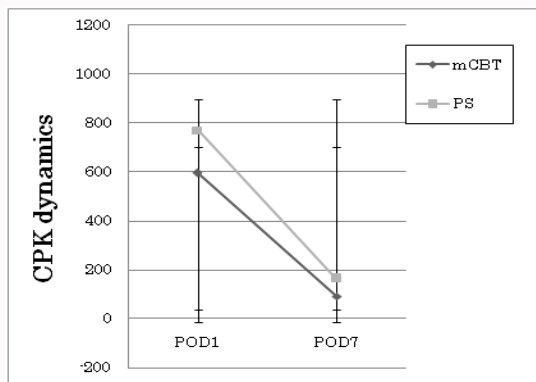


Figure 3: Postoperative dynamics of mean CPK values for mCBT and PS groups. Asterisk depicts the statistically significant difference between the mCBT and PS groups.

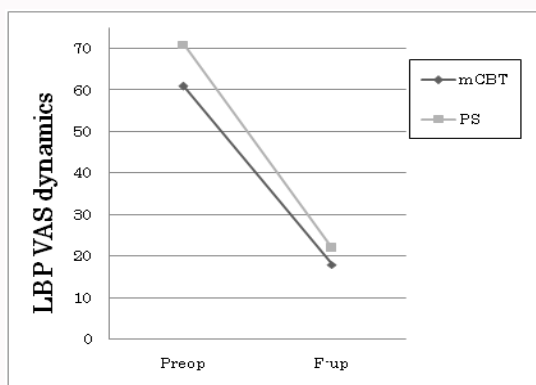


Figure 4: The low back pain VAS score dynamics.

Statistical analysis: The interval data were compared using unpaired Student’s t-test between two groups. The nominal data were compared using the Chi-square. The significance cutoff for both tests was set at $p \leq 0.05$.

Results

Mean number of segments fixed per case was 1.9 in mCBT and 2.1 in PS group. Overall 919 mCBTs and 388 PSs were inserted.

All cases were followed up until at least two-year postop. The average operation time was 157 ± 91 min and 177 ± 66 mins in the CBT and PS groups respectively ($p=0.11$).

The intraoperative blood loss was significantly greater in the PS group (167 ± 186 ml and 334 ± 255 ml in the mCBT and PS groups respectively ($p=0.002$)) (Figure 1). The average serum CRP level on POD1 was 2.33 ± 2.1 and 3.5 ± 2.4 in the mCBT and PS groups respectively ($p=0.004$). The POD7 mean CRP values were 1.8 ± 1.9 and 3.1 ± 4.3 in mCBT and PS groups respectively, which was significantly higher in the PS group ($p=0.003$) (Figure 2). The POD1 mean CPK level was not significantly different but tended to be higher in the PS group (595 ± 995 and 770 ± 481 in the mCBT and PS groups respectively, $p=0.19$). The POD7 mean CPK level was significantly higher in the PS group (92 ± 114 and 163 ± 196 in the mCBT and PS groups respectively, $p=0.001$) (Figure 3). Mean length of hospital stay was somewhat longer for PS group (23 days for PS vs. 17 days for mCBT, $p=0.3$). The fraction of patients who required a transfer to a

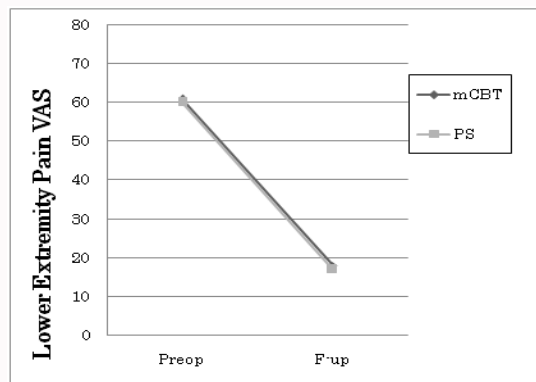


Figure 5: Lower extremity pain VAS score dynamics.

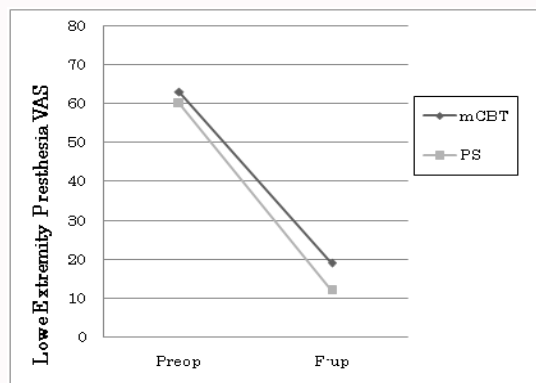


Figure 6: Lower extremity paresthesia VAS dynamics.

rehabilitation facility after discharge was not different but tended to be greater for PS (50% in PS group vs. 43% in mCBT group, $p=0.3$).

The average JOABPEQ effectiveness ratios were not statistically different with best levels of effectiveness demonstrated for pain and walking and lowest effectiveness for psychological disability (Table 2).

The mean preoperative Low Back Pain (LBP) VAS scores were 71.5 and 61.2 in PS and mCBT groups respectively ($p=0.1$). At follow up, the mean LBP VAS scores were 22.6 and 18.0 in PS and mCBT groups respectively (Figure 4). The mean preoperative lower extremity pain VAS scores were 60.6 and 61.7 in PS and mCBT groups respectively. At follow-up the mean lower extremity pain VAS scores improved to 17.7 and 18.6 in PS and mCBT groups respectively (Figure 5). The mean preoperative low extremity paresthesia VAS scores were 60.6 and 63 in PS and mCBT groups respectively. At follow-up the mean low extremity paresthesia VAS scores improved to 12.7 and 19.0 in PS and mCBT groups respectively ($p=0.2$) (Figure 6). No statistically significant differences were observed between any preoperative or follow-up VAS scores between the PS and mCBT groups.

The presence of pseudarthrosis and screw loosening was evaluated on the follow-up X-rays and suspected pseudarthrosis cases were further scrutinized with CT scans. Screw loosening was observed in 15 patients (25% of cases) in PS group and in 3 cases (1.8% of cases) in mCBT group ($p=0.006$). Bony fusion was achieved in 53 cases in PS group (90%) and in 157 cases in mCBT group (98%). This difference was statistically significant by Chi-square ($p=0.006$). One nonunion in mCBT group required revision and achieved fusion

Table 1: Background data comparison of two surgical groups.

	mCBT	PS	Significance
Number of cases	160	60	
Gender (M:F)	53:107	26:34:00	NS
Age	69 ± 11	66 ± 17	NS
BMI	24.7 ± 3.7	23.7 ± 3.7	NS
Smoker	13%	14%	NS
Previous lumbar surgery	21%	20%	NS
Age corrected Charson comorbidity index	3.4 ± 1.5	3.1 ± 1.7	NS
Duration of Symptoms (months)	28 ± 43	35 ± 97	NS

Mean ± SD

NS: No Significant difference between two groups

and 2 cases were asymptomatic. Two pseudarthrosis in PS group required revision with mCBT screws and eventually achieved fusion and 4 cases were asymptomatic.

There were two cases of 4.75 mm diameter CBT screw breakage (both successfully fused). There were no cases of screw breakage since we started to insert mCBT screws 5.5 mm or larger diameter.

There were 2 intraoperative screw perforations resolved by reinsertion during the index surgery, 4 CSF leaks, 5 superficial wound infections, one compartment syndrome due to superficial percutaneous rod introduction, 2 postop deliriums and one ischemic colitis in the mCBT group. All complications in mCBT group resolved after conservative treatment.

In PS group there was one deep wound infection requiring construct removal, one deep hematoma requiring reoperation, one rod dislodgement, 1 CSF leak, 1 screw perforation requiring intraoperative removal, and 1 postop pneumonia.

Discussion

Fast increase of elderly population serves as an impetus in recent search for methods to increase the strength of anchors for spinal instrumentation in the osteoporotic vertebrae. Augmenting the screw tract bone with artificial bone or cement and sub laminar wiring or taping have been introduced but failed to attain a golden standard status due to insufficient anchoring strength gain and significant hazards.

The CBT technique is a concept of screw insertion into the densest bone available creating a screw tract that contacts as much cortical bone as possible from a posterior approach to a vertebra.

Original CBT was developed for insertion under fluoroscopy and for that reason relies on bone surface landmarks for insertion point selection. Also the instrumentation under 2 dimensional imaging necessitates strict adherence to standardized trajectory to reduce screw perforation rates and pars fracture incidence to minimum [8]. This also restricts the screw choice to short screws of small diameter because unlike pedicle screws the CBTs are comparatively easy to cause perforation due to their intentional proximity to medial pedicle wall and vertebral body surface. However, even under the condition of strict adherence to original technique the original CBTs have significant pars fracture rates, screw breakage rates and perforation rates.

Furthermore, the strict confinement of original CBT insertion point to the medial aspect of the lamina hampers rod introduction

Table 2: Comparison of JOABPEQ effectiveness rates.

	mCBT	PS	Significance
Pain	83%	80%	NS
Function	67%	64%	NS
Walking	90%	81%	NS
Social	62%	71%	NS
Psychological	51%	47%	NS

NS: No Significant difference between two groups

in long fusion cases and when CBTs have to be aligned with pedicle screws or pelvic anchors. The insertion point is also in close proximity to spinous process which may cause the rod to collide with the bone in cases when spinous process is preserved such as percutaneous instrumentation.

Also, traditional CBT screw head location at the caudal pole of facet joint surface carries a risk of postoperational facet joint disturbance that is almost completely absent when pedicle screws are used as anchors. The above mentioned demerits of traditional CBT method are accountable for the insufficient spread of the technique especially for long fusion cases such as deformity correction for degenerative scoliosis, and for percutaneous instrumentation cases.

All these problems can be resolved with our modified CBT (mCBT) technique for which we utilize a 3 dimensional imaging modality such as intraoperative CT with navigation. 3D navigation obviates the dependence on bone surface landmarks because it allows the surgeon to look inside the bone to locate the densest bony area of lamina away from facet surface and the spinous process to choose a safe location for high torque anchor starting point reasonably aligned for a smooth rod introduction. Moreover, the trajectory itself does not need to rely on cortical bone alone. Vertebral body bony islands, bony spurs, cranial endplate of caudal vertebra in an instrumented segment, the promontorium of S1 vertebra can be intentionally purchased to increase the anchor strength. 3D navigation allows avoiding inserting the CBTs dangerously close to the pedicle wall or the vertebral body wall or the anterior vascular structures without reliance on short puny screws. In fact in our practice there were no pars fractures, symptomatic perforations or screw breakage incidence of long large diameter CBT screws inserted under 3D navigation (mCBT technique). Using long screws of course also means good anterior load sharing which allows us to use mCBT anchors for deformity correction involving derotation, sagittal correction maneuvers, distraction and compression with minimal loosening even in osteoporotic bone.

While being burly and long the mCBTs by all means retain all the advantages that the original CBT technique boasts over pedicle screws: mCBTs do not need exposure lateral to the facet joint thus preventing any damage to the posterior spinal nerve rami; the insertion torque is very high; intraoperative bleeding is significantly less; loosening rate is significantly lower; fusion rate is significantly higher [9]. The CBTs are also very versatile for PS nonunion revision because the CBT trajectory doesn't suffer from bone weakening after PS removal [10,11].

There are several limitations in this study. The study included non-homogenous groups in terms of spinal disorders, fixed spinal levels, and operative procedures. It was realistic study design in which gender, spinal disorders and procedures would be standardized. As this study first evaluated the overall trend of clinical outcome between

modified CBT and PS group, the future study should be planned in more standardized fashion with prospective study design.

Conclusion

The mCBT was a reliable instrumentation technique for various spinal disorders such as osteoporotic spine, revision surgery, and spinal deformity correction, when compared to conventional pedicle screws.

References

1. Kojima K, Asamoto S, Kobayashi Y, Ishikawa M, Fukui Y. Cortical bone trajectory and traditional trajectory--a radiological evaluation of screw-bone contact. *Acta Neurochir (Wien)*. 2015;157(7):1173-8.
2. Matsukawa K, Yato Y, Kato T, Imabayashi H, Asazuma T, Nemoto K. *In vivo* Analysis of Insertional Torque During Pedicle Screwing using Cortical Bone Trajectory Technique. *Spine (Phila Pa 1976)*. 2014;39(4):E240-5.
3. Mobbs RJ. The "medio-latero-superior trajectory technique": an alternative cortical trajectory for pedicle fixation. *Orthop Surg*. 2013;5(1):56-9.
4. Santoni BG, Hynes RA, McGilvray KC, Rodriguez-Canessa G, Lyons AS, Henson MA, et al. Cortical bone trajectory for lumbar pedicle screws. *Spine J*. 2009;9(5):366-73.
5. Charlson ME, Pompei P, Ales KL, MacKenzie CR. A new method of classifying prognostic comorbidity in longitudinal studies: Development and validation. *J Chronic Dis*. 1987;40(5):373-83.
6. Kotani Y, Abumi K, Ito M, Sudo H, Abe Y, Minami A. Mid-term clinical results of minimally invasive decompression and posterolateral fusion with percutaneous pedicle screws versus conventional approach for degenerative spondylolisthesis with spinal stenosis. *Eur Spine J*. 2012;21(6):1171-7.
7. Fukui M, Chiba K, Kawakami M, Kikuchi S, Konno S, Miyamoto M, et al. JOA Back Pain Evaluation Questionnaire (JOABPEQ)/JOA Cervical Myelopathy Evaluation Questionnaire (JOACMEQ). The report on the development of revised versions. April 16, 2007. The Subcommittee of the Clinical Outcome Committee of the Japanese Orthopaedic Association on Low Back Pain and Cervical Myelopathy Evaluation. *J Orthop Sci*. 2009;14(3):348-65.
8. Iwatsuki K, Yoshimine T, Ohnishi Y, Ninomiya K, Ohkawa T. Isthmus-guided cortical bone trajectory for pedicle screw insertion. *Orthop Surg*. 2014;6(3):244-8.
9. Ueno M, Sakai R, Tanaka K, Inoue G, Uchida K, Imura T, et al. Should we use cortical bone screws for cortical bone trajectory? *J Neurosurg Spine*. 2015;22(4):416-21.
10. Calvert GC, Lawrence BD, Abtahi AM, Bachus KN, Brodke DS. Cortical screws used to rescue failed lumbar pedicle screw construct: a biomechanical analysis. *J Neurosurg Spine*. 2015;22(2):166-72.
11. Pacione D, Kim I, Wilson TA, Frempong-Boadu A. Cortical screw trajectory for instrumentation and fusion in the setting of osteopathic compression fracture allows for percutaneous kyphoplasty for adjacent level compression fractures. *J Clin Neurosci*. 2015;22(5):899-904.