



Combined Surgical Treatment of Lung Cancer and Atrial Fibrillation – First Experience

Ales Mokravec^{1,2}, Vojtech Kurfirst^{1,2*}, Julia Csanady¹ and Vladislav Hytych³

¹Department of Cardiothoracic Surgery, Hospital of Ceske Budejovice, The Czech Republic

²University of South Bohemia in Ceske Budejovice, The Czech Republic

³Department of Thoracic Surgery, Thomayer Hospital in Prague, The Czech Republic

Abstract

Lung malignancies are accompanied by a number of complications which include disorders of hemostasis, such as bleeding or thrombosis or systemic embolism. This risk is even higher in patients with atrial fibrillation. We describe a case of a combined surgical approach in a patient with cancer of the left upper lobe of the lung and chronic atrial fibrillation after a stroke.

Keywords: Lung cancer; Atrial fibrillation; Stroke

Case Presentation

A 79-year-old patient after right hemicolectomy for adenocarcinoma was admitted for unverified tumor of the upper lobe of the left lung with mediastinal lymphadenopathy (Figure 1). Other diseases included atrial fibrillation, arterial hypertension, dyslipidemia and overweight. In the past, the patient overcame ischemic stroke on the effective anticoagulant therapy without subsequent neurological residue. After spirometric examination the patient was evaluated as being able to undergo resection to the extent of lobectomy. The study was approved by the local ethics committee. First, the patient underwent video mediastinoscopy with mediastinal lymph node biopsy and these were tumor negative. Based on a joint decision of the thoracic and heart teams, the patient was indicated for combined surgery – left upper lobectomy and exclusion of the left atrial appendage. The surgery was performed with selective ventilation in the right flank position from a limited 5 cm anterolateral thoracotomy. Then, another working port was intentionally introduced to load the ENDOCAMERA. This was followed by opening of the mediastinal pleura, isolation of the upper pulmonary vein when verifying the presence and course of the lower pulmonary vein, and this was interrupted by a stapler suture. Next, the upper lobar bronchus was isolated and interrupted by a endo-stapler suture. Finally, the upper lung lobe, including the adjacent branches of the left pulmonary artery, was resected using staplers. Furthermore, mediastinal node dissection was performed due to tumor staging. This was followed by the cardiac surgery part of the procedure from the current approach with the opening of the pericardial cavity dorsally from the phrenic nerve. Under transesophageal echocardiography control, the left atrial appendage was excluded with a 40 mm Atriclip (AtriCure, West Chester, USA) (Figure 2). The procedure was completed by chest drainage with two silicone drains. Histological examination confirmed invasive squamous cell carcinoma and the obtained mediastinal nodes were tumor negative. The patient was discharged from the hospital in a cardiopulmonary compensated condition with a favorable X-ray finding.

OPEN ACCESS

*Correspondence:

Vojtech Kurfirst, Department of Cardiothoracic Surgery, Hospital of Ceske Budejovice, Bozeny Nemcove 54, Ceske Budejovice 37001, The Czech Republic, Tel: 00420777237299; E-mail: vojtech.kurfirst@post.cz

Received Date: 05 Jan 2021

Accepted Date: 20 Jan 2021

Published Date: 22 Jan 2021

Citation:

Mokravec A, Kurfirst V, Csanady J, Hytych V. Combined Surgical Treatment of Lung Cancer and Atrial Fibrillation – First Experience. Clin Surg. 2021; 6: 3040.

Copyright © 2021 Vojtech Kurfirst.

This is an open access article distributed under the Creative Commons Attribution License, which permits unrestricted use, distribution, and reproduction in any medium, provided the original work is properly cited.

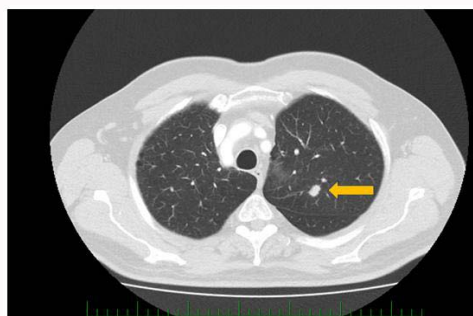


Figure 1: Unverified tumor of the upper lobe of the left lung with mediastinal lymphadenopathy.

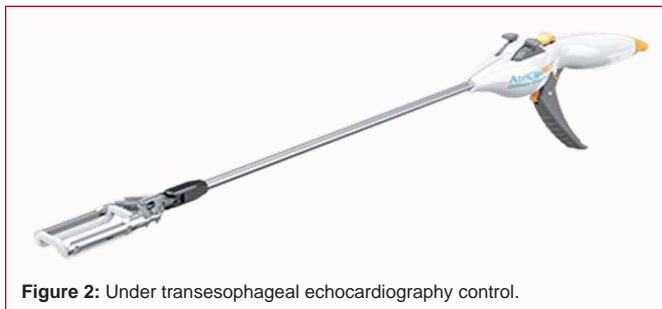

Figure 2: Under transesophageal echocardiography control.

Atrial fibrillation was present on the ECG, so anticoagulant therapy with Warfarin was continued.

Discussion

Atrial fibrillation is the most common arrhythmia, with an incidence of 1% to 2% in the European population and an even higher incidence in the cancer population (almost 10% according to some data) [1,2]. The etiology of atrial fibrillation is also different in cancer patients. Arterial hypertension is used as a general risk factor, in addition to direct or indirect tumor action, secondary myocardial ischemia in anemia, metabolic abnormalities caused by disease or treatment, and direct cardiotoxic action of oncological treatment (cDDP, ifosfamide, taxanes, gemcitabine, 5-FU, etoposide). Due to the procoagulant tendency of the organism, a CHA₂DS₂-VASc score is automatically achieved in these patients, which justifies permanent anticoagulant therapy. The most common medicament for permanent anticoagulation is Warfarin, which is frequently not recommended for possible bleeding complications. Warfarin is one of the drugs with the highest percentage of interactions, both pharmacokinetic and pharmacodynamics. In the distribution phase, it binds up to 95% to 99% to albumin, and only its free fraction is effective. The level of albumin can fluctuate significantly in cancer patients due to anorexia or nausea, which does not allow maintaining a stable INR level and thus the optimal effect for the patient. A place for new p.o. anticoagulants has not yet been precisely determined, therefore LMWH is recommended as an anticoagulant therapy of first choice. From oncological patients, patients with cancer of the pancreas, lung, colon and rectum have the highest risk of ischemic brain attack [3]. The most common source of thromboembolism is then the left atrial appendage. The surgical closure of the left atrial appendage for lowering risk of embolic events in patients with atrial fibrillation can

be performed by the classic surgical route (resection, suture) or by the instrumental route (stapler, Atriclip, endoloop) from left-sided videothoracoscopy, where these methods have different results [4]. In non-small cell lung tumors in stages I, II and IIIa, radical tumor resection (atypical resection, lobectomy, pneumectomy) is the method of choice. The operation is standardized and commonly used both in the classical form (thoracotomy) and preferably using minimally invasive methods (VATS: Video Assisted Thoracoscopic Surgery; RATS: Robotic Assisted Thoracoscopic Surgery) [5]. The possibility of combining both procedures represents an extension of the range of treatment options that we can offer to patients with lung malignancies and rhythm disorders within a very close interdisciplinary cooperation.

Conclusion

Given the growing number of patients with concomitant lung cancer complicated by cardiac arrhythmias with embolism, this case is the basis of a larger multicenter study, the results of which would support the benefits of a combined surgical approach in these patients. In addition to the surgical treatment of oncological disease, it is also possible to focus only on exclusion of the left atrial appendage or to perform a complete ablation procedure.

References

1. Yang X, Li X, Yuan M, Tian C, Yang Y, Wang X, et al. Anticancer therapy-induced atrial fibrillation: Electrophysiology and related mechanisms. *Front Pharmacol.* 2018;9:1058.
2. Garcia-Fernandez FJ, Ibanez Criado JL, Quesada Dorador A. Spanish Catheter Ablation Registry. 17th official report of the Spanish Society of Cardiology Working Group on electrophysiology and arrhythmias (2017). *Rev Esp Cardiol.* 2018;71:941-51.
3. D'Souza M, Carlson N, Fosbol E. CHA₂DS₂-VASc score and risk of thromboembolism and bleeding in patients with atrial fibrillation and recent cancer. *Eur J Prev Cardiol.* 2018;25:651-8.
4. Caliskan E, Sahin A, Yilmaz M, Seifert B, Hinzpeter R, Alkadhhi H, et al. Epicardial left atrial appendage AtriClip occlusion reduces the incidence of stroke in patients with atrial fibrillation undergoing cardiac surgery. *Ep Europace.* 2018;20(7):e105-e114.
5. Flores RM, Park BJ, Dycoco J, Aronova A, Hirth Y, Rizk N P, et al. Lobectomy by Video-Assisted Thoracic Surgery (VATS) versus thoracotomy for lung cancer. *J Thorac Cardiovasc Surg.* 2009;138(1):11-8.