



Colonic Phytobezoar: An Unexpected Cause of Large Bowel Obstruction

Farhanul Huda*, Somprakas Basu, Prateek Sharda, Saumya Agrawal and Siddharth Verma

Department of General Surgery, All India Institute of Medical Sciences, Rishikesh, India

Abstract

Colonic phytobezoar is a rare cause of large bowel obstruction and may pose a diagnostic challenge. We report our experience with a case of colonic phytobezoar presenting as sigmoid volvulus. A 22 year old male presented with clinical features of acute large bowel obstruction. X-Ray and sonography of the abdomen revealed gross dilatation of large bowel suggestive of intestinal obstruction. A provisional diagnosis of sigmoid volvulus was made and the patient was taken up for exploratory laparotomy. On exploration, the cause of large bowel obstruction was impacted phytobezoar at the rectosigmoid junction.

Keywords: Colonic phytobezoar; Intestinal obstruction; Rectosigmoid

Introduction

Bezoar is derived from the Arabic word “badzehr” meaning antidote or antivenom¹. Bezoars are masses which are formed by the condensation of poorly digestible or indigestible products in the gastrointestinal tract [1]. There are four types of bezoars: a trichobezoar is made up of ingested hairs, a phytobezoar of non-digestible fibers such as cellulose, hemicellulose, lignin and fruit tannins, pharmacobezoars consist of drugs like antacids, cholestyramine, resins, kayexalate, which when taken in large amounts agglutinate and produce a mass, and lactobezoars seen in infants and consists of milk curd which form secondary to infant formula [2].

The complications caused by bezoars include mechanical irritation, mucosal ulceration leading to bleeding, intestinal obstruction or in severe cases perforation peritonitis [3]. Intestinal obstruction caused by bezoars is rare and constitutes only 0.4% to 4% of all causes of intestinal obstruction, mainly occurring in the stomach and small bowel [4]. Bezoar as a cause of colonic obstruction is still rarer and sometimes is confused with neoplasia, volvulus or gallstone ileus [5].

The present report describes the clinical course of a patient of colonic phytobezoar with an initial suspicion of sigmoid volvulus.

Case Presentation

A 22 year old male presented to the emergency with complaints of non passage of stools, abdominal distension and pain since 15 days and non passage flatus since 1 day. Abdominal distension was progressively increasing and was associated with vomiting and abdominal pain. The pain was intense, classified as 8 on a 0-10 verbal numerical scale. He denied any recent change in bowel habits, per rectal bleeding or change in faecal consistency or odour. On examination the patient had tachycardia, was normotensive and afebrile. On her abdomen examination, abdomen was distended, tender and tense in all the quadrants, had a tympanic note and bowel sounds were absent on auscultation. Digital rectal examination revealed the absence of feces, blood or mucus in the rectum. Laboratory investigations revealed a TLC of 13000/mm³ with neutrophilia. The liver function test, coagulation profile and basic metabolic panel were within normal limits. Plain X-ray abdomen showed significant dilation of bowel loops (more than 5 cm). On ultrasonography of abdomen patient had grossly distended bowel loops showing to and fro peristalsis likely suggestive of acute intestinal obstruction with inter-bowel free fluid. During the workup the patient developed fever and hypotension and was taken up for exploratory laparotomy with the provisional diagnosis of sigmoid volvulus. The abdomen was opened by midline vertical incision. On exploration, whole of the transverse and sigmoid colon up to the rectosigmoid junction was grossly dilated. The bowel was not ischemic and there were no impending perforations. There was no rotation of the sigmoid mesentery. Resection of the dilated sigmoid colon and descending colon was done. As the discrepancy in the size of lumen of the proximal and distal ends of bowel was huge, a proximal end

OPEN ACCESS

*Correspondence:

Farhanul Huda, Department of General Surgery, All India Institute of Medical Sciences, Veerbhadra Road, Rishikesh 249203, Uttarakhand, India, Tel: +91 9997533211; E-mail: farhanul1973huda@gmail.com

Received Date: 31 Jan 2019

Accepted Date: 22 Feb 2019

Published Date: 26 Feb 2019

Citation:

Huda F, Basu S, Sharda P, Agrawal S, Verma S. Colonic Phytobezoar: An Unexpected Cause of Large Bowel Obstruction. *Clin Surg*. 2019; 4: 2347.

Copyright © 2019 Farhanul Huda. This is an open access article distributed under the Creative Commons Attribution License, which permits unrestricted use, distribution, and reproduction in any medium, provided the original work is properly cited.

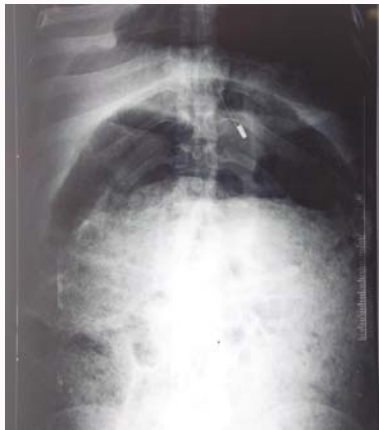

Figure 1: Straight X-ray Abdomen (erect) at the time of presentation.

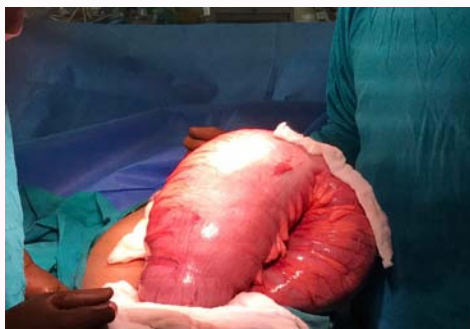

Figure 2: Massively dilated colon intraoperatively.

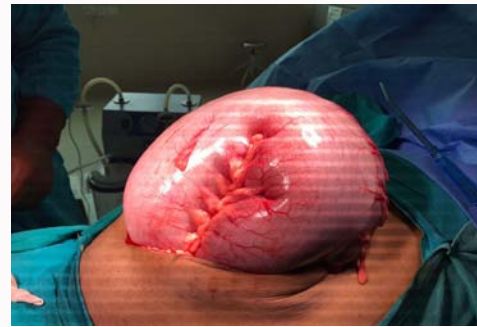


Figure 3: Hugely dilated colon, ready to pop out as soon as the abdomen was opened up.



Figure 4: The phytobezoar that was removed from the sigmoid colon.

colostomy with closure of distal stump was done. On opening up the Specimen a large phytobezoar along with fecalith was impacted at the rectosigmoid junction.

The patient's postoperative recovery was uneventful. He was allowed per orally on the 3rd postoperative day and was discharged on the 7th postoperative day.

Discussion

Bezoars are a rare cause of intestinal obstruction. They most commonly occur in the stomach as the pyloric sphincter prevents further propagation of the mass in the small intestines. Bezoars formed primarily in the small bowel become impacted in the terminal ileum or sometimes in the jejunum and almost always present with intestinal obstruction [2]. Colonic obstruction caused by phytobezoar is an even rarer entity and has only been published in case reports.

The pre disposing factors for bezoar formation in adults are previous gastrointestinal surgery, diabetic gastroparesis, inadequate mastication due to poor dentition, intake of drugs which decrease the gastrointestinal motility, muscular dystrophy, renal failure, psychiatric illness, Gullian-Barre syndrome, cystic fibrosis or hypothyroidism [4]. None of these risk factors were present in our patient. Phytobezoars are formed as a result of the interaction between the compounds found in leguminosae and shibuol and tannins found in fruits with gastric acid which results in the formation of a structure that accumulates cellulose and other proteins. The clinical manifestations of patients with colonic phytobezoar are abdominal pain, distension, diarrhoea or constipation and anorexia and weight loss. If there is delay in treatment they may present with

intestinal obstruction, as in our case, or perforation with consequent peritonitis [4]. Diagnosing colonic bezoars can be quiet demanding and is usually made with radiological investigations. Abdominal radiographs may reveal a mixed density mass with interspersed air foci within giving a mottled appearance. They can be easily mistaken for an abscess or feces in the colon. As reported by Verstanding et al. conventional radiographs identify bezoars in only 10% of cases. On ultrasonography the presence of an intraluminal mass with a hyperechoic arc like surface and a marked acoustic shadow is suggestive of phytobezoar. However due to the excessive dilatation of bowel loops in our patient the mass could not be visualised on ultrasonography. Abdominal CT scan is a good diagnostic modality in evaluating the cause, level and degree of intestinal obstruction. The characteristic CT image of colonic phytobezoar is that of a well defined intraluminal mass with air bubbles retained within the interstices with proximal dilatation of bowel loops. However due to the deteriorating condition of our patient abdominal CT could not be done. Many authors have described the use of endoscopy as a diagnostic as well as a therapeutic tool in this condition. The goal of treatment of colonic bezoars is removal of the mass and prevention of recurrence. There are several treatment option available for this condition which depend according to the location, size and presence of complications [4]. Conservative management consisting of digital evacuation and enemas is considered in uncomplicated cases. Invasive procedures like sigmoidoscopy or colonoscopy may be used if conservative approach fails. Finally, surgery is mandatory if the endoscopic treatment fails or if the patient presents with complications. In our case, the patient underwent laparotomy as he presented with intestinal obstruction.

Conclusion

Colonic bezoar is a rare cause of intestinal obstruction and its

diagnosis can be challenging. It should be considered in patients with risk factors that are already mentioned in the previous section. CT seems to be the main diagnostic tool. Treatment can be conservative, endoscopic or surgery. The choice of treatment depends on the patient's condition and the presence of complications.

References

1. Mery CM, Pappas AN, Bueno R, Mentzer SJ, Lukanich JM, Sugarbaker DJ, et al. Relationship between a history of antecedent cancer and the probability of malignancy for a solitary pulmonary nodule. *Chest*. 2004;125(6):2175-81.
2. Ersoy E, Ozdogan M, Kulaçoglu H, Gundogdu H. Retained foreign body in the axillary region. *East Mediterr Health J*. 2008;14(5):1222-4.
3. Ando A, Hatori M, Hagiwara Y, Isefuku S, Itoi E. Imaging features of foreign body granuloma in the lower extremities mimicking a soft tissue neoplasm. *Ups J Med Sci*. 2009;114(1):46-51.
4. Yazici B, Sever AR, Mills P, Fish D, Jones S, Jones P. A rare cause of breast mass that mimics carcinoma: Foreign body reaction to amorphous surgical material. *Wien Klin Wochenschr*. 2007;119(15-16):497-9.
5. Adams ST, Cox J, Rao GS. Axillary silicone lymphadenopathy presenting with a lump and altered sensation in the breast: a case report. *J Med Case Reports*. 2009;3:6442-7.