



## Clinical Experiences for Oncoplastic Breast Surgery Improve a Cosmetic Outcome and Reduce Postoperative Complications

Yuko Kijima<sup>1,2,3\*</sup>, Munetsugu Hirata<sup>3</sup>, Yoshiaki Shinden<sup>3</sup>, Toshiaki Utsumi<sup>1</sup>, Zenichi Morise<sup>2</sup> and Shoji Natsugoe<sup>3</sup>

<sup>1</sup>Department of Breast Surgery, Fujita Health University, Japan

<sup>2</sup>Department of Digestive Surgery, Fujita Health University, Japan

<sup>3</sup>Department of Digestive Surgery, Breast and Thyroid Surgery, Kagoshima University Graduate School of Medical and Dental Sciences, Japan

### Abstract

**Purpose:** We evaluate perioperative and cosmetic results of Oncoplastic Breast Surgery (OBS) for the Japanese patients with ptotic breasts according to time after introduction of this method. The study aims to investigate the effect of experience for new surgical technique in breast surgery.

**Methods:** From March 2006 to December 2014, we performed OBS with volume displacement, combining partial mastectomy with reduction mammoplasty, for consecutive 57 patients with ptotic breasts in Kagoshima University Hospital. They were diagnosed having with early breast cancer indicated for partial mastectomy and did not receive any preoperative systemic therapy. Out of 57 patients, forty patients received volume displacement surgery on contralateral healthy breasts immediately. We retrospectively analyzed their perioperative results, postoperative complications, and cosmetic results according to time after we started OBS; early phase and late one.

**Results:** On both phases, patient's age, menopausal status, body mass index, systemic disease, smoking, tumor location, axillary operation and operation type of OBS, there were no significant difference. Operation period and plastic period were significantly shorter in late phase than in early one (<0.05), while there were no significant differences in intraoperative bleeding, weight of resected breast tissue, pathological margins in both phases. A rate of vascular disorder of nipple-areola were fewer in late phase (<0.05), while there were no significant differences between two phases in rates of fat necrosis, hyperplastic disorder of the scar. On cosmetic evaluation, it was improved in late phase that percentages of excellent-good case on both phases were 85% and 100%, respectively.

**Conclusion:** The techniques of OBS with volume displacement were improved perioperative, postoperative and cosmetic results after clinical experience in one institution.

**Keywords:** Breast cancer; Oncoplastic breast surgery; Ptotic breast; Volume displacement; Breast reduction

### Introduction

Oncoplastic Breast Surgery (OBS) combining partial mastectomy with reduction mammoplasty and recentralization of Nipple-Areola Complex (NAC) for early breast cancer is widely practiced. We have introduced OBS for Japanese patient and revealed that it is suitable approach both in oncological and cosmetic reasons for Asian female whose breasts are not so large compared to Western female. It is necessary for us to report focusing in operation results, postoperative complication and cosmetic results by phase after introduction of OBS in one institution. We would like to retrospectively clarify whether there is technical acquisition for new approach and clinical experience influences the results of OBS.

### Patients and Methods

Fifty-seven consecutive Japanese patients were diagnosed with early breast cancer in ptotic breasts between March 2006 and December 2014 and underwent OBS combining partial mastectomy with reduction mammoplasty and re-centralization of nipple-areola without any neoadjuvant systemic therapy. Of these patients, forty patients underwent contralateral operation for symmetrical results.

### OPEN ACCESS

#### \*Correspondence:

Yuko Kijima, Department of Breast Surgery, Fujita Health University, School of Medicine, 1-98, Dengakugakubo, Kutsukakecho, Toyoake, Aichi 470-1192, Japan, Tel: 815629041; Fax: 81562933178;

E-mail: [ykijima@fujita-hu.ac.jp](mailto:ykijima@fujita-hu.ac.jp)

Received Date: 01 Sep 2018

Accepted Date: 05 Oct 2018

Published Date: 09 Oct 2018

#### Citation:

Kijima Y, Hirata M, Shinden Y, Utsumi T, Morise Z, Natsugoe S. Clinical Experiences for Oncoplastic Breast Surgery Improve a Cosmetic Outcome and Reduce Postoperative Complications. *Clin Surg*. 2018; 3: 2145.

Copyright © 2018 Yuko Kijima. This is an open access article distributed under the Creative Commons Attribution License, which permits unrestricted use, distribution, and reproduction in any medium, provided the original work is properly cited.

**Table 1:** Patients characteristics.

	Early phase (n=20)	Late Phase (n=20)	P Value
Patients age (average) y.o.	64 (47-76)	64 (42-73)	NS
Menopausal status			
Pre menopausal	2	3	NS
Post menopausal	18	17	
Body mass index			
<25	5	12	P<0.05
>=25	15	8	
Systemic disease, smoking			
None	7	12	NS
Hypertension	6	6	
Diabetes mellitus	4	0	
Smoker	1	0	
Psychological disorder	2	2	
Tumor location			
Upper	1	3	NS
Upper inner	1	5	
Upper outer	3	2	
Lower	2	1	
Lower inner	2	3	
Lower outer	9	3	
Central	2	3	

**Table 2:** Type of operation.

	Early phase (n=20)	Late phase (n=20)	P value
OBS			
Periareolar mammoplasty	2	9	NS
Lateral mammoplasty	3	2	
J-mammoplasty	8	1	
L-mammoplasty	0	2	
Horizontal mammoplasty	2	0	
Vertical scar mammoplasty	2	0	
Inverted-T mammoplasty	2	6	
Amputation and NA grafting	1	0	
Axillary dissection			
Yes	4	1	NS
No (SNB*)	16	19	

\*: SNB: Sentinel Lymph Node Biopsy

Indications for oncoplastic surgery combining partial mastectomy with reduction mammoplasty were as follows: (1) ptotic (the nipple level was beneath the inframammary line) or large breasts; (2) without any severe systemic disease; and (3) informed consent being obtained preoperatively after an explanation of the surgical procedures. We divided them into two groups retrospectively, early phased: from March 2006 to July 2011, and late phase: from August 2011 to December 2014. There are twenty patients in each group. During that period, two experienced surgeons were in charge in operations. None of them received preoperative systemic chemo- or endocrine therapy. The mean age of patients was 64.0 years (range: 47-76) and 64 .0 years (range: 42-73), and two and three patients were premenopausal in early phase group and late one, respectively.

**Table 3:** Pathological findings and postoperative therapy.

	Early phase (n=20)	Late phase (n=20)	P value
TNM Classification [4]			
0	3	0	NS
IA	13	17	
IIA	0	2	
IIB	0	1	
Pathological margin*			
(mm, average)	14.1	13.6	NS
Axillary dissection			
Yes	4	1	NS
No (SNB**)	16	19	

\*: distance from margin to nearest invasive lesion or intraductal lesion

\*\* : SNB: Sentinel Lymph Node Biopsy

Patients with over 25 of body mass index were 15 and 8 in both groups, statistically much more in early phase than that of late phase (P<0.05). Out of 20 patients in both groups, seven and twelve patients were free from medication due to systemic disease. One patient in early phase group is a smoker. Six patients in both groups received medication for hypertension, diabetes mellitus and psychological disorder, respectively (Table 1). Assessment of resected specimens of breast cancer and stage classification was carried out in accordance with the TNM Classification of Malignant Tumours 6<sup>th</sup> edition [1].

**Tumor location**

Five and 10 lesions located on upper area (upper, upper inner, and upper outer area) in early and late phase, respectively. In the same manner, 13 and 7 lesions located on lower area, and 2 and 3 lesions located on the central area, respectively (Table 1).

**Selection of OBS**

Kind of OBS was selected mainly depend on the tumor location, tumor size and the excessive skin and gland depend on patient's breast size and shape by one surgeon (Y.K).

Patients had a consultation with the breast surgeon at least twice and more to conduct the type of operation, and the procedure. They have been also explained different surgical options to the patient, e.g., other oncoplastic surgical techniques such as immediate volume displacement using a free graft or local flap [2,3]. On two days before surgery the resection area was drawn together with a surgical margin of at least 2.0 cm with the patient in a supine position. We carried out the method to experience for the first time in reference to a literature [4-6].

**Informed consents**

All patients signed informed consent to participate in the study.

**Pathological examination**

Two or three pieces of surgical margins were examined to confirm being negative for cancer involvement intraoperatively. For pathological diagnosis, all pieces of permanent sections cut by every 5 mm were examined postoperatively.

**SLN biopsy and axillary lymphadenectomy**

SLN biopsy using the RI and dye method was performed in patients with clinically diagnosed as node-negative. SLNs were biopsied and examined histologically during surgery. If SLN was positive for metastasis, axillary lymphadenectomy was planned.

### Cosmetic assessment

A digital camera with a resolution of 14.1 megapixels was used with a blue panel as the background. Photographs were taken in four positions with the patient standing on floor marks: facing the camera with their arms down, facing the camera with their arms up, from the left side with their arms up, and from the right side with their arms up. Images were recorded, printed out and then cosmetically measured and evaluated by two parsons (Y.K and M.H) independently.

Cosmetic assessment after breast-conserving therapy reported by Sawai's group supported the Japanese Breast Cancer Society [7]. This assessment contains eight items: 1. breast size, 2. breast shape, 3. wound scar, 4. softness of the breast, 5. shape and size of nipple-areola, 6. color of nipple-areola, 7. level of nipple (difference of distance from suprasternal notch in bilateral nipples), and 8. Lowest point of the breast (difference of bilateral breasts). The cosmetology was evaluated as excellent when the total score was 12 points, good when it was 9 to 11, fair when it was 5 to 8 and poor when it was 0 to 4.

### Statistical analysis

Statistical significance was analyzed by the chi square test and t test.

## Results

### OBS using partial mastectomy with reduction mammoplasty

Reduction types of surgery selected in this study were shown in Table 2. Periareolar mammoplasty [8-9], lateral mammoplasty, J-mammoplasty [10], L-mammoplasty, Horizontal mammoplasty [11], vertical scar mammoplasty [11], inverted-T mammoplasty [12,13], and amputation and NA grafting [14,15] were selected due to tumor location, degree of breast ptosis, and necessity of nipple resection because of ductal spreading. We experienced the operation procedure and learned perioperative results each case, so we sometimes chose another kind of OBS even if both of tumor side factor and a host side factor were same.

### Axillary operation

Axillary lymph nodes were dissected in 4 and 1 patients in both phases. Remnant 16 and 19 patients were performed sentinel lymph node biopsy (Table 2).

### Pathological diagnosis

All of them were diagnosed with ductal carcinoma of the breasts. Three patients in early phase were having with ductal carcinoma *in situ*. All of patients, surgical margins were free from cancer involvement which were larger than 2 mm. Average of pathological horizontal margins were 14.1 mm and 13.6 mm, respectively (Table 3). No one needed delayed operation due to positive margin. Pathological examinations were added to the contralateral healthy breast tissue. No unexpected cancer was detected from any healthy breast.

### Adjuvant therapy

All patients of earlier 23 patients, except one, avoided postoperative radiation therapy to the remnant gland due to our institutional indication for radiation therapy at that time. All later consecutive 17 patients received postoperative radiation therapy to the remnant gland.

### Results of surgical procedure

The total operative period, including the waiting period for the results of the pathological examination of several surgical margins and

**Table 4:** Results of surgical procedure.

	Early phase (n=20)	Late phase (n=20)	P value
Operation period (average, minutes)	174 (112-289)	148 (96-216)	<0.05*
Plastic period (average, minutes)	88 (40-230)	84 (50-129)	<0.05
Bleeding (average, ml)	43 (0-230)	28 (5-65)	NS*
Resected breast tissue (g)	173 (39-350)	160 (56-668)	NS*
Delayed operation	0	0	
Local recurrence	0	0	
Observation period (average, months)	71 (57-121)	28 (21-49)	<0.05*

\*: t test, \*\*: X<sup>2</sup> test

**Table 5:** Postoperative complication and outcomes.

	Early phase (n=20)	Late phase (n=20)	P value
Postoperative complication			
Vascular disorder of NAC (%)	6 (25)	1 (5)	<0.05**
Fat necrosis (%)	0	1 (5)	NS**
Hyper plastic disorder (%)	3 (15)	1 (5)	NS**
Flat nipple (%)	2 (10)	2 (10)	NS**
Cosmetic evaluation			
Excellent good (%)	17 (75)	20 (100)	<0.05**
Poor fair (%)	3 (15)	0 (0)	
Re-operation	0	0	
Oncological outcome			
Local recurrence	0	0	
Distant recurrence	0	0	
Cancer specific death	0	0	
Death for another disease	1	0	

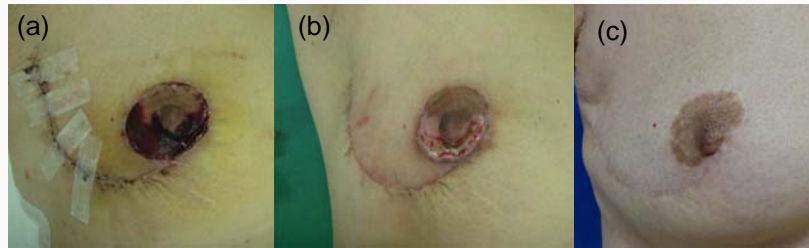
\*: t test, \*\*: X<sup>2</sup> test

SLN, ranged between 112 and 289 mins, with the mean period being 174 mins in early phase. In late phase, it ranged between 96 mins to 216 minutes with the mean period being 148 mins. It was significantly shorted in pate phase (P<0.05, Table 4). The mean plastic period was 88 minutes (ranged 40 mins to 230 mins) and 84 minutes (ranged 50 mins to 129 mins), respectively. Bleeding were 43 g (ranged 0 g to 230 g) and 28 g (5 g to 65 g), respectively. The amount of resected breast tissue was 173 g (ranged 39 g to 350 g) and 160 g (ranged 56 g to 668 g), respectively. No one received delayed operation due to cancer involvement of surgical margin after permanent pathological examination.

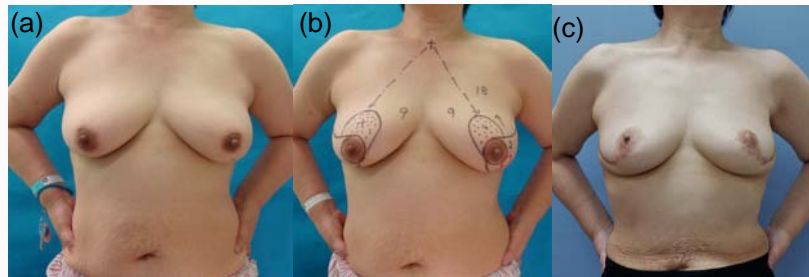
### Postoperative complications and cosmetic outcomes

Postoperative complications were shown in Table 5. Vascular disorder of NAC was observed in 6 and 1 patients, respectively (p<0.05). One of them whose disorder was most severe was shown in Figure 1. All of them were epithelialized completely in several weeks. Fat necrosis was shown in one patient in late phase. Hyperplastic disorder was shown in three and one patients, respectively (Figure2).

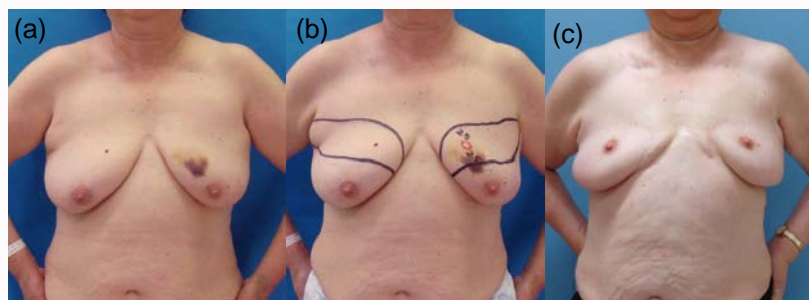
Cosmetic outcome was shown in Table 5. In early phase, sixteen patients (80%) was evaluated as excellent and good by cosmetic assessment, while all twenty ones were evaluated as excellent-good in late phase (P<0.05). On three patients in early phase cosmetic results were evaluated as poor-fair. On one patient whose lesion located on upper-inner quadrant area, we selected horizontal-mammoplasty. The shape and size of bilateral breasts were different, and the position of nipple were not symmetrized (Figure 3). On two patients



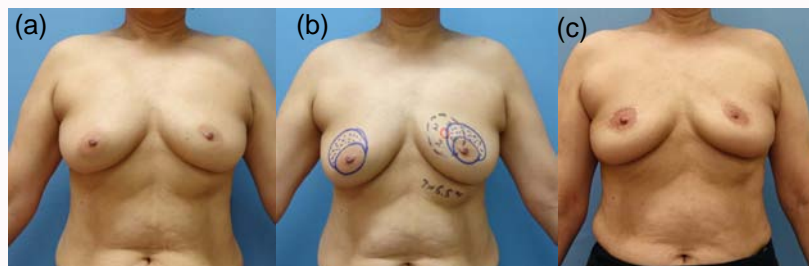
**Figure 1:** Vascular disorder of nipple-areola. a) Postoperative 2 weeks. b) Postoperative 5 weeks. c) Postoperative 7 years.



**Figure 2:** Hypertrophic disorder, Lt Breast cancer, 62-years old, T2N0M0 stageIIA, Bp+Ax. a) Preoperative findings. b) J-mammoplasty was designed. c) Postoperative 7 years findings.



**Figure 3:** Cosmetic result was evaluated as poor (Left breast cancer, 60-years old). a) Preoperative findings of ptotic breasts. b) Horizontal mammoplasty was designed. c) Postoperative 7 years findings.



**Figure 4:** Cosmetic result was evaluated as excellent (Left breast cancer, 55-years old). a) Preoperative findings of ptotic breasts. b) Horizontal mammoplasty was designed. c) Postoperative 4 years findings.

whose tumor located on outer-lower quadrant area, we selected J-mammoplasty. The breast size and shape were not kept symmetry. On all patients of late phase, cosmetic results were evaluated as excellent-good (Figure 4).

**Postoperative oncological outcome**

No patient experienced local recurrence, distant recurrence, or cancer specific death. Only one patient passed away 59 months postoperatively due to pancreatic cancer, good oncological and cosmetic conditions were obtained in her breast.

**Discussion**

The final cosmetic result of breast-conserving therapy is dependent

on many factors, including tumor size, tumor site, breast volume, the extent of surgery, chemotherapy, radiotherapy, hormone therapy, and age [16-19]. OBS which combines the concepts of oncologic and plastic surgeries is becoming more common, especially in Western countries [16,20-23]. There are currently many different OBS such as the careful planning of skin and parenchymal excisions, reshaping of the gland following parenchymal excisions, and repositioning of the NAC to the center of the breast mound with or without corrections to the contralateral breast in order to achieve better symmetry [18]. Different kinds of TMs based on tumor location have been reported and established, and the concept of TM combining partial mastectomy with a breast reduction technique has become more popular [4,5,24].

However, few studies have been conducted by Japanese institutions [2,3,10,11,13,14,25,26]. It is not clear that clinical experiences for new surgical technique affected the postoperative complications and cosmetic results until now. So we evaluated our experience and results of oncoplastic breast surgery combining with partial resection and reduction type of surgery of the breasts.

In this retrospective study, it is revealed that total operation period and plastic period of late phase became shorter, postoperative complication became less, and cosmetic results became better than those of early phase. It seems that we did improve oncoplastic breast surgery according to not only learning of the operation technique but also the adequate selection of the reduction mammoplasty.

In this study, we examined contralateral breast tissue whether being detected unexpected cancer or not. In Munhz's series, it was detected in the opposite breast in 2.8% of patients. Although the diagnosis of occult cancer is not a reason to perform opposite breast reduction, this procedure may be advantageous for high-risk patients and particularly for those who have already had breast cancer [27]. It is difficult to explain the discrepancy of our results and Munhoz's report, but the incidence of breast cancer of Japanese patients were not so far from that of other countries, so the advantages by removing the contralateral breast tissue at the time of breast conserving surgery might be coming important on the Japanese patients as well as Western ones.

Patient satisfaction is very important in the management of breast cancer [28]. In another series of out study, in which OBS combining partial mastectomy and free nipple areola grafting technique for patients with ptotic breast, 60% of patients noted that they were happy with the aesthetic results obtained, 40% were satisfied, and no one was dissatisfied. Eighty percent of patients considered the aesthetic appearance of their breasts to have been improved by surgery, which we regard as satisfactory [15]. We need to assess not only cosmetic evaluations, but also the satisfaction of patients with those newly introduced surgeries in Japan.

We are aware of some problems resolved in this study. The cost of opposite breast surgery is currently not covered by the national health insurance system. We showed the results of OBS with contralateral breast surgery to achieve good symmetric results under the approval of the Ethical Review Board of our university hospital. If opposite breast surgery for good symmetry immediately at the time of cancer surgery is accepted by the national insurance system, many patients will have more choices and get better oncological control easily, and better cosmetic improvements will be achieved. In near future, it will be necessary to establish a system performed at an appropriate value. Immediate bilateral operation might to be appropriate for patients, due to reduction of expected cancer on the contralateral healthy breast.

It remains that there is a possibility to perform an additional resection or mastectomy even after contra lateral symmetry established if pathological margins are positive or local recurrence appear. We select OBS under enough understanding about those limitations.

## Conclusion

The newly introduced OBS for Japanese patients have been well performed and experience progressed in both of safety and cosmesis. This is expected to become more popular as a treatment in Japan.

## References

1. Sobin LH, Wittekind C. TNM: classification of malignant tumours. 6<sup>th</sup> edn. New York: Wiley-Liss. 2002.
2. Kijima Y, Yoshinaka H, Hirata M, Shinden Y, Ishigami S, Nakajo A, et al. Oncoplastic breast surgery using spindle shaped-partial mastectomy for early breast cancer in the upper quadrant area. *MPS*. 2013;3(2):57-64.
3. Kijima Y, Yoshinaka H, Hirata M, Nakajo A, Arima H, Okumura H, et al. Oncoplastic breast surgery combining partial mastectomy with immediate breast reshaping using a keyhole-shaped skin glandular flap for Paget's disease. *Surg Today*. 2014;44(9):1783-8.
4. Clough KB, Kaufman GJ, Nos C, Buccimazza I, Sarfati IM. Improving breast cancer surgery: a classification and quadrant per quadrant atlas for oncoplastic surgery. *Ann Surg Oncol*. 2010;17(5):1375-91.
5. Berry MG, Fitoussi AD, Curnier A, Couturaud B, Salmon RJ. Oncoplastic breast surgery: a review and systematic approach. *J Plast Reconstr Aesthet Surg*. 2010;63(8):1233-43.
6. Hoffmann J, Wallwiener D. Classifying breast cancer surgery: a novel, complexity-based system for oncological, oncoplastic and reconstructive procedures, and proof of principle by analysis of 1225 operations in 1166 patients. *BMC Cancer*. 2009;9:108.
7. Japanese Breast Cancer Society. Cosmetic assessment after breast conserving surgery. The 12<sup>th</sup> annual meeting of the Japanese Breast Cancer Society. 2004; pp107-9.
8. Kijima Y, Yoshinaka H, Hirata M, Nakajo A, Arima H, Ishigami S, et al. Oncoplastic breast surgery combining periareolar mammoplasty with volume displacement using a crescent-shaped cutaneous flap for early breast cancer in the upper quadrant. *Surg Today*. 2013;43(8):946-53.
9. Kijima Y, Yoshinaka H, Hirata M, Mizoguchi T, Ishigami S, Nakajo A, et al. Oncoplastic surgery in Japanese patients with breast cancer close to the areola: partial mastectomy using periareolar mammoplasty: a case report. *Case Rep Surg*. 2011;2011:121985.
10. Kijima Y, Yoshinaka H, Ishigami S, Hirata M, Kaneko K, Mizoguchi T, et al. Oncoplastic surgery for Japanese patients with ptotic breasts. *Breast Cancer*. 2011;18(4):273-81.
11. Kijima Y, Yoshinaka H, Hirata M, Mizoguchi T, Ishigami S, Nakajo A, et al. Oncoplastic surgery in a Japanese patient with breast cancer in the lower inner quadrant area: partial mastectomy using horizontal reduction mammoplasty. *Breast Cancer*. 2014;21(3):375-8.
12. Kijima Y, Yoshinaka H, Hirata M, Mizoguchi T, Ishigami S, Nakajo A, et al. Oncoplastic Surgery for Japanese patients with breast cancer of the lower pole. *Surg Today*. 2011;41(10):1461-5.
13. Kijima Y, Yoshinaka H, Funasako Y, Natsugoe S, Aikou T. Oncoplastic surgery after mammary reduction and mastopexy for bilateral breast cancer lesions: Report of a case. *Surg Today*. 2008;38(4):335-9.
14. Kijima Y, Yoshinaka H, Hirata M, Mizoguchi T, Ishigami S, Arima H, et al. Oncoplastic surgery combining partial mastectomy with breast reconstruction using a free nipple-areola graft for ductal carcinoma in situ in a ptotic breast: report of a case. *Surg Today*. 2011;41(3):390-5.
15. Kijima Y, Yoshinaka H, Hirata M, Shinden Y, Nakajo A, Arima H, et al. Therapeutic mammoplasty combining partial mastectomy with nipple-areola grafting for patients with early breast cancer: a case series. *Surg Today*. 2016;46(10):1187-95.
16. Clough KB, Cuminet J, Fitoussi A, Nos C, Mosseri V. Cosmetic sequelae after conservative treatment for breast cancer: classification and results of surgical correction. *Ann Plast Surg*. 1998;41(5):471-81.
17. Bostwick J, 3rd, Paletta C, Hartrampf C. Conservative treatment for breast cancer. Complications requiring reconstructive surgery. *Ann Surg*. 1986;203(5):481-90.[Petit JY RM. Deformities following tumorectomy and partial mastectomy. In: plastic and reconstructive surgery of the

- breast. Noon B, editor. Philadelphia: Marcel Decker 1991.
18. Clough KB, Nos C, Salmon RJ, Soussaline M, Durand JC. Conservative treatment of breast cancers by mammoplasty and irradiation: a new approach to lower quadrant tumors. *Plast Reconstr Surg.* 1995;96(2):363-70.
  19. Noguchi M, Saito Y, Mizukami Y, Nonomura A, Ohta N, Koyasaki N, et al. Breast deformity, its correction, and assessment of breast conserving surgery. *Breast Cancer Res Treat.* 1991;18(2):111-8.
  20. Audretsch W, Rezai M, Kolotas C, Zamboglou N, Schnabel T, Bojar H. Onco-plastic surgery: "target" volume reduction (BCT-mastopexy), lumpectomy reconstruction (BCT-reconstruction) and flap-supported operability in breast cancer. *Proceeding 2nd European Congress on Senology. Proceeding 2nd European Congress on Senology.* 1994;October 2-6:139-57.
  21. Audretsch W, Rezai M, Kolotas C, Zamboglou N, Schnabel T, H B. *Perspect Plast Surg. Perspect Plast Surg.* 1998;11:71-106.
  22. Bostwick J, 3rd, Paletta C, Hartrampf CR. Conservative treatment for breast cancer. Complications requiring reconstructive surgery. *Ann Surg.* 1986;203(5):481-90.
  23. Petit JY RM. Deformities following tumorectomy and partial mastectomy. In: plastic and reconstructive surgery of the breast. Noon B, editor. Philadelphia: Marcel Decker 1991.
  24. Masetti R, Pirulli PG, Magno S, Franceschini G, Chiesa F, Antinori A. Oncoplastic techniques in the conservative surgical treatment of breast cancer. *Breast cancer.* 2000;7(4):276-80.
  25. Zaha H, Hakazu O, Watanabe M, Higa M. Breast-conserving surgery using reduction mammoplasty. 2008;223:211-5.
  26. Kijima Y, Yoshinaka H, Shinden Y, Hirata M, Nakajo A, Arima H, et al. Oncoplastic breast surgery for centrally located breast cancer: a case series. *Gland surgery.* 2014;3(1):62-73.
  27. Munhoz AM, Aldrighi CM, Montag E, Arruda E, Brasil JA, Filassi JR, et al. Outcome analysis of immediate and delayed conservative breast surgery reconstruction with mastopexy and reduction mammoplasty techniques. *Ann Plast Surg.* 2011;67(3):220-5.
  28. Waljee JF, Hawley S, Alderman AK, Morrow M, Katz SJ. Patient satisfaction with treatment of breast cancer: does surgeon specialization matter? *J Clin Oncol: An American Society of Clinical Oncology.* 2007;25(24):3694-8.