



# Cerebral Hyperperfusion Syndrome is it an Underlying Complication of Ventriculoperitoneal Shunt: a Case Report

Junwen Hu, Fuyi Liu, Chun Wang, Feng Yan, Jingyin Chen, Cong Qian and Gao Chen\*

Department of Neurological Surgery, Zhejiang University School of Medicine, Hangzhou, China

## Abstract

**Objective:** Cerebral Hyperperfusion Syndrome (CHS) is a rare complication that most reported after carotid endarterectomy, which to be an underlying complication of ventriculoperitoneal shunt (V-P shunt) theoretically, has not been reported yet. Here we report a case that had clinical and radiological proof of CHS after V-P shunt.

**Methods:** We reviewed clinical progress and imagings's of this patient in detail and consult some relevant literatures. Then we put forward a novel hypothesis that a potential but rare complication occurs after V-P shunt, which we provide relevant information to confirm.

**Results:** The recorded clinical progress and imaging's of the case highly supports the hypothesis that the patient experienced cerebral hyperperfusion after the V-P shunt.

**Conclusion:** Physicians must be aware of CHS that a rare but potentially fatal complication following V-P shunt.

**Keywords:** Ventriculoperitoneal shunt; Epilepsy; Cerebral hyperperfusion syndrome

## Case Presentation

A 63-year-old woman was admitted January 2018 for progressive mental deterioration and trouble walking within 3 months. Her medical history includes resection of left frontal lobe grade III glioma, the surgery presented in March 2003. In July 2004, she was diagnosed hydrocephalus and then went on ventriculoperitoneal shunt (V-P shunt); the tube was placed in the right lateral ventricle (Figure 1A). Both two surgeries did not process in our hospital. During the past 14 years, the patient irregularly went to our hospital for brain magnetic resonance imaging (MRI) scan, MRI showed no significant changes on the size of bilateral ventricles and no recurrence of glioma. She basically had the ability to independently carry out daily activities before this admission. Now she was admitted to our hospital for progressive mental deterioration and trouble walking.

On physical examining, she was moving slowly, had correct verbal answer, sat in a wheelchair and could not walk independently, Glasgow Coma Scale (GCS) scored 15. Brain MRI showed bilateral ventricles enlargement compared to the previous imaging's the reservoir of the right shunt system was considered out of work so we decided to implement V-P shunt once again in another side of the ventricle. The preoperative pressure of lumbar puncture was 80 mm H<sub>2</sub>O. The patient went on left V-P shunt on Jan. 8, 2018, but was found confusion soon after the surgery, her GCS score deteriorated to 10 (E3V2M5), which was not improved using low dose methylprednisolone. Her Systolic Blood Pressure (sBP) monitored between 154 mmHg to 198 mmHg compared to 120 mmHg to 162 mmHg preoperatively. On postoperative day 6 (POD 6), the patient began to have paroxysmal right hand and face twitch, seizures stopped after using diazepam. Brain CT and MRI showed no intracranial hemorrhage (Figure 1B) or fresh cerebral infarction (Figure 1C). Treatment with levetiracetam and valproate was initiated, but seizures still had not been fully controlled. In the next few days, she was experienced five or six seizures daily and GCS score declined to 8 (E2V1M5). After we added clonazepam and carbamazepine to treat her on POD19, the patient had no recurrence of seizures, but still in a coma state, GCS scored 7 (E1V1M5). At POD47, we found a large hematoma beside the left occipital horn by reexamining brain CT (Figure 1H). Laboratory studies showed normal coagulation function. The patient then received conservative treatment and discharged. After three months follow-up, we reduced the antiepileptic drugs for the patient, and she had no recurrence of epilepsy, but was still confused.

## OPEN ACCESS

### \*Correspondence:

Gao Chen, Department of Neurological Surgery, Zhejiang University School of Medicine, Hangzhou, China, Tel: 86 057187784753;  
E-mail: d-chengao@zju.edu.cn

Received Date: 08 Jan 2019

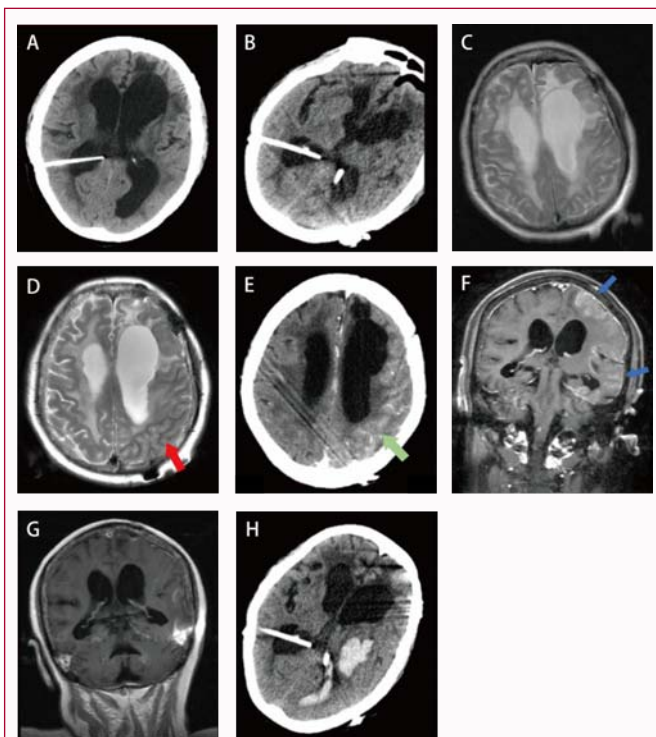
Accepted Date: 04 Feb 2019

Published Date: 07 Feb 2019

### Citation:

Hu J, Liu F, Wang C, Yan F, Chen J, Qian C, et al. Cerebral Hyperperfusion Syndrome is it an Underlying Complication of Ventriculoperitoneal Shunt: a Case Report. *Clin Surg*. 2019; 4: 2323.

Copyright © 2019 Gao Chen. This is an open access article distributed under the Creative Commons Attribution License, which permits unrestricted use, distribution, and reproduction in any medium, provided the original work is properly cited.



**Figure 1:** A): Preoperative brain CT demonstrated that a shunt tube placed in the right lateral ventricle. B): (POD 1): Brain CT showed no intracranial hemorrhage. C): (POD 8): There is no fresh cerebral infraction. D): (POD 8): Extensive gyral swelling in the left hemisphere especially in rear part on T2-weighted MR. E): (POD 14): Brain CTA showed the apparently increased cerebral blood flow in the left hemisphere as to the right. F): (POD 16): Cortical gyral enhancement that involves the left hemisphere on coronal gadolinium-enhanced T1-weighted MR, but disappeared in G): (POD 29). H): (POD 47): A large hematoma beside the left occipital horn flooding into left ventricle was found by reexamining brain CT before the patient discharged.

## Discussion

The incidence of epilepsy after V-P shunt is from 4.5% to 6.0% in adults [1,2]. Epilepsy after shunt can be secondary to intracranial hemorrhage, infection, etc., or directly caused by the damage to the brain parenchyma, leaving foreign body inside the skull, modifying shunt tube, etc [3]. The vast majority of seizures occur several months after the placement of tube, and there is no case reported during the first two weeks after shunting by Dan and Wade [4]. In our case, the epileptic seizure occurred in POD6 and exhibited intractable, which we suspect relating to other factors.

By reviewing the case and literatures, we realized that our patient may have close interaction with cerebral hyperperfusion syndrome (CHS), which is a rare but extremely serious complication that occurs after carotid endarterectomy (CEA). It was first reported by Sundt et al. [5] postoperative headache, altered mental status, neurological deficits, seizures are the several primary clinical manifestations. Postoperative hypertension is one of the risk factors combines with CHS [6,7]. The destruction of the ipsilateral Blood-Brain Barrier (BBB) happens in the early stage of CHS, and the vascular damage may further increase the risk of intracranial hemorrhage, which is reported an uncommon complication of CHS and occurs in less than 1% of patient [8]. Patients with epilepsy after CHS initially present with focal seizures in the contralateral of the surgical site, they may develop a generalized tonic-clonic attack if not treat properly. Impaired cerebral autoregulation and hypertension are said to be

the two synergistic mechanisms that contribute to pathophysiology of CHS [9]. CHS is not only emerging after Carotid Artery Stenting (CAS) and Carotid Endarterectomy (CEA), commonly seen after other revascularization operations, like intracranial arterial percutaneous angioplasty, intracranial-cranial bypass grafting, iv tPA treatment for acute ischemic stroke etc [3,10,11]. Abnormal manifestations on MRI include: white matter edema, focal infarction, localized or extensive cerebral hemorrhage.

Bouri et al. [6] proposed four criteria for the diagnosis of CHS after CEA in 2011: (1) occurred within 30 days post-CEA; (2) evidence of cerebral hyperperfusion (supported by TCD, SPECT or CT/MRI perfusion imaging) or sBP >180 mmHg; (3) clinical symptoms such as new headache, epilepsy, hemiplegia, GCS <15, or presence of images, such as cerebral edema or intracranial hemorrhage; (4) no evidence of new cerebral ischemia, postoperative carotid occlusion, metabolism, or drug-related factors. 6 Some scholars have suggested that the current diagnosis of CHS is divided into two levels: cerebral hemodynamic diagnostic criteria, clinical and imaging diagnostic criteria [12]. In our case, the patient changed consciousness soon after the surgery, POD6 appeared intractable focal seizures, CTA showed that the significantly increased cerebral blood flow in the operative hemisphere than the otherside (Figure 1E). Meanwhile extensive gyral swelling was seen in the left hemisphere (Figure 1D) because of hyperperfusion that lead to vasogenic brain edema. Cortical gyral enhancement in the operative hemisphere (Figure 1F) suggests reperfusion injury, which is said to be attributed to breakdown of the blood-brain barrier (BBB) [13]. Glioma recurrence was also considered, but the enhancement disappeared later (Figure 1G), it may due to the improvement of the BBB. Finally ICH come out before POD47 (Figure 1H). In conclusion, this patient is highly pointing to the diagnose of CHS in the light of the existing evidences of both clinical and radiological manifestations.

Patients with severe hydrocephalus often have longer disease course, highly dilated ventricles, atrophic parenchyma, and more complicated conditions. In this patient, the bilateral cerebral hemispheres may form their own pressures respectively as time went on, making this operation equivalent to decompressing the left hemisphere. However, her brain had a poor compliance to adjust the Intracerebral Pressure (ICP) in a short time, which would be compensated by increasing cerebral blood flows and then she appeared a series symptoms of CHS.

We believe that for patient with poor basic condition and complex intracranial situation, it is better to determine the intracranial hemodynamics before the shunt operation, or to recognize the possibility of CHS once seizure occurred after the surgery by closely monitoring blood pressure and for evidence of hyperperfusion, then effective treatments can be implemented and later improve patients' prognosis. Postoperative BP control is fundamental in the prevention and management of CHS [7].

## Limitations

We did not consider the problem of CHS during the treatment, so it is regrettable that we do not detect intracerebral blood flow of the patient by using TCD or CTP.

## Conclusion

Here we report a patient experienced cerebral hyperperfusion syndrome after V-P shunt. The recorded clinical progress and

imaging's of the case highly supports the hypothesis that the patient experienced cerebral hyperperfusion after the V-P shunt. Early recognition and medical intervention of CHS are extremely important, because the prognosis gets worse once intracerebral hemorrhage happen. Physicians must be aware of this rare but potentially fatal complication following V-P shunt in patients with poor basic condition and complex intracranial situation.

## Acknowledgement

1. We would like to acknowledge the patient's relative that kindly agreed to sign the informed consent.

2. This study was supported by National Natural Science Foundation of China (81701152).

## References

1. Akdag G, Algin DI, Musml A, Erdinic OO. Epilepsy due to Intracranial Surgery: 15 Years of Experience. *J Turkish Epilepsi Society*. 2016;23(1):19-24.
2. Larsson J, Israelsson H, Eklund A, Malm J. Epilepsy, headache, and abdominal pain after shunt surgery for idiopathic normal pressure hydrocephalus: the INPH-CRasH study. *J Neurosurg* 2018;128(6):1674-83.
3. Klepper J, Büsse M, Strassburg HM, Sörensen N. Epilepsy in shunt-treated hydrocephalus. *Dev Med Child Neurol*. 1998;40(11):731-6.
4. Dan NG, Wade MJ. The incidence of epilepsy after ventricular shunting procedures. *J Neurosurg* 1986;65(1):19-21.
5. Sundt TM Jr, Sharbrough FW, Piepgras DG, Kearns TP, Messick JM Jr, O'Fallon WM. Correlation of cerebral blood flow and electroencephalographic changes during carotid endarterectomy: with results of surgery and hemodynamics of cerebral ischemia. *Mayo Clin Proc*. 1981;56(9):533-43.
6. Bouri S, Thapar A, Shalhoub J, Jayasooriya G, Fernando A, Franklin IJ, et al. Hypertension and the post-carotid endarterectomy cerebral hyperperfusion syndrome. *Eur J Vasc Endovasc Surg* 2011;41(2):229-37.
7. van Mook WN, Rennenberg RJ, Schurink GW, van Oostenbrugge RJ, Mess WH, Hofman PA, et al. Cerebral hyperperfusion syndrome. *Lancet Neurol*. 2005;4(12):877-88.
8. Moulakakis KG, Mylonas SN, Sfyroeras GS, Andrikopoulos V. Hyperperfusion syndrome after carotid revascularization. *J Vasc Surg*. 2009;49(4):1060-8.
9. Sanders K, Demaerel P, Lemmens R. Aphasia 1 Week After Carotid Endarterectomy: Hypoperfusion or Hyperperfusion? *Stroke*. 2016;47(4):e63-5.
10. Zhang Y, Kumar A, Tezel JB, Zhou Y. Imaging Evidence for Cerebral Hyperperfusion Syndrome after Intravenous Tissue Plasminogen Activator for Acute Ischemic Stroke. *Case Rep Neurol Med*. 2016;2016:8725494.
11. Muehlschlegel S, Voetsch B, Singhal AB. CT angiography and CT perfusion in post-CEA hyperperfusion syndrome. *Neurology*. 2007;68(17):1437.
12. Liu SD, Lv CF, Yuan D. 4 case of cerebral hyperperfusion syndrom and cerebral hyperperfusion phenomenon following carotid artery stenting. *Journal of Clinical Emergency (China)* 2015;16(5):382-86.
13. Smirniotopoulos JG, Murphy FM, Rushing EJ, Rees JH, Schroeder JW. Patterns of contrast enhancement in the brain and meninges. *Radiographics*. 2007;27(2):525-51.