



# Can Simultaneous Bilateral Medial Opening High Tibial Osteotomy Satisfy Bilateral Medial Osteoarthritis Patients with Varus Alignment?

Dong Won Suh<sup>1</sup>, Seung Beom Han<sup>2</sup>, Kuhoang Cheong<sup>1</sup>, So Hyun Kim<sup>1</sup> and Bong Soo Kyung<sup>1\*</sup>

<sup>1</sup>Joint Center, Barunesang Hospital, Seongnam-si, Gyeonggi-do, Korea

<sup>2</sup>Department of Orthopedic Surgery, Korea University Anam Hospital, Korea University College of Medicine, Seoul, Korea

## Abstract

**Purpose:** To determine the feasibility of simultaneous bilateral High Tibial Osteotomy (HTO) with early weight bearing rehabilitation for bilateral medial osteoarthritis patients with varus alignment.

**Methods:** Clinical records and radiographic findings of 25 patients who underwent simultaneous bilateral HTO with early weight bearing rehabilitation from January 2015 to March 2016 at our institution were retrospectively reviewed. The crutch ambulation period and patient satisfaction were evaluated at postoperative one year. The union at postoperative one year and femorotibial angle at postoperative two months and one year were radiologically checked.

**Results:** Regarding patient satisfaction, of 25 patients, 17 (68%) indicated they were 'satisfied', 3 (12%) 'unsatisfied', and the remaining five 'so-so'. Eleven (44%) patients could walk without any support within one month and other eleven (44%) patients within two months. The remaining three (12%) patients took three months to remove their crutch. All cases showed complete union at postoperative one year. A greater loss in the correction was identified in the bone substitute group than that in the allo-bone chip group.

**Conclusion:** Simultaneous bilateral medial opening HTO can be a good option for patients of bilateral medial osteoarthritis with varus alignment. This showed good patient satisfaction and acceptable discomfort.

**Keywords:** Osteoarthritis; Tibial osteotomy; Rehabilitation; Patient satisfaction

## OPEN ACCESS

### \*Correspondence:

Bong Soo Kyung, Joint Center,  
Barunesang Hospital, Seongnam-si,  
Gyeonggi-do, Korea,  
E-mail: id-helios27@hanmail.net

**Received Date:** 11 Mar 2019

**Accepted Date:** 10 Apr 2019

**Published Date:** 17 Apr 2019

### Citation:

Suh DW, Han SB, Cheong K, Kim SH, Kyung BS. Can Simultaneous Bilateral Medial Opening High Tibial Osteotomy Satisfy Bilateral Medial Osteoarthritis Patients with Varus Alignment?. *Clin Surg.* 2019; 4: 2397.

**Copyright** © 2019 Bong Soo Kyung. This is an open access article distributed under the Creative Commons Attribution License, which permits unrestricted use, distribution, and reproduction in any medium, provided the original work is properly cited.

## Introduction

High Tibial Osteotomy (HTO) is a well-established surgical option for symptomatic medial compartmental osteoarthritis with varus alignment [1,2]. Since varus alignment and medial osteoarthritis tend to develop bilaterally, surgical options, including total knee arthroplasty and unicompartmental knee arthroplasty, are often recommended for both sides simultaneously [3,4]. However, simultaneous HTO has not been suggested due to discomfort by an extended postoperative restrictive period of weight bearing.

With the development of an advanced rigid locking plate, Tomofix, a new rehabilitation protocol that includes early weight bearing, has been recently applied [5-9]. These studies have reported that a rigid locking plate enables patients to apply an early weight bearing rehabilitation protocol with better clinical outcomes and patient satisfaction than previous unlocking plates and a delayed rehabilitation protocol. Furthermore, for all patients in these studies, the non-weight bearing period was applied for two weeks only. These showed the possibility of simultaneous bilateral HTO possibly needing two weeks of a wheelchair ambulation period with a bilateral non-weight bearing. Patients can then start to walk with crutches.

However, there is lack of study regarding simultaneous bilateral HTO and rehabilitation. Only one study with 10 cases showed excellent outcomes after simultaneous bilateral HTO and early weight bearing rehabilitation [8]. Therefore, the objective of this study was to determine the feasibility of simultaneous bilateral High Tibial Osteotomy (HTO) with an early weight bearing rehabilitation protocol for bilateral medial osteoarthritis patients with varus alignment. The crutch ambulation period, patient satisfaction, and radiological outcomes (union and femorotibial angle) were then evaluated.

## Materials and Methods

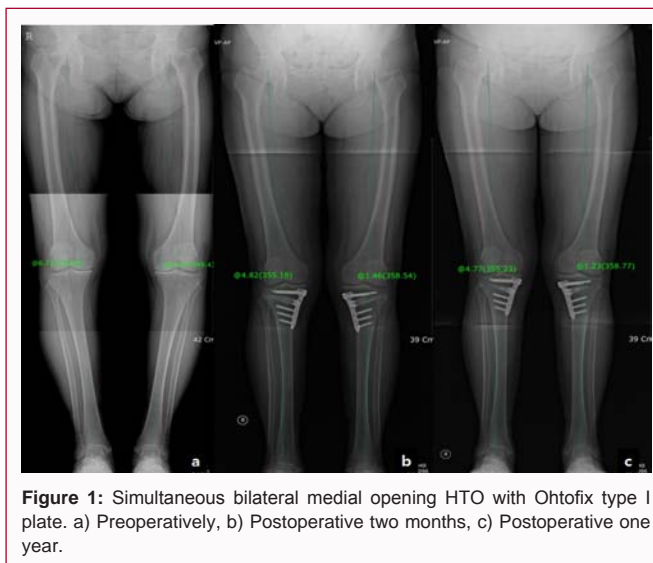
From January 2015 to March 2016, our institution recommended simultaneous bilateral HTO rehabilitation with early weight bearing for patients who met the following inclusion criteria for both sides: 1) symptomatic medial osteoarthritis, 2) over 5 degrees of varus knee alignment on weight-bearing lower extremity Anteroposterior (AP) view, 3) no combined problem on lateral compartment, and 4) age over 20 years but under 70 years. All patients underwent combined arthroscopic surgery, such as partial meniscectomy and meniscal repair or microfracture chondroplasty if needed. The exclusion criteria for the current study were: 1) those who denied simultaneous or HTO surgery, 2) those who had severe sarcopenia or osteoporosis, 3) those who disagreed with using their medical records for any studies.

The clinical records and radiographic findings of the participants who met the inclusion criteria without meeting the exclusion criteria were retrospectively reviewed. A total of 25 patients were enrolled in the current study, and the demographics of these participants are summarized in Table 1. The Rosenberg view, lateral view, and weight-bearing lower extremity AP view images at postoperative two months and one year were taken for all patients (Figure 1). At the monthly follow-up after the operation, the patients reported when they could walk without crutch or any support. At one year after surgery, the patient's satisfaction was evaluated with a 4-grade scale: 1) very satisfied, 2) satisfied, 3) so-so, and 4) unsatisfied. The Public Institutional Review Board approved this study (approval number: 2017-0597-002).

### Surgical procedures and postoperative rehabilitation protocol

Preoperative planning was performed according to the "Miniaci's method", and a proper gap diameter was measured with the weight-bearing lower extremity AP view [10,11]. Under spinal anesthesia, the tourniquet was inflated to 300 mmHg to 350 mmHg, and a routine arthroscopic examination was performed using anteromedial and anterolateral portals. When necessary, arthroscopic procedures were done, including meniscectomy, meniscal repair, debridement, and/or microfracture chondroplasty. A skin incision was made longitudinally or transversely on the medial side of the proximal tibia, and the superficial medial collateral ligament was released. After checking for the metaphyseal flare on the medial side of the proximal tibia, two K-wires were applied to the "safe zone" between the fibular tip and the circumferential line of the fibular head under fluoroscopic guidance [12]. According to OhtoFix plate surgical guideline (Ohto Medical) and previous studies, bi-plane or uni-plane osteotomy was performed based on the surgeon's preference [12,13]. After sawing below the two K-wires up to 10 mm from the lateral cortex, the osteotomy site was gradually opened using the three-chisel technique. After widening the measured gap, a metal block with a planned diameter was applied on the widened gap, and the OhtoFix type I plate was applied and fixed with a link screw. After applying six locking screws to the plate, the allocancellous bone chip or artificial bone substitute was grafted on the osteotomy gap as filler. Hemovac drain was then applied to the osteotomy site. The subcutaneous fat layer and skin were closed using Vicryl and nylon, respectively. After applying a compressive dressing, the tourniquet was deflated, and a cylinder splint was applied.

Postoperatively, the applied drain was removed on postoperative day 2 and passive range of motion exercise was started using



**Figure 1:** Simultaneous bilateral medial opening HTO with Ohtofix type I plate. a) Preoperatively, b) Postoperative two months, c) Postoperative one year.

**Table 1:** Demographic characteristics of patients.

Demographics	Mean $\pm$ Standard deviation or N
Age (years old)	55.6 $\pm$ 5.7
Sex (M:F)	5:20
Weight (Kg)	66.8 $\pm$ 10.0
Height (cm)	160 $\pm$ 6.3
BMI	26.0 $\pm$ 3.6
Pre-op FTA* (degree)	
Right knee	6.2 $\pm$ 2.3
Left knee	6.3 $\pm$ 2.4
Operative time (min)	197 $\pm$ 28
Size of metal block (mm)	
Right knee	9.8 $\pm$ 2.1
Left knee	10.6 $\pm$ 2.7
Type of filler (Allo-bone chip: artificial bone substitute)	12:13

\*FTA (Femorotibial Angle, '+' mean varus; '-' mean valgus)

continuous passive motion equipment. At that time, the applied cylinder splint was changed to a Medial Collateral Ligament (MCL) brace or Anterior Cruciate Ligament (ACL) brace per surgeon's preference, and the brace was recommended to be kept for two months. After two weeks of wheel-chair ambulation with support, crutch ambulation with partial weight bearing was started. With an allowance of tolerable weight bearing, patients advanced their weight bearing as the pain and strength allowed.

### Statistical analysis

The patient's satisfaction and crutch ambulation period were evaluated. To identify the factors affecting patient's satisfaction and crutch period, a multiple regression stepwise backward analysis was performed using variable factors, including age, sex, height, weight, BMI, operation time, pre-operative varus angle (right, left), wedge size (right, left), and type of filler. Radiologically, the union rate at postoperative one year was evaluated, and in addition, mechanical Femorotibial Angle (FTA) of both sides at postoperative two months and one year was measured for all participants by one orthopedic surgeon. Wilcoxon signed rank test was used to compare FTA at postoperative two months and one year. After grouping by two types of filler, allo-bone chip vs. bone substitute, the FTA in each group were also compared in the same manner.

**Table 2:** Radiological results (degree).

Group	All			Allo-bone chip			Bone substitute		
	Right	Left	All	Right	Left	All	Right	Left	All
Pre Op FTA <sup>†</sup>	6.2	6.3	6.3	6.4	6.6	6.5	6.1	6.1	6.1
Post 2m FTA	-1.7	-2.1	-1.9	-1.3	-1.7	-1.5	-2.1	-2.4	-2.2
Post 1 yr FTA	-1.0	-1.6	-1.4	-1.4	-1.4	-1.4	-0.8	-1.8	-1.3
P-value <sup>**</sup>			0.008			0.845			0.004

<sup>†</sup> FTA (Femorotibial Angle, '+' mean varus; '-'mean valgus)

<sup>\*\*</sup> Wilcoxon signed rank test of FTA between postoperative two months and one year

## Results

Regarding patient's satisfaction, of 25 patients, 17 (68%) answered 'satisfied' (4 'very satisfied' and 13 'satisfied'), 3 (12%) answered 'unsatisfied', and 5 answered 'so-so'. Eleven (44%) patients each could walk without any support within 1 month and within 2 months, respectively. The other three (12%) patients took 3 months to remove the crutch (Figure 2). Multiple regression analysis of patient's satisfaction showed that the type of filler and pre-operative varus angle of left knee were significant factors. However, there were no significant factors affecting the crutch ambulation period.

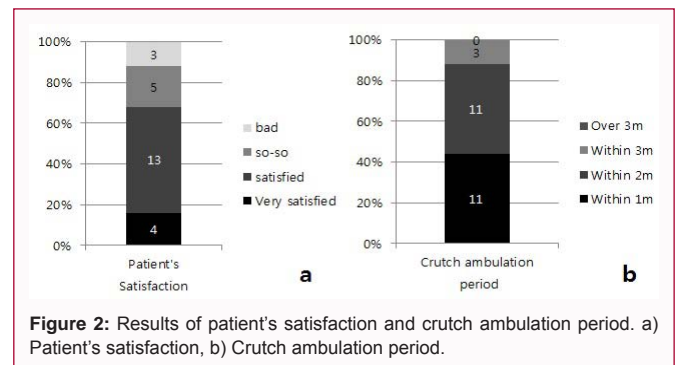
Radiologically, all patients showed union at postoperative one year. On weight-bearing lower extremity AP view at postoperative two months, the FTA showed valgus 1.7 degrees on right knees and 2.1 degrees on left knees. The correction angles were slightly reduced to valgus 1.1 degrees on right knees and 1.7 degrees on left knees at postoperative one year. The Wilcoxon signed rank test showed a statistically significant difference in FTA between postoperative two months and one year (Table 2). After dividing the two groups by the type of filler, a greater loss of correction was found in the group with the bone substitute than that with the allo-bone chip. Furthermore, only the decrement in the FTA in the bone substitute group was statistically significant based on a Wilcoxon signed rank test (Table 2).

## Discussion

The purpose of the current study was to evaluate patient's satisfaction and crutch ambulation period after simultaneous bilateral medial opening HTO to show the feasibility to apply this simultaneous procedure for patients with bilateral medial osteoarthritis with varus alignment. The results of the current study showed good patient satisfaction and a relatively short period of discomfort, suggesting that simultaneous HTO with early weight bearing rehabilitation could be used for such patients with acceptable discomfort.

Prior biomechanical studies have reported the necessity of bilateral HTO. Lind et al. [14] have reported that HTO reduces varus alignment and adduction moments of the operated knee. However, they also reported that it might increase the adduction moments of the non-operated knee [14]. Sischek et al. [15] reported that this pathological status can be reduced by a staged bilateral HTO, and they also reported no difference in the biomechanical property between patients who underwent the second surgery staged within one year of the first surgery, and those who underwent the second surgery beyond one year of the first surgery. To shorten the pathological period for a second staged knee, the simultaneous bilateral HTO can be a proper method if it has no effect on patient's rehabilitation.

A previous reported on the clinical results of a simultaneous bilateral medial opening of HTO [8]. Takeuchi et al. [8] reported



**Figure 2:** Results of patient's satisfaction and crutch ambulation period. a) Patient's satisfaction, b) Crutch ambulation period.

excellent clinical and radiological results for their ten patients with simultaneous bilateral HTO and early weight bearing rehabilitation. Consistent with their results, our study also showed that all participants showed complete union at postoperative one year, and they removed any support within three months, and most of them answered that they were satisfied. These results showed that simultaneous bilateral HTO with early weight bearing rehabilitation could be applied to patients of bilateral medial osteoarthritis with varus alignment, resulting in acceptable discomfort.

For early weight bearing after simultaneous bilateral HTO, firm fixation for the osteotomy site is important. With the development of a rigid locking plate, Tomofix, an early weight bearing rehabilitation protocol, has begun to be applied after HTO. Many studies have reported better results after using this plate and early weight bearing rehabilitation than a previous nonlocking plate or delayed rehabilitation [5-7,9]. For simultaneous bilateral HTO, we suggest a firmer fixator and a new rigid locking plate with a metal block. Previous cadaveric studies reported that locking plate with a metal block has a higher failure load than the locking plate only [16,17]. The current study used a locking plate with a metal block, Ohtofix type I plate. The crutch ambulation period was shorter than that in a study using Tomofix, even though that study was about unilateral HTO [5].

To open the gap of the medial opening HTO, various materials have been grafted. Two systematic reviews have evaluated these fillers as the factor for nonunion or loss of correction [18,19]. Slevin et al. [19] reported that a greater loss of correction has been identified in the allograft group than that in the synthetic graft group in their systematic review. With a common rigid locking plate, Tomofix, no correction loss has been reported in two studies [20,21]. However, Lash et al. have reported a greater loss of correction in the bone substitute group than in the allograft or autograft group [18]. One study using Hydroxyapatite/Tricalcium Phosphate bone substitute and their own unusual locking plate reported that the mean loss of correction from postoperative three months to postoperative one year was four degrees [22]. In the current study, patients in the bone

substitute group showed worse patient satisfaction than the allo-bone chip group, although the loss of correction was only statistically significant in the bone substitute group. According to these results, we carefully suggest that an allograft may be better than the artificial bone substitute. However, a further controlled study will be needed.

This study has a few limitations. First, this study was retrospective without a control group. Second, this study had a short-term follow-up period without detailed outcome measurement tools, such as the WOMAC score. However, contrary to popular belief, our 25 patients reported good satisfaction and acceptable discomfort with a short crutch ambulation period. These findings suggest that simultaneous bilateral medial opening HTO with early weight bearing rehabilitation might be feasible for patients with bilateral medial osteoarthritis with varus alignment.

## Conclusion

Simultaneous bilateral medial opening HTO can be a good option for bilateral medial osteoarthritis patients with varus alignment. This provides good patient's satisfaction and acceptable discomfort.

## References

- McNamara I, Birmingham TB, Fowler PJ, Giffin JR. High tibial osteotomy: evolution of research and clinical applications--a Canadian experience. *Knee Surg Sports Traumatol Arthrosc.* 2013;21(1):23-31.
- Prodromos CC, Amendola A, Jakob RP. High tibial osteotomy: indications, techniques, and postoperative management. *Instr Course Lect.* 2015;64:555-65.
- Cohen RG, Forrest CJ, Benjamin JB. Safety and efficacy of bilateral total knee arthroplasty. *J Arthroplasty.* 1997;12(5):497-502.
- Leonard L, Williamson DM, Ivory JP, Jennison C. An evaluation of the safety and efficacy of simultaneous bilateral total knee arthroplasty. *J Arthroplasty.* 2003;18(8):972-8.
- Lansdaal JR, Mouton T, Wascher DC, Demey G, Lustig S, Neyret P, et al. Early weight bearing versus delayed weight bearing in medial opening wedge high tibial osteotomy: a randomized controlled trial. *Knee Surg Sports Traumatol Arthrosc.* 2017;25(12):3670-8.
- Lee OS, Ahn S, Lee YS. Effect and safety of early weight-bearing on the outcome after open-wedge high tibial osteotomy: a systematic review and meta-analysis. *Arch Orthop Trauma Surg.* 2017;137(7):903-11.
- Schröter S, Ateschrang A, Löwe W, Nakayama H, Stöckle U, Ihle C. Early full weight-bearing versus 6-week partial weight-bearing after open wedge high tibial osteotomy leads to earlier improvement of the clinical results: a prospective, randomised evaluation. *Knee Surg Sports Traumatol Arthrosc.* 2017;25(1):325-32.
- Takeuchi R, Aratake M, Bito H, Saito I, Kumagai K, Ishikawa H, et al. Simultaneous bilateral opening-wedge high tibial osteotomy with early full weight-bearing exercise. *Knee Surg Sports Traumatol Arthrosc.* 2008;16(11):1030-7.
- Takeuchi R, Ishikawa H, Aratake M, Bito H, Saito I, Kumagai K, et al. Medial opening wedge high tibial osteotomy with early full weight bearing. *Arthroscopy.* 2009;25(1):46-53.
- Elson DW, Petheram TG, Dawson MJ. High reliability in digital planning of medial opening wedge high tibial osteotomy, using Miniaci's method. *Knee Surg Sports Traumatol Arthrosc.* 2015;23(7):2041-8.
- Miniaci A, Ballmer FT, Ballmer PM, Jakob RP. Proximal tibial osteotomy. A new fixation device. *Clin Orthop Relat Res.* 1989;(246):250-9.
- Han SB, Lee DH, Shetty GM, Chae DJ, Song JG, Nha KW. A "safe zone" in medial open-wedge high tibia osteotomy to prevent lateral cortex fracture. *Knee Surg Sports Traumatol Arthrosc.* 2013 Jan;21(1):90-5.
- Suh DW, Kyung BS, Han SB, Cheong K, Lee WH. Efficacy of Tranexamic Acid for Hemostasis in Patients Undergoing High Tibial Osteotomy. *J Knee Surg.* 2018;31(1):50-5.
- Lind M, McClelland J, Wittwer JE, Whitehead TS, Feller JA, Webster KE. Gait analysis of walking before and after medial opening wedge high tibial osteotomy. *Knee Surg Sports Traumatol Arthrosc.* 2013;21(1):74-81.
- Siscek EL, Birmingham TB, Leitch KM, Martin R, Willits K, Giffin JR. Staged medial opening wedge high tibial osteotomy for bilateral varus gonarthrosis: biomechanical and clinical outcomes. *Knee Surg Sports Traumatol Arthrosc.* 2014;22(11):2672-81.
- Ha JK, Yeom CH, Jang HS, Song HE, Lee SJ, Kim KH, et al. Biomechanical Analysis of a Novel Wedge Locking Plate in a Porcine Tibial Model. *Clin Orthop Surg.* 2016;8(4):373-8.
- Seung-Beom Han, Ji-Hoon Bae, Sung-Jae Lee, Tae-Gon Jung, Kang-Hee Kim, Jae Ho Kwon, et al. Biomechanical properties of a new anatomical locking metal block plate for opening wedge high tibial osteotomy: uniplane osteotomy. *Knee Surg Relat Res.* 2014;26(3):155-61.
- Lash NJ, Feller JA, Batty LM, Wasiak J, Richmond AK. Bone grafts and bone substitutes for opening-wedge osteotomies of the knee: a systematic review. *Arthroscopy.* 2015;31(4):720-30.
- Slevin O, Ayeni OR, Hinterwimmer S, Tischer T, Feucht MJ, Hirschmann MT. The role of bone void fillers in medial opening wedge high tibial osteotomy: a systematic review. *Knee Surg Sports Traumatol Arthrosc.* 2016;24(11):3584-98.
- Onodera J, Kondo E, Omizu N, Ueda D, Yagi T, Yasuda K. Beta-tricalcium phosphate shows superior absorption rate and osteoconductivity compared to hydroxyapatite in open-wedge high tibial osteotomy. *Knee Surg Sports Traumatol Arthrosc.* 2014;22(11):2763-70.
- Saito T, Kumagai K, Akamatsu Y, Kobayashi H, Kusayama Y. Five- to ten-year outcome following medial opening-wedge high tibial osteotomy with rigid plate fixation in combination with an artificial bone substitute. *Bone Joint J.* 2014;96-B(3):339-44.
- Rouvillain JL, Lavallé F, Pascal-Mousselard H, Catonné Y, Daculsi G. Clinical, radiological and histological evaluation of biphasic calcium phosphate bioceramic wedges filling medial high tibial valgisation osteotomies. *Knee.* 2009;16(5):392-7.