



Cadaveric Atlas for Orthoplastic Lower Limb and Foot Reconstruction of Soft Tissue Defects

Kaitlyn L Ward¹, Anthony Romano¹ and Edgardo R Rodriguez-Collazo^{2*}

¹Franciscan Foot & Ankle Institute, Federal Way, WA, USA

²Presence Saint Joseph Hospital, Chicago, IL, USA

Abstract

Soft tissue deficits or non-healing wounds are a common and challenging problem faced by the lower extremity reconstructive surgeon. These cases often end in proximal amputation, especially in those with co-morbidities, compromised angiosomes, or following significant trauma. This atlas provides a guide for surgeons to understand and treat soft tissue lower extremity defects and complications. We discuss basic orthoplastic reconstructive principles and patient work-up; thus, alleviating the need to refer to a plastic or microsurgical specialist. Additionally, incision placement, anatomy of perforators, axial flow and arc of rotation for flaps are shown for medial, lateral and anterior compartments of the lower leg as well as the foot. The muscular and fascio cutaneous flaps in this atlas can be used to cover almost all areas of the lower extremity from the knee distally to the digits. The purpose of this atlas is to serve as a guide for surgeons to more effectively treat these soft tissue defects without the need for amputation.

Keywords: Orthoplastic; Reconstruction; Soft tissue defects; Flaps; Lower extremity

Introduction and Preoperative Planning

The first step in preparation for performing any flap is precise preoperative planning. Anatomic landmarks should be utilized to map out major neurovascular structures and perforating vessels. Locations and patency of said vessels can be further confirmed with the use of Doppler ultrasound and/or angiography if necessary. A typical map of such structures in the lower extremity is shown in the figures above. Figure 1a shows the major landmarks that should be drawn out pre-operatively. The green lines represent the anterior and medial borders of the tibia. The dashed blue lines represent proper incision placement. They are drawn 1cm posterior and 1cm anterior to the medial and anterior tibial borders respectively. Perforating vessels lie along these blue lines and are marked by the red X's. They correlate with the anatomic map of perforating vessels at approximately 5 cm, 10 cm, and 15 cm proximal to the ankle joint as shown in Figure 1b. Figure 1c shows a contrast angiogram confirming adequate blood flow to the perforators stemming from the major vascular structures of the lower extremity.

Section I: Medial approach to the superficial and deep compartment of the lower leg

- Tibial Exposure
- Medial Gastrocnemius Flap
- Medial Soleal Flap
- Proximal cutaneous sural perforator flap
- Distal cutaneous sural perforator flap

Tibial exposure (for osseous, muscle flap or compartment fasciotomy): In order to avoid any further damage to the cutaneous perforators, tibial exposure should be obtained 1 cm from the medial tibial border. This is noted by the dashed red line in Figure 2a. Locations of the perforators are noted by red X's.

Medial gastrocnemius and medial soleal flap

Incision Planning: As previously stated, a thorough understanding of the relevant anatomical structures and preoperative mapping should be performed. Figure 2b is a cross-section demonstrating important structures and the incision placement when performing the medial gastrocnemius

OPEN ACCESS

*Correspondence:

Edgardo Rodriguez-Collazo,
Department of Surgery, Director
Chicago Foot & Ankle Deformity
Correction Center, Illizarov Correction
& Microsurgical Limb Reconstruction
Presence Saint Joseph Hospital,
Chicago, USA,
E-mail: egodpm@gmail.com

Received Date: 05 Jun 2018

Accepted Date: 21 Jun 2018

Published Date: 28 Jun 2018

Citation:

Ward KL, Romano A, Rodriguez-Collazo ER. Cadaveric Atlas for Orthoplastic Lower Limb and Foot Reconstruction of Soft Tissue Defects. Clin Surg. 2018; 3: 2001.

Copyright © 2018 Edgardo R Rodriguez-Collazo. This is an open access article distributed under the Creative Commons Attribution License, which permits unrestricted use, distribution, and reproduction in any medium, provided the original work is properly cited.

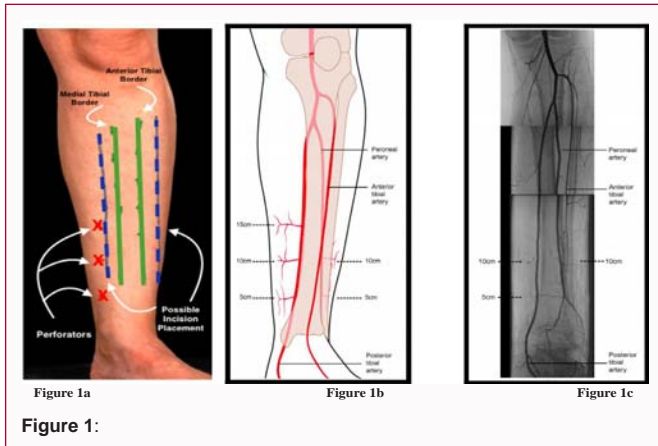


Figure 1:

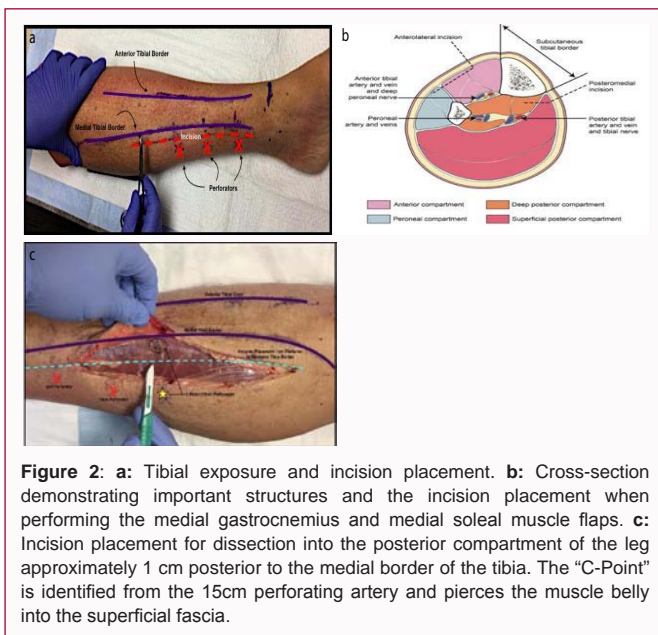


Figure 2: a: Tibial exposure and incision placement. b: Cross-section demonstrating important structures and the incision placement when performing the medial gastrocnemius and medial soleal muscle flaps. c: Incision placement for dissection into the posterior compartment of the leg approximately 1 cm posterior to the medial border of the tibia. The “C-Point” is identified from the 15cm perforating artery and pierces the muscle belly into the superficial fascia.

and medial soleal muscle flaps. Perforators and axial flow should be marked on the posterior border of the tibia at approximately 5 cm, 10 cm, and 15 cm proximal to the ankle joint. An incision is made approximately 1cm posterior to the medial tibial border on the medial aspect of the leg as pictured below in Figure 2c. The perforator 15cm proximal to the ankle is also known as the “C-Point” coined by Dr. Pedro Rodriguez MD. This is where the division of the medial hemi soleus should be performed.

Anatomy of perforators & axial flow: It is important to take care when dissecting down to the fascial planes. The gastrocnemius and soleus muscles lie in the superficial posterior compartment (Figure 3a). The posterior tibial artery supplies this entire compartment with the exception of the medial head of the gastrocnemius (supplied by the medial sural artery). Again, these perforators should be identified at 5 cm, 10 cm, and 15 cm proximal to the ankle joint in the posterior medial compartment of the leg (Figure 3b). Posterior tibial perforators arise from the deep fascia into the superficial compartment (Figure 3c,3d). It is paramount to avoid dissection over the septum because they carry the blood supply.

Arc of Rotation: The division of the medial hemi soleus should be performed to protect the distal perforator at 15cm proximal to the ankle joint, the “C-Point” (Figure 4a). Segmental fascia resection

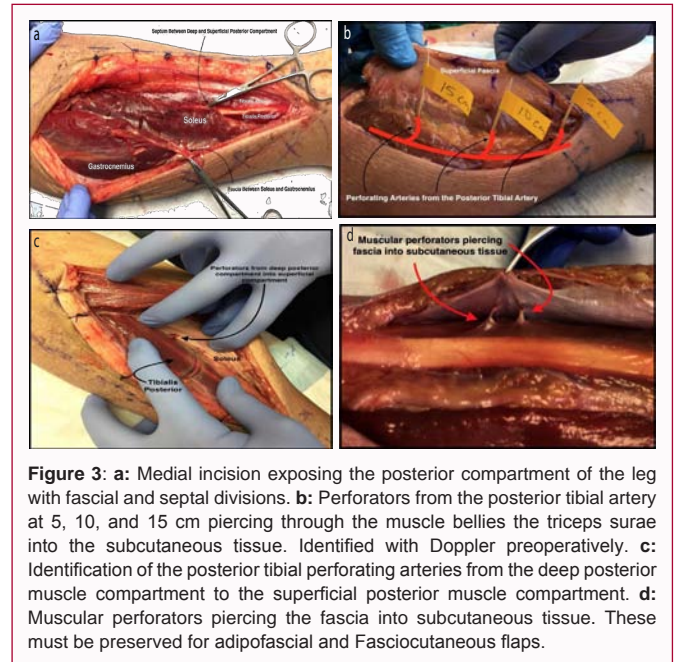


Figure 3: a: Medial incision exposing the posterior compartment of the leg with fascial and septal divisions. b: Perforators from the posterior tibial artery at 5, 10, and 15 cm piercing through the muscle bellies the triceps surae into the subcutaneous tissue. Identified with Doppler preoperatively. c: Identification of the posterior tibial perforating arteries from the deep posterior muscle compartment to the superficial posterior muscle compartment. d: Muscular perforators piercing the fascia into subcutaneous tissue. These must be preserved for adipofascial and Fasciocutaneous flaps.

for additional gastrocnemius and soleus length may be performed if more coverage is needed. The arc of rotation for these flaps allows for adequate coverage of the posterior proximal portion of the leg (proximally based medial gastrocnemius), the anterior leg (distally based medial hemi-soleus) as seen in Figure 4a. The medial hemi-soleus may also provide coverage for the medial malleolar area, posterior heel, distal tibia, and anterior ankle (Figure 4b,4c).

Proximal & distal cutaneous sural perforator flap: Two additional flaps with relevant anatomy to the medial aspect of the lower extremity are the proximal and distal cutaneous adipose fascia sural artery perforator flaps (Figure 4d).

Incision planning and anatomy of perforators & axial flow: The medial aspect of the tibial should be palpated. The perforators for the proximal cutaneous adipose fascia sural artery flap are demonstrated in Figure 4d and 4e. Incision placement is key and needs to include the perforators for vital blood supply.

Arc of Rotation: The Proximally Based Sural Perforator Flap is excellent for coverage of proximal medial tibial defects (Figure 4f) and medial popliteal area (Figure 4g). The Proximally Based Sural Perforator Flap is excellent for coverage of the medial malleolus and calcaneus (Figure 4h), anterior ankle (Figure 4i) and anterior tibia (Figure 4j).

Section II: Approach to the lateral and anterior compartment of the lower extremity

- Peroneus Brevis Flap
- Septal Peroneal Perforator Flap
- Lateral Compartment Options
- Common Peroneal Nerve Exposure
- Proximal Based Lateral Gastrocnemius Muscle Flap
- Anterior Compartment

Peroneus brevis flap

Incision planning: When dissecting the peroneus brevis flap, the

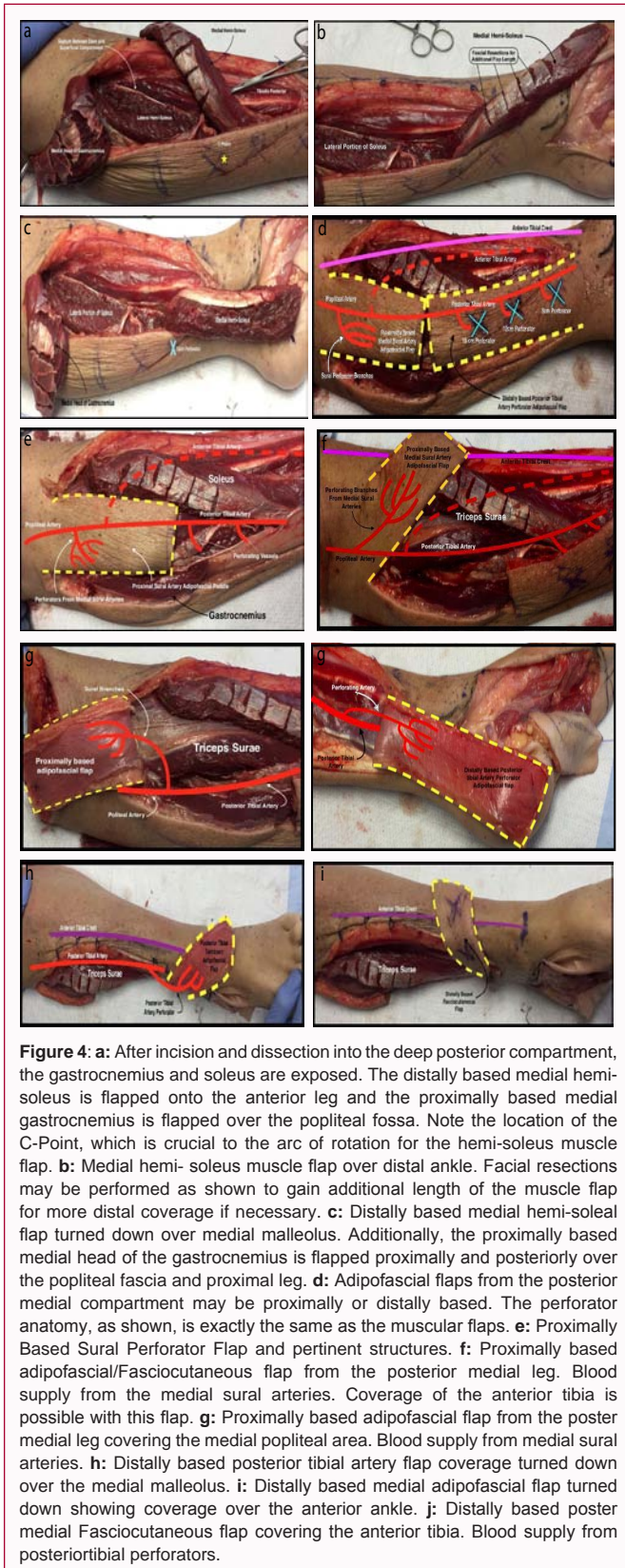


Figure 4: a: After incision and dissection into the deep posterior compartment, the gastrocnemius and soleus are exposed. The distally based medial hemi-soleus is flapped onto the anterior leg and the proximally based medial gastrocnemius is flapped over the popliteal fossa. Note the location of the C-Point, which is crucial to the arc of rotation for the hemi-soleus muscle flap. b: Medial hemi-soleus muscle flap over distal ankle. Facial resections may be performed as shown to gain additional length of the muscle flap for more distal coverage if necessary. c: Distally based medial hemi-soleal flap turned down over medial malleolus. Additionally, the proximally based medial head of the gastrocnemius is flapped proximally and posteriorly over the popliteal fascia and proximal leg. d: Adipofascial flaps from the posterior medial compartment may be proximally or distally based. The perforator anatomy, as shown, is exactly the same as the muscular flaps. e: Proximally Based Sural Perforator Flap and pertinent structures. f: Proximally based adipofascial/Fasciocutaneous flap from the posterior medial leg. Blood supply from the medial sural arteries. Coverage of the anterior tibia is possible with this flap. g: Proximally based adipofascial flap from the poster medial leg covering the medial popliteal area. Blood supply from medial sural arteries. h: Distally based posterior tibial artery flap coverage turned down over the medial malleolus. i: Distally based medial adipofascial flap turned down showing coverage over the anterior ankle. j: Distally based poster medial Fasciocutaneous flap covering the anterior tibia. Blood supply from posteriotibial perforators.

fibular head and lateral malleolus should be palpated and marked. The incision should start approximately 4 cm distal to the fibular head in order to avoid common peroneal nerve damage and is made directly over the fibula as shown in Figure 5b. It is important to take care to avoid incisions over the anterior and posterior borders of the fibula in

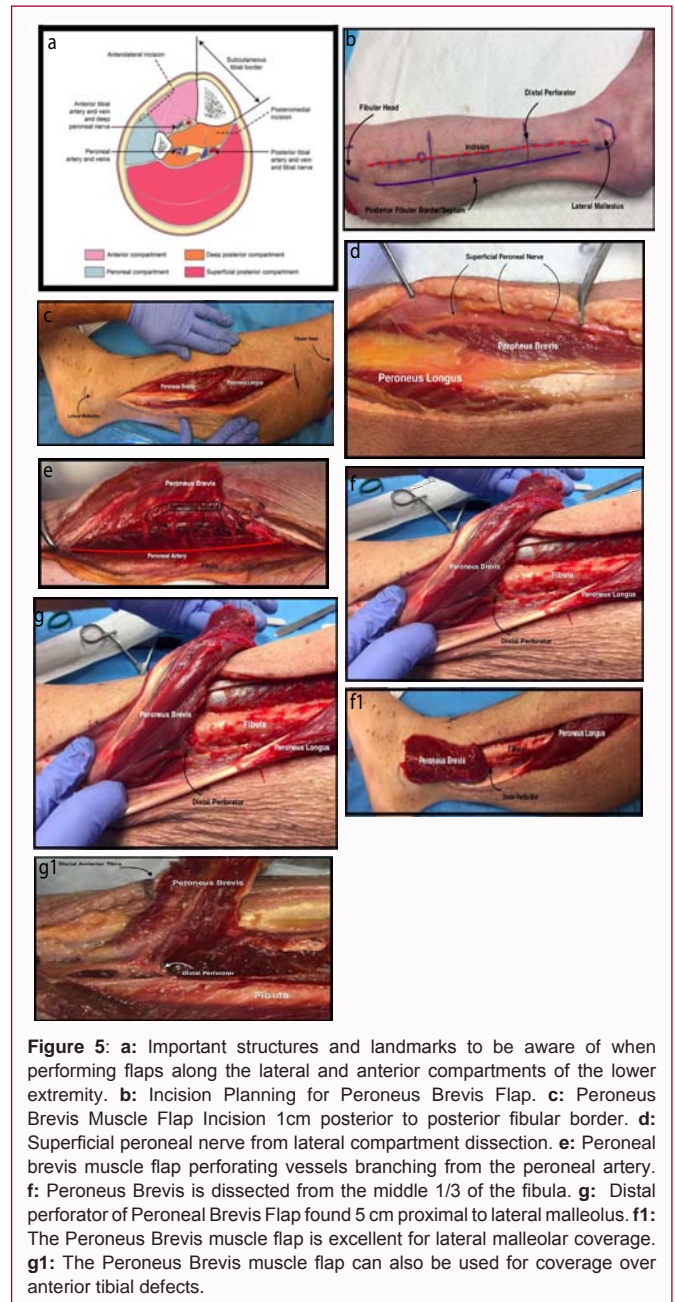


Figure 5: a: Important structures and landmarks to be aware of when performing flaps along the lateral and anterior compartments of the lower extremity. b: Incision Planning for Peroneus Brevis Flap. c: Peroneus Brevis Muscle Flap Incision 1cm posterior to posterior fibular border. d: Superficial peroneal nerve from lateral compartment dissection. e: Peroneal brevis muscle flap perforating vessels branching from the peroneal artery. f: Peroneus Brevis is dissected from the middle 1/3 of the fibula. g: Distal perforator of Peroneal Brevis Flap found 5 cm proximal to lateral malleolus. f1: The Peroneus Brevis muscle flap is excellent for lateral malleolar coverage. g1: The Peroneus Brevis muscle flap can also be used for coverage over anterior tibial defects.

order to preserve septal perforators. The posterior border and septum of the fibula should also be marked. The perforators should also be marked out and typically lie approximately 5 cm, 10 cm, and 15 cm proximal to the lateral malleolus. The viability of the flap is completely dependent on maintaining the distal most perforator. Dissection is sharply carried down through cutaneous, adipose and superficial fascia tissue layers approaching midline (Figure 5c). It is important to carry dissection towards midline in order to avoid the Superficial Peroneal Nerve (SPN) (Figure 5d). The SPN travels anterior to the peroneus brevis muscle over the roof of the anterior compartment or anterior aspect of the floor of the lateral compartment.

Anatomy of perforators & axial flow: As previously mentioned, the perforating vessels from this flap, stem from the peroneal artery and consistently lie approximately 5 cm, 10 cm, and 15 cm proximal to the lateral malleolus; however, they can be much more numerous (Figure 5e).

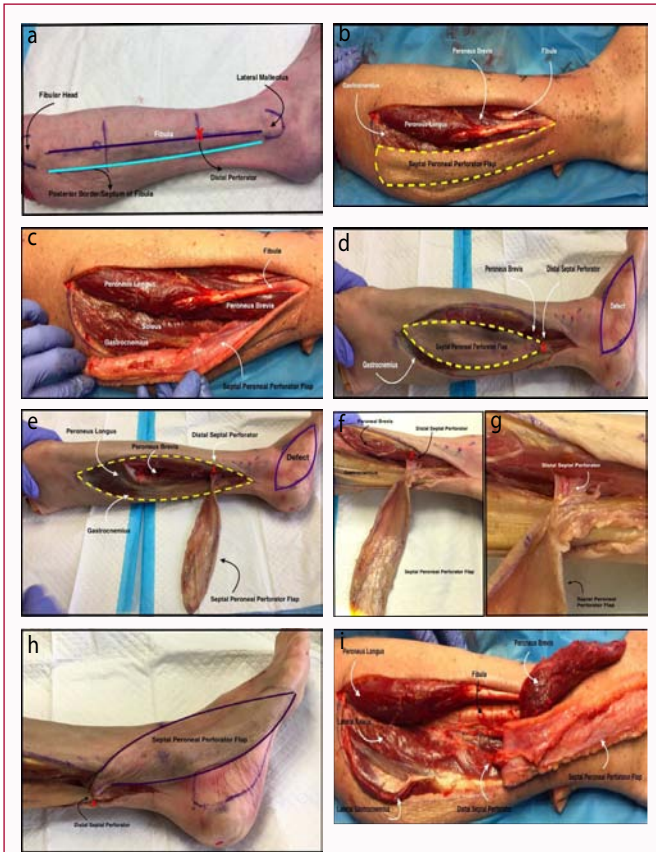


Figure 6: a: Incision planning for the Septal Peroneal Perforator Flap. b: Septal Peroneal Perforator Flap. c: Septal Peroneal Perforator Flap demonstrating the septal, fascia, adipose and cutaneous. d: Variation of the Septal Peroneal Perforator Flap. e: The distal septal perforator is located 10 cm proximal to the lateral malleolus. f: Another look at the distal septal perforator. g: Close up of the distal septal perforator. h: Septal Peroneal Perforator Flap providing lateral malleolar and foot coverage. i: Septal Peroneal Perforator Flap providing lateral malleolar and foot coverage. Peroneal brevis flap providing anterior ankle joint coverage.

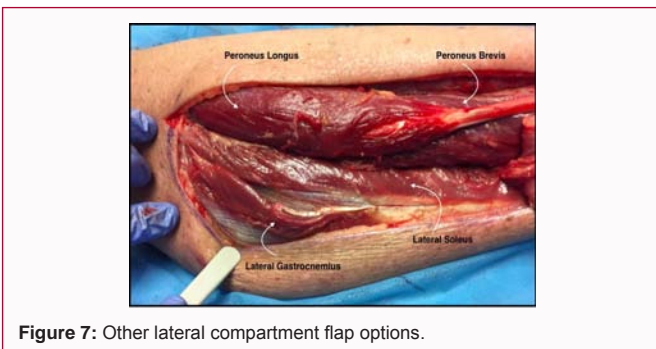


Figure 7: Other lateral compartment flap options.

The peroneus brevis muscle belly is mobilized beginning proximal to distal from the floor of the compartment (superior surface of the flat surface of the middle 1/3 of the fibula) (Figure 5f). The muscle is carefully teased off the fibula until the level of the distal most perforator approximately 5cm to 7 cm proximal to the lateral malleolus (Figure 5g).

Arc of rotation: The peroneus brevis muscle flap has been termed the “work horse flap” of the lower extremity due to its large arc of rotation and many applications. These include: lateral malleolus (Figure 5f), retrocalcaneal and Achilles insertion (posterior and plantar calcaneus). Additionally, it is adequate for anterior tibia and

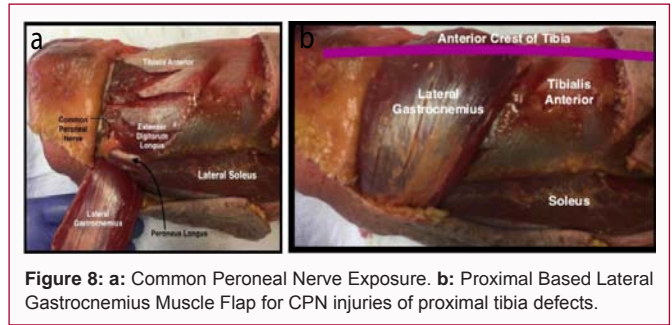


Figure 8: a: Common Peroneal Nerve Exposure. b: Proximal Based Lateral Gastrocnemius Muscle Flap for CPN injuries of proximal tibia defects.

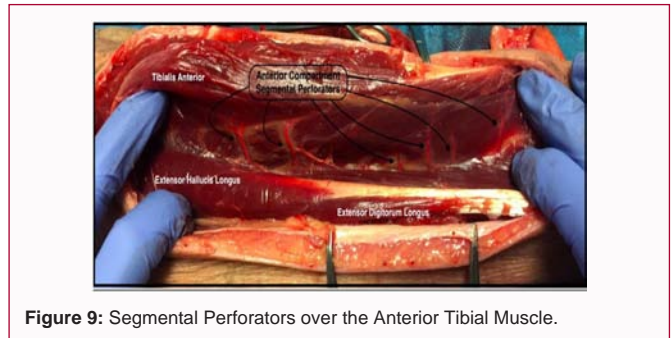


Figure 9: Segmental Perforators over the Anterior Tibial Muscle.

ankle defects (Figure 5g).

Septal peroneal perforator flap

Incision planning: When dissecting the septal peroneal perforator flap, the posterior border of the fibula should be palpated and marked as shown in Figure 6a with a blue line. It is vital to keep dissection away from this line as it also corresponds with the posterior-lateral septum, the perforators and all the necessary blood flow to this flap. The lateral malleolus should also be marked out. The distal perforator for this flap is typically 10cm proximal to ankle joint and is marked by the red X in Figure 6a. Dissection is sharply carried down through cutaneous, adipose and superficial fascia tissue (Figure 6c). It is important to keep a paddle of 2 cm (at minimum) on either side of the posterior septum in order to ensure adequate blood supply to the flap (Figure 6b and 6d).

Anatomy of perforators & axial flow: As previously mentioned the distal septal perforator for this flap is typically located approximately 10 cm proximal to the lateral malleolus (Figures 6e-6g).

Arc of rotation: This flap has similar indications as the peroneus brevis flaps and includes: anterior tibia, lateral foot (Figure 6h and 6i), lateral malleolus (Figure 6h and 6i), retrocalcaneal and Achilles insertion.

Lateral compartment exposure: It should be noted that the lateral compartment dissection technique also allows for exposure to the lateral gastrocnemius, lateral soleus, peroneus longus muscle flaps as well (Figure 7a).

Common peroneal nerve exposure: One key structure in this area is the common peroneal nerve. It can be accessed effectively through the lateral compartment (Figure 8a).

Proximal based lateral gastrocnemius muscle flap: for those practitioners involved with microsurgical techniques and treating revisional common peroneal nerve injuries or proximal tibia defects, it is important to be aware that the proximal based lateral

gastrocnemius is a flap that can be harvested in this area (Figure 8b). This flap receives its blood supply from the sural artery.

Anterior compartment (Figure 9a)

Section III: Medial arch approach for the foot

- Medial Plantar Artery Cutaneous Adipofascia Flap
- Abductor Hallucis Muscle Flap
- Flexor Digitorum Brevis Muscle Flap
- Flexor Hallucis Brevis Muscle Flap
- Plantar Fasciocutaneous Flap

Medial plantar artery cutaneous adipofascia flap

Incision planning: When performing the medial plantar artery cutaneous adipofascia flap the following structures are important to identify and mark: calcaneus, metatarsal heads and 3rd ray (Figure 10a). The dissection for this flap will take place medial to the 3rd ray. Dissection begins laterally and is carried full thickness down to muscle of the medial instep of the foot.

Anatomy of perforators & axial flow: Blood flow for this flap is dependent upon the medial plantar artery and its corresponding perforators (Figure 10b). It is crucial to keep the septum intact.

Arc of rotation: This flap is excellent for coverage of tarsal tunnel or medial malleolus, dorsal foot and plantar foot.

Abductor hallucis muscle flap

Incision planning: The same landmarks, structures and incision as the Medial Plantar Artery Cutaneous Adipofascia are utilized for the Abductor Hallucis Muscle flap (Figure 10a). The dissection for this flap will take place medial to the 3rd ray. Dissection begins laterally and is carried full thickness down to muscle of the medial instep of the foot. The Abductor Hallucis Muscle is then identified and transected distally.

Anatomy of perforators & axial flow: Blood flow for this flap is dependent upon the medial plantar artery and its corresponding perforators (Figure 10b).

Arc of rotation: This flap is excellent for coverage of plantar calcaneal and plantar midfoot defects (Figure 10c).

Flexor digitorum brevis flap

Incision planning & anatomy of perforators & axial flow: The flexor digitorum brevis flap is typically harvested through a plantar midline incision extending from the metatarsal heads and carried towards the calcaneus (Figure 10d). It is important to note that the incision placement preserves the medial plantar skin for medial plantar artery adipofascial flaps. Branches from the lateral plantar artery mainly supply the muscle, but there is contribution from the medial plantar artery as well. These arteries should be identified and marked with a Doppler preoperatively. Dissection is taken through the plantar fascia which is retracted medially and laterally to expose the flexor brevis muscle belly. Once the muscle is identified, the tendinous portion to the toes is transected at the metatarsal neck (Figure 10d). Dissection is then carried from distal to proximal on the plantar foot. Dissection is then taken as proximal as needed while preserving the proximal as needed while preserving the proximal perforators that have been identified.

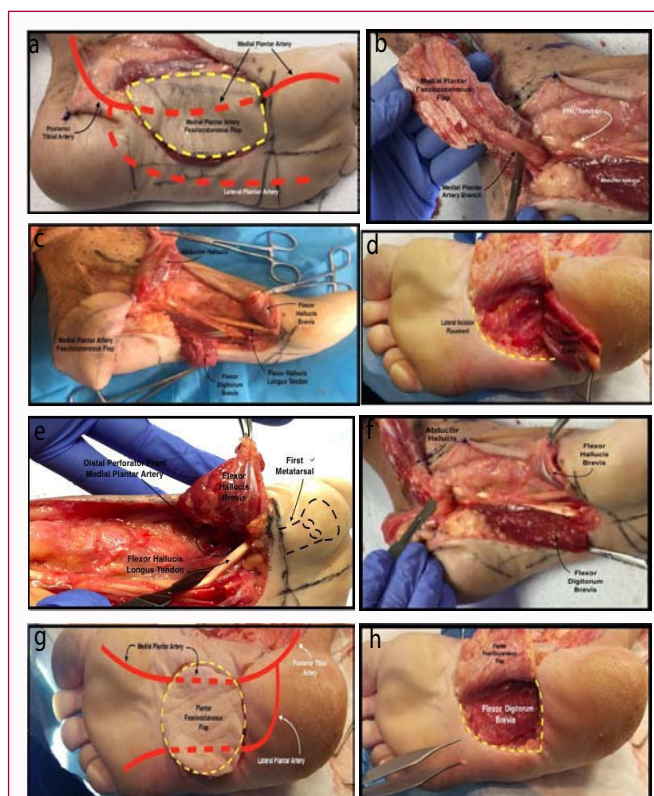


Figure 10: a: Medial plantar artery flap with incision placement. Blood supply mainly from medial plantar artery.

Blood supply is mapped preoperatively with a Doppler. **b:** Medial plantar artery Fasciocutaneous flap with blood supply from medial plantar artery (proximally based) with dissection at the level of the tarsal tunnel. **c:** Medial foot flaps depicting the versatility of intrinsic and fasciocutaneous flaps coverage of foot defects as shown. **d:** Incision placement and dissection of proximally based flexor digitorum brevis flap. Exposed portion of the FDB is transected at the level of the tendinous portion. Note the incision placement preserves the medial plantar skin for medial plantar artery adipofascial flaps. The flap is excellent for coverage of proximal plantar calcaneus. **e:** Flexor hallucis brevis flap and the distally based perforator off of the medial plantar artery. Note the distal coverage sub first metatarsal head. **f:** Dissection of the medial and plantar foot at the level of the tarsal tunnel and distal showing proximally and distally bases muscle flaps with blood supply from the medial and lateral plantar arteries. **g:** Plantar Fasciocutaneous flap with perforating arteries from both medial and lateral plantar arteries. **h:** Exposure of the flexor digitorum brevis and dissection of plantar Fasciocutaneous flap. Coverage of medial arch defects can be obtained with this flap.

Arc of rotation: Coverage of plantar calcaneal and medial foot defects are possible with this muscle as seen in Figure 10d.

Flexor hallucis brevis flap

Incision planning & anatomy of perforators & axial flow: The flexor hallucis brevis may be harvested deep to the abductor hallucis muscle belly. This flap is mainly supplied by the medial plantar artery (Figure 10e). Preoperative mapping should be performed with a Doppler.

Arc of rotation: The main advantage of using this flap is that it may be distally based to provide coverage for the plantar aspect of the first metatarsophalangeal joint as seen in Figure 10e,10f.

Plantar fasciocutaneous flap

Incision planning & anatomy of perforators & axial flow: The Plantar Fasciocutaneous Flap incision is performed on the plantar arch and is demarcated by the dashed yellow lines in Figure 10g.

Blood supply to this flap comes from both medial and lateral plantar arteries.

Arc of rotation: Coverage of medial arch defects can be obtained with this flap (Figure 10h).

References

1. Nanchahal J, Nayagam S, Khan U, Moran C, Barrett S, Sanderson F, et al. Standards for the Management of Open Fractures of the Lower Limb. Royal Society of Medicine Press Ltd. 2009.