



Bubbling Parotitis

Deepti Sinha^{1,3}, Jacqueline Brown² and Kathleen Fan^{1*}

¹Department of Oral and Maxillofacial Surgery, King's College Hospital, UK

²Department of Oral Radiology, Guys' Hospital, UK

³Department of Oral and Maxillofacial Surgery, OMFS-IMPACT Research Group, Katholieke University, Belgium

Abstract

Acute bilateral parotitis is a rare presentation in adults. Most often the underlying pathology is systemic unless exposure to a viral epidemic is confirmed.

We report an unusual case of a 50-year-old female patient presenting to our department with intermittent bilateral parotid swelling of unknown origin. Clinical findings included apyrexia, bilateral non-tender facial swelling. Bimanual palpation of the Stenson's duct revealed expulsion of air bubbles *via* the duct orifice. Ultrasound examination confirmed the presence of hyperechoic structures suggestive of air bubbles within the duct and the surrounding salivary gland tissue.

Pneumoparotitis is a rare cause of parotid gland swelling and is most commonly thought to occur when air is forced through the parotid duct from a pressurized oral cavity. It can present as a unilateral or bilateral swelling, is usually non-tender and almost often resolves spontaneously. It is commonly seen in wind instrument players, glass blowers and scuba divers.

Although rare recurrent pneumoparotitis can predispose to sialectasis, recurrent parotitis and subcutaneous emphysema tracking to the neck, mediastinum and potentially pneumothorax. Diagnosis is based mainly on history, but is often missed. The objective of this abstract is to draw the attention of the clinician towards a rare but entirely benign cause for bilateral parotid swelling in adults.

Keywords: Pneumoparotid; Atypical sialadenitis; Recurrent pneumosialadenitis

Introduction

Unilateral swellings of the major salivary glands are a common entity in clinical practice. The pathogenesis of which can be attributed to several reasons, the most common being an infective cause such as a bacteria or virus. Bilateral swellings in adult patients on the other hand are uncommon. If present, they are usually encountered in post-menopausal patients and are most often associated with an underlying systemic illness [1].

There are several ways to classify swellings associated with major salivary gland associated in adults. An easy clinically reproducible classification is broadly dividing the swellings based on their appearance in to diffuse and circumscribed (Figure 1).

In general, circumscribed lumps present clinically as either painful or painless swellings. The differential diagnosis includes tumor pathology (benign or malignant), lymphoma or cysts when they are painless. Reactive lymphadenitis, *actinomyces*, cat scratch disease, toxoplasma, atypical mycobacterial lymphadenitis may be considered as differentials when pain is an associated feature. Although several other clinical features like nerve involvement, overlying skin changes, etc. may suggest a more sinister diagnosis these features however are not always consistently found and therefore the presence or absence of pain is more crucial a feature in distinguishing the nature of the lesion clinically. To establish a diagnosis first line investigations for a circumscribed swelling include an ultrasound scan and fine needle aspiration cytology. When the swelling is suspicious other diagnostic adjuncts such as an MRI or PET-CT are used. Serology is very useful in infective cases.

The story is slightly different for diffuse swellings, in that pain is a constant feature and therefore provides very little in terms of clinical clues towards establishing a differential diagnosis. However, dividing them in to unilateral or bilateral lumps is diagnostically more relevant. Unilateral diffuse swellings in adults are generally a sialadenitis. Based on chronicity they can be further classified in to acute or chronic sialadenitis. As these swellings are usually bacterial in origin first line

OPEN ACCESS

*Correspondence:

Kathleen Fan, Department of Oral and Maxillofacial Surgery, King's College Hospital, London, UK, Tel: +44(0) 2032999000; Fax: +44 (0) 2032993754;

E-mail: kfan@nhs.net

Received Date: 13 Apr 2020

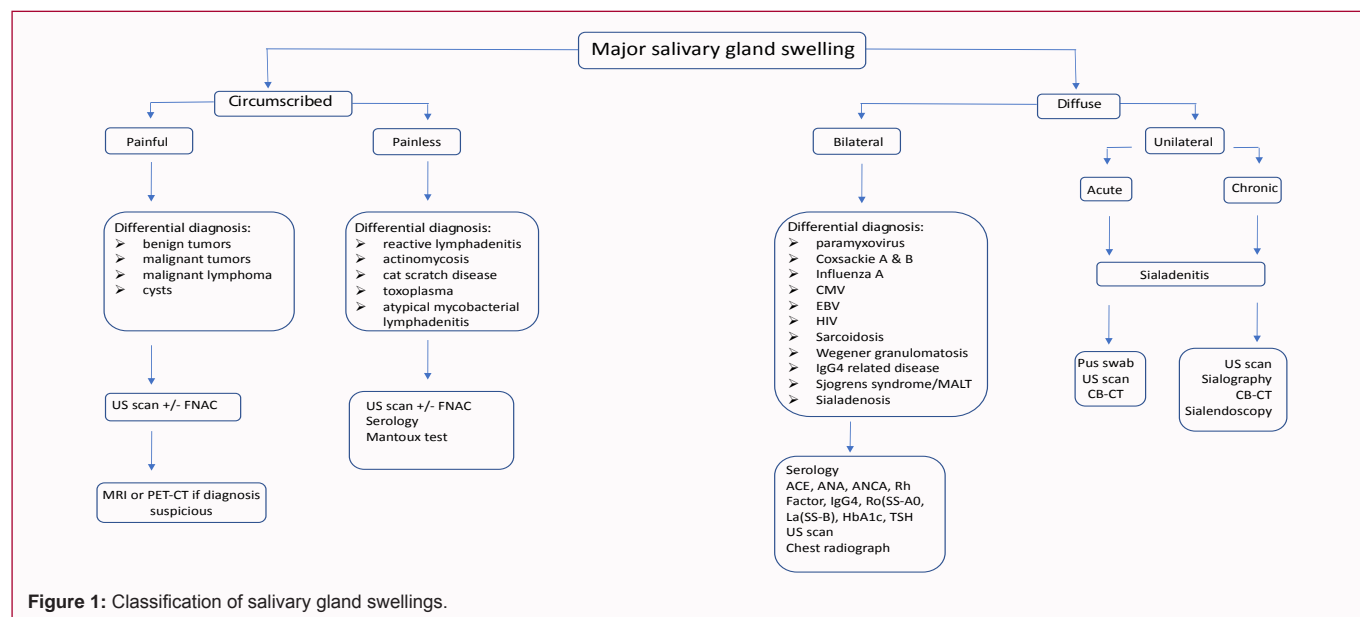
Accepted Date: 24 Apr 2020

Published Date: 28 Apr 2020

Citation:

Sinha D, Brown J, Fan K. Bubbling Parotitis. *Clin Surg*. 2020; 5: 2812.

Copyright © 2020 Kathleen Fan. This is an open access article distributed under the Creative Commons Attribution License, which permits unrestricted use, distribution, and reproduction in any medium, provided the original work is properly cited.



investigations include a pus swab for microbiology if pus is present, followed by an ultrasound scan and sialography or a cone beam CT. Bilateral swellings are more representative of an underlying systemic condition such as sarcoidosis, Wegner's, Sjogrens, MALT lymphoma, IgG4 glandular sialadenitis, sialadenitis, coxsackie A & B virus, paramyxovirus, influenza A, CMV, EBV and HIV. First line investigations for bilateral swellings includes an ultrasound scan and a battery of blood tests such as serology, Angiotensin Converting Enzyme (ACE), Antinuclear Antibodies (ANA), rheumatoid factor, IgG4, Ro (SS-A), La (SS-B), HbA1c and TSH. A chest radiograph is usually also done for the sake of completeness. Occasionally a tissue sample may be required. While this classification is useful as an aide memoir for commonly encountered salivary swellings in clinical practice it is not exhaustive.

"Pneumoparotid" is used to describe obvious air in the parotid duct or gland in the absence of demonstrable inflammation or infection [2,3]. "Pneumoparotitis" the resulting inflammation of the parotid gland is caused by recurrent pneumoparotid. Various other synonyms are used in literature to describe the condition such as; pneumosialadenitis, wind parotitis, surgical mumps, anesthesia mumps and pneumatocele glandula parotis [4]. The first case of pneumoparotitis reported in literature on musicians learning to play wind instruments were by Hyrtl in 1865 [5].

It occurs in both children and adults and can be unilateral or bilateral. In adults, it commonly presents as an occupational hazard associated with wind instrument playing, glass blowers, balloon blowers, divers and watch keepers in high barometric pressure environment or can be iatrogenically induced by positive pressure ventilation [6], Valsalva manoeuvres, after spirometry, endoscopy, during acquisition of computed tomography and dental treatment [1,7]. In pediatric and adolescents self-induced pneumoparotitis has been reported almost exclusively and often these children have psychosocial problems (Markowitz-Spence 1987).

Various articles have attempted to put forth some plausible explanations towards the occurrence of this phenomenon. They can be broadly divided in to two categories local anatomical considerations and high pressure theory.

The anatomical design of the Stenson's duct itself confers up on it the ability to prevent reflux of air by the orifice being embedded in redundant mucosal folds and its actual diameter being much smaller than that of the duct [1]. Moreover, the orifice has a slit like opening. The duct itself along its lateral course is compressed between the buccinators and masseter muscles [1]. These virtues contribute a protective mechanism to the entry of air *via* the orifice. When these protective anatomical features are lost, it could predispose to reflux of air in to the duct and cause its spread in to the acini.

The high-pressure theory suggests that when the intra oral pressure is sufficiently raised like in situations such as blowing, coughing, sneezing, etc. in combination with the anatomical variations can give rise to air within the ductal system. Air is insufflated into the acini of the gland *via* the duct. This insufflated air then may rupture the walls of the acini and spread in to the surrounding subcutaneous tissues causing emphysema [1].

Clinical presentation is usually a facial swelling localized to the pre-auricular and parotid gland region and can be unilateral or bilateral. Pain is not a constant finding. Erythema and temperature changes of the overlying skin are suggestive of infection. A few other findings such as crepitus and frothy saliva may provide clues towards diagnosis of the condition. Incidentally none of the clinical features are consistent in presentation. History therefore is imperative and usually sufficient to establish the diagnosis. With regards to the different imaging modalities that can be used, first line investigation is an ultra sound scan. However, when in doubt a cone beam computed tomography can be performed. Sialography is not diagnostically helpful as it only shows a filling defect which could be indicative of other pathology such as a sialolith, tumor or stricture.

Most cases are managed conservatively as the discomfort is transient and the swelling self-resolving. Surgical intervention is occasionally required to manage the resulting complications namely; surgical emphysema affecting the face, neck, mediastinum and subsequent pneumothorax [4].

Case Presentation

A 50-year-old female patient presented to our outpatient

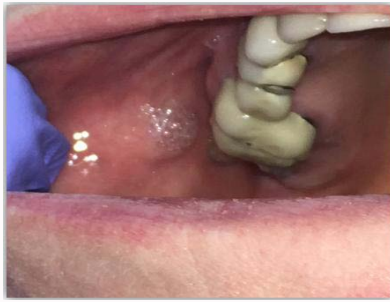

Figure 2: Frothy saliva expressed from the duct orifice.

department clinic with complaints of recurrent bilateral facial swellings. The facial swelling was spontaneous, intermittent, bilateral confined to the pre-auricular and parotid regions and were non-tender. She denied a history of meal time associated symptoms or pyrexia. There were no aggravating or relieving factors that could be identified. No identifiable systemic illnesses were found that could be related to her symptoms.

Clinical examination revealed obvious bilateral facial swellings confined to the parotid gland region with normal looking overlying skin on inspection. Palpation of the swelling did not reveal any altered temperature changes to the skin however crepitus suggestive of emphysema could be felt on palpation. Bimanual palpation of the Stenson's duct revealed air bubbles at the orifices of the ducts readily (Figure 2). Clear saliva was expressed thereafter.

In the absence of an obvious underlying cause an ultra sound scan was requested. Ultrasound examination confirmed the presence of hyperechoic air bubbles within the duct and the surrounding salivary gland tissue confirming the diagnosis of pneumoparotitis.

On further questioning the patient admitted to habitually puffing of her cheeks which helped confirm the diagnosis of pneumoparotitis (Figure 2). Treatment was conservative with encouragement to break the habit.

Conclusion

Unilateral swellings of the major salivary glands are a common entity in clinical practice. The causative factors of which range from localized infections to more sinister lesions. Bilateral swellings on the other hand are uncommon and are usually associated with an underlying systemic disease.

Pneumoparotitis is a rare clinical presentation. It can be unilateral

or bilateral. Occupational hazards, iatrogenic and psychosocial factors are common associations. Unilateral swelling is more commonly associated with iatrogenic cases. The condition can be transient or recurrent. With minimal positive clinical findings, history is imperative for diagnosis and management. Although rare recurrent pneumoparotitis can predispose to sialiectasis, recurrent parotitis and subcutaneous emphysema tracking to the neck, mediastinum and potentially pneumothorax.

Conventional imaging such as an ultra sound is the first line investigation and can sufficiently identify air within the duct and gland; however in cases of doubt a CBCT can be a useful tool. Sialography is unhelpful in these cases.

Management is conservative due to its transient nature. Surgical intervention is occasionally required to manage the resulting complications namely; surgical emphysema affecting the face, neck, mediastinum and subsequent pneumothorax [1].

It is interesting to note that the cases described in literature arise from several disciplines, highlighting the fact that its presentation is not just confined to the maxillofacial office.

References

1. Bhat V, Kuppuswamy M, Santosh Kumar DG, Bhat V, Karthik GA. Pneumoparotid in "puffed cheek" computed tomography: Incidence and relation to oropharyngeal conditions. *Br J Oral Maxillofac Surg.* 2015;53(3):239-43.
2. Luaces R, Ferreras J, Patiño B, Garcia-Rozado A, Vázquez I, López-Cedrún JL. Pneumoparotid: A case report and review of the literature. *J Oral Maxillofac Surg.* 2008;66(2):362-5.
3. Cook JN, Layton SA. Bilateral parotid swelling associated with chronic obstructive pulmonary disease. A case of pneumoparotid. *Oral Surg Oral Med Oral Pathol.* 1993;76(2):157-8.
4. Ahuja CK, Yadav MK, Gupta V, Khandelwal N. Incidental pneumoparotid detected on computed tomography: Should it raise an alarm? *Oral Surg Oral Med Oral Pathol Oral Radiol.* 2012;114(6):792-5.
5. Markowitz-Spence L, Brodsky L, Seidell G, Stanievich JF. Self-induced pneumoparotitis in an adolescent. Report of a case and review of the literature. *Int J Pediatr Otorhinolaryngol.* 1987;14(2-3):113-21.
6. Watt J. Benign parotid swellings: A review. *Proc R Soc Med.* 1977;70(7):483-6.
7. Piette E, Walker RT. Pneumoparotid during dental treatment. *Oral Surg Oral Med Oral Pathol.* 1991;72(4):415-7.