



## Brownish Black Nodule Over Foot - A Subtle Presentation of a Grave Disorder Image

Seema Manjunath, Anuradha Bishnoi and Muthu Sendhil Kumaran\*

Department of Dermatology, Venereology and Leprology, Post Graduate Institute of Medical Education and Research, India

### Clinical Image

A 58-year-old male presented with 1-year history of blackish asymptomatic nodule on right sole, which initially started as pinhead sized papule and progressed to present size. No previous history of bleeding or oozing from lesion. Patient denied history of trauma or a prior melanocytic nevus. Clinical examination revealed well-defined, irregular, brownish black, infiltrated nodular plaque measuring 6 cm × 7 cm over right heel (Figure 1a). There was no lymphadenopathy. Dermoscopy of lesion revealed multiple colors (ranging from dark brown, blue, gray, and black), irregular brown and black dots and globules suggesting diagnosis of melanoma (Figure 1b), which was confirmed on histopathology.

Melanoma in Indians is rare compared to Caucasians with age specific incidence less than 0.5 per 1,000,000. Those arising from nail unit or sole often presents late, contributing to diagnostic delay and hence poor outcome [1]. Dermoscopy is a powerful tool helping to diagnose melanoma early even before specific histopathological findings develops and helps ruling out other pigmented lesions [2].

### OPEN ACCESS

#### \*Correspondence:

Muthu Sendhil Kumaran, Department of Dermatology, Venereology and Leprology, Post Graduate Institute of Medical Education and Research, 160012, Chandigarh, India, Tel: 91-9876930521;

E-mail: drsen\_2000@yahoo.com

Received Date: 19 Feb 2019

Accepted Date: 26 Mar 2019

Published Date: 02 Apr 2019

#### Citation:

Manjunath S, Bishnoi A, Sendhil Kumaran M. Brownish Black Nodule Over Foot - A Subtle Presentation of a Grave Disorder Image. Clin Surg. 2019; 4: 2384.

**Copyright** © 2019 Muthu Sendhil Kumaran. This is an open access article distributed under the Creative Commons Attribution License, which permits unrestricted use, distribution, and reproduction in any medium, provided the original work is properly cited.

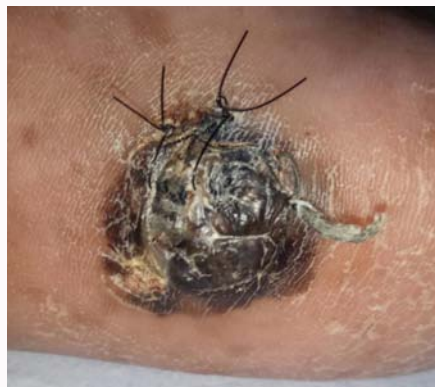

Figure 1a: Brownish black pigmented infiltrated nodular plaque with irregular border over right heel.

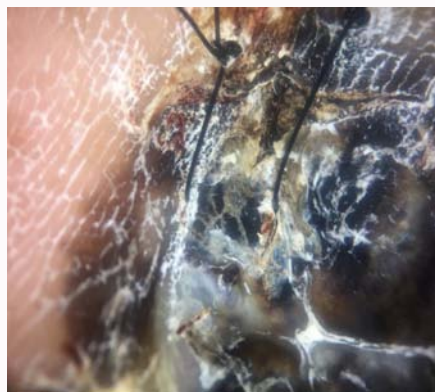


Figure 1b: Dermoscopy showing multiple colors (ranging from tan, dark brown, blue, gray, and black), irregular blotches, irregular brown dots and globules, and black color.

## References

1. Bristow IR, de Berker DA, Acland KM, Turner RJ, Bowling J. Clinical guidelines for the recognition of melanoma of the foot and nail unit. *J Foot Ankle Res.* 2010;3:25.
2. Menzies SW, Moloney FJ, Byth K, Avramidis M, Argenziano G, Zalaudek I, et al. Dermoscopic evaluation of nodular melanoma. *JAMA Dermatol.* 2013;149(6):699-709.