



Bowel Perforation Surgery due to Fecal Impaction Immediately after Hernia Mesh Surgery (TAPP)

Choi JB, Lee BC*, Han JH, Noh BG, Park JK, Park YM, Jung HJ and Jo HJ

Department of Surgery, Pusan National University Hospital, South Korea

Abstract

Inguinal hernia repair using prosthetic mesh is standard treatment in most countries and accepted as superior to primary suture repair. Although the risk of recurrence was reduced by using prosthetic mesh during hernia surgery, the risk of mesh infection remains. A 71-year-old man presented with symptomatic bilateral inguinal hernias. He underwent successful laparoscopic Transabdominal Preperitoneal (TAPP) repair and was discharged the same day. Three days later, he presented with small bowel perforation, and underwent emergency surgery. We identified perforation of the distal ileum by fecal impaction and severe intra-abdominal contamination. We performed subtotal colectomy and ileosigmoid anastomosis, but did not remove the prosthetic mesh because the previous TAPP site was intact. The patient recovered well postoperatively. Contaminated or dirty surgery immediately after the hernia mesh surgery could be safely performed.

Introduction

Transabdominal Preperitoneal hernia (TAPP) repair is an approved and common surgical approach for the treatment of inguinal hernia in adults, particularly for bilateral and recurrent inguinal hernia after open surgery [1]. With the advent of prosthesis, the outcome of hernia repairs has indeed improved significantly. But there are still other issues to be resolved, including mesh infection. In case of ventral hernia repair using mesh, it is known that the use of prosthetic mesh in infected fields should be prohibited, and has been reported that superficial infections occur 2.5 and 3.8 times more frequently in cleanliness-contaminated and contaminated patients, respectively, than in cleanliness patients [2]. It is crucial to propose that the use of prosthetic mesh in contaminated hernias should be restricted regardless of the level of contamination. However, there is no consensus on the use of prostheses in potentially infected surgical fields in cases of TAPP and there is no specific guideline for what to do if the mesh is contaminated shortly after hernia repair. We would like to share our experience of a patient who had perforated peritonitis three days following TAPP surgery.

Case Presentation

A 71-year-old man presented to the surgical department with symptomatic bilateral inguinal hernias and he had undergone robot-assisted radical prostatectomy two years ago. The bilateral inguinal hernias were evident on clinical. He underwent successful laparoscopic Transabdominal Preperitoneal (TAPP) repair and was discharged on operation day (Figure 1).

Three days later after discharge, he presented to the emergency room with severe abdominal pain. He did not have bowel movement for a week. We found that he had severe constipation and frequently dug up the stool with his fingers. A physical examination revealed abdominal distension and rigidity with rebound tenderness. The patient's blood pressure was 110/70 mmHg, pulse rate was 116 beats/min, and body temperature was 38.0°C. In the complete blood count, a white blood cell count was $2.04 \times 10^3/\text{mm}^3$ and hemoglobin was 13.5 g/dL. The C-reactive protein was 34.33 mg/dL, Procalcitonin was 14.50 ng/mL, and Creatinine was 1.79 mg/dL. He underwent Computed Tomography (CT), which showed focal bowel wall defect was observed at the distal ileum, and complicated fluid collection and free air in the abdominal cavity (Figure 2). The patient was diagnosed small bowel perforation due to fecal impaction and underwent emergency surgery.

On laparoscopic exploration, we identified perforation of the distal ileum by fecal impaction and severe intra-abdominal contamination (Figure 3). The entire colon was filled with very hard stool and the cecum was dilated up to 11 cm. We decided to perform surgery for bowel perforation and constipation at the same time. We performed subtotal colectomy and ileosigmoid anastomosis,

OPEN ACCESS

*Correspondence:

Byoung Chul Lee, Department of Surgery, Pusan National University Hospital, 179, Gudeok-ro, Seo-gu, Busan 49241, South Korea, Tel: 82-51-240-7238; Fax: 82-51-247-1365; E-mail: gsb3927@gmail.com

Received Date: 26 Oct 2022

Accepted Date: 14 Nov 2022

Published Date: 17 Nov 2022

Citation:

Choi JB, Lee BC, Han JH, Noh BG, Park JK, Park YM, et al. Bowel Perforation Surgery due to Fecal Impaction Immediately after Hernia Mesh Surgery (TAPP). *Clin Surg*. 2022; 7: 3591.

Copyright © 2022 Lee BC. This is an open access article distributed under the Creative Commons Attribution License, which permits unrestricted use, distribution, and reproduction in any medium, provided the original work is properly cited.

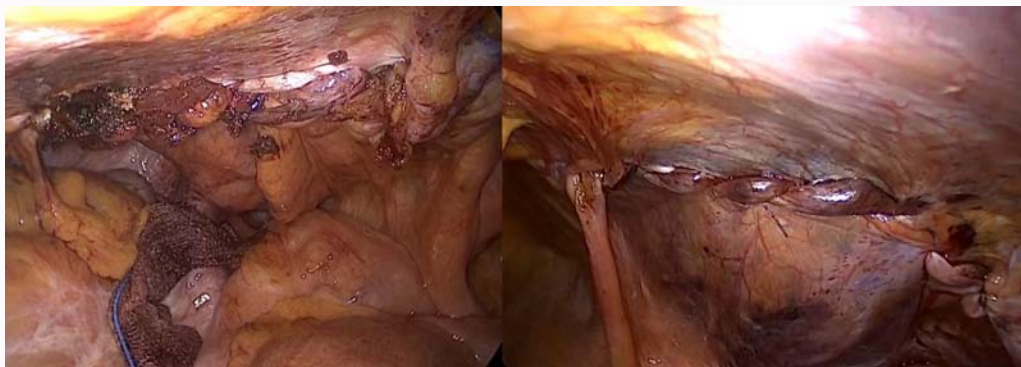

Figure 1: Laparoscopic images after laparoscopic hernia repair.

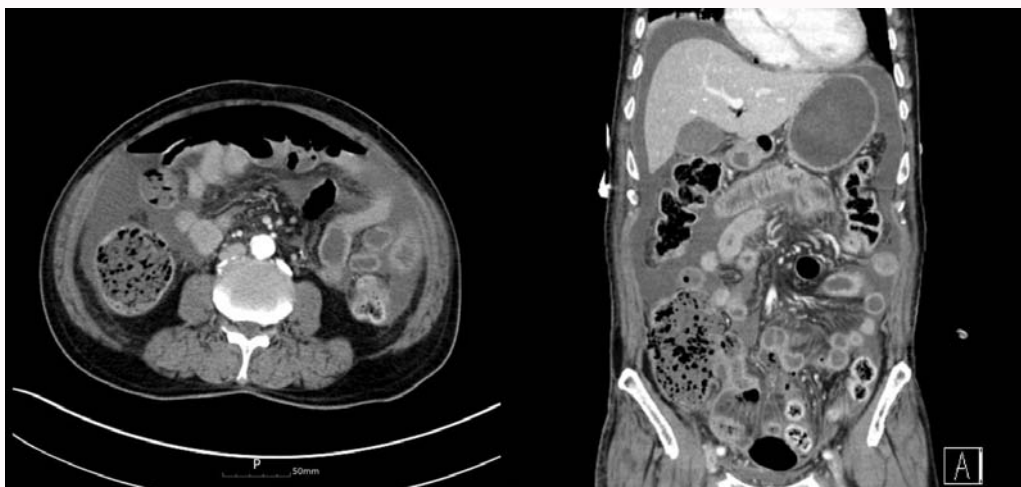


Figure 2: Abdomen CT showed complicated fluid collection and free air in the abdominal cavity.

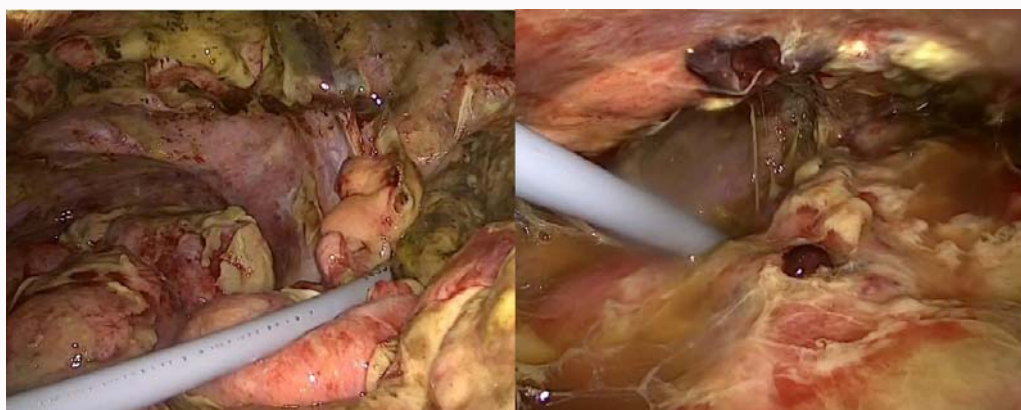

Figure 3: Laparoscopic images of bowel perforation and severe intra-abdominal contamination.

but did not remove the prosthetic mesh because the previous TAPP site was intact. The patient recovered well and was discharged on postoperative day 9. He has been followed up on for the past one year and has shown no signs of infection and he has a normal stool once a day.

Discussion

Numerous studies revealed that patients who underwent laparoscopic repair had low recurrence rate, fewer postoperative

complications, were discharged earlier and able to return to their daily lives more quickly than patients who underwent open hernia [2]. However, they did not clarify which is the best laparoscopic approach for inguinal hernia repair. TAPP is becoming increasingly popular in herniorrhaphy, especially when previous herniorrhaphy was open or when both hernia operations are required. Complications have been reported in various ways, such as pain, infection, recurrence, and so on. Among them, the frequency of mesh infection is very low (0.1% to 0.2%) [3].

Belansky et al. [4] describes the pathophysiology of mesh infection, which is contaminated by bacteria within the first 24 h to 48 h and is not integrated with surrounding tissues, forming an impermeable membrane, such as biofilm, without blood flow. Once a biofilm is formed on the surface of the mesh, infection cannot be removed, and treatment is often difficult, so in most cases, even in case where antibacterial agent is preserved and cured, recurrence is repeated and the mesh is finally removed. Therefore, many surgeons are paying attention to intraoperative infections.

Contamination of a field during a hernia repair can occur secondary to many factors such as an inadvertent enterotomy or need for concomitant bowel resection a time of repair [2]. Xourafas et al. [5] examined the impact of mesh on ventral hernia repair with a simultaneous bowel resection and found a significantly higher incidence of infections and other complications in patients that had mesh versus patients without mesh. It is recommended that the safe method in laparoscopic hernia corrections with unintended contamination of the gastrointestinal tract, reproductive urology, or biliary tract is not to use artificial mesh at the same time as restoring organ damage, but instead to redesign fundamental hernia corrections within weeks [2].

On the other side, it has not been demonstrated that there is an increased risk of mesh contamination in the event of simultaneous operations performed on the digestive tract. Some authors report prosthetic repair of the abdominal wall after colonic resection with good results [6,7]. Many others perform prosthetic inguinal hernia repair in emergencies that require intestinal resection in cases of strangulated hernias [1]. It is also very common for laparoscopic surgeons to perform inguinal prosthetic hernia repair TAPP after performing a cholecystectomy [8].

Regarding TAPP surgery, there were some cases of bowel perforation and the timing of occurrence was different for all reported cases, but mesh site infection was not observed during follow up [9]. In our case, intra-abdominal contamination occurred only 3 days after surgery, but no signs of infection were observed during the follow up period for the patient, and there were no specific findings on the CT. Perhaps, through TAPP surgery, mounting the mesh in

the preperitoneal space, peritoneum isolates the peritoneal cavity from the mesh with less risk of contamination [10]. Contaminated or dirty surgery immediately after hernia mesh surgery could be safely performed.

References

1. Campanelli G, Nicolosi FM, Pettinari D, Avesani EC. Prosthetic repair, intestinal resection, and potentially contaminated areas: Safe and feasible? *Hernia*. 2004;8:190-92.
2. Choi JJ, Palaniappa NC, Dallas KB, Rudich TB, Colon MJ, Divino CM. Use of mesh during ventral hernia repair in clean-contaminated and contaminated cases: outcomes of 33,832 cases. *Ann Surg*. 2012;255:176-80.
3. Samee A, Adjepong S, Pattar J. Late onset mesh infection following laparoscopic inguinal hernia repair. *BMJ Case Rep*. 2011;2011.
4. Belyansky I, Tsirlina VB, Montero PN, Satishkumar R, Martin TR, Lincourt AE, et al. Lysostaphin-coated mesh prevents staphylococcal infection and significantly improves survival in a contaminated surgical field. *Am Surg*. 2011;77:1025-31.
5. Xourafas D, Lipsitz SR, Negro P, Ashley SW, Tavakkolizadeh A. Impact of mesh use on morbidity following ventral hernia repair with a simultaneous bowel resection. *Arch Surg*. 2010;145:739-44.
6. Mahon D, Decadt B, Rhodes M. Prospective randomized trial of laparoscopic (transabdominal preperitoneal) vs. open (mesh) repair for bilateral and recurrent inguinal hernia. *Surg Endosc*. 2003;17:1386-90.
7. Pans A, Plumacker A, Legrand M, Mohdad F, Dubois J, Meurisse M, et al. [Surgical treatment of incarcerated inguino-crural hernia with interposition of a preperitoneal prosthesis]. *Acta Chir Belg*. 1991;91:223-6.
8. Moon V, Chaudry GA, Choy C, Ferzli GS. Mesh infection in the era of laparoscopy. *J Laparoendosc Adv Surg Tech A*. 2004;14:349-52.
9. Birolini C, Utiyama EM, Rodrigues AJ, Jr., Birolini D. Elective colonic operation and prosthetic repair of incisional hernia: Does contamination contraindicate abdominal wall prosthesis use? *J Am Coll Surg*. 2000;191:366-72.
10. Wang L, Maejima T, Fukahori S, Nishihara S, Yoshikawa D, Kono T. Bowel obstruction and perforation secondary to barbed suture after minimally invasive inguinal hernia repair: Report of two cases and literature review. *Surg Case Rep*. 2021;7:161.