



# Bilioptysis with Hepatoiliobronchial Fistula: A Rare Hepatic Hydatidosis Complication

Juan Bellido Luque<sup>1\*</sup>, Alvaro Ramirez Redondo<sup>1</sup>, Inmaculada Sanchez-Matamoros<sup>1</sup>, Fernando Oliva Mompeán<sup>2</sup> and Angel Nogales Muñoz<sup>1</sup>

<sup>1</sup>Department of Hepatobiliopancreatic Surgery, Virgen de la Macarena, Spain

<sup>2</sup>Department of Gastrointestinal Surgery, Virgen de la Macarena, Spain

## Abstract

We present a case of a patient with hepatic hydatidosis who, after an episode of cholangitis, presented bilioptysis. A biliobronchial fistula and portal thrombosis were diagnosed, requiring surgical fistula resection and bile duct prostheses placement as well as a vena cava filter. After the procedure, the patient has not relapsed and continues with a vena cava filter due to his portal thrombosis.

**Keywords:** Biobronchial fistula; Hepatic hydatidosis; Bilioptysis; Right hepatectomy

## Introduction

The Biliobronchial Fistula (BBF) is a rare communication between the biliary tract and the bronchial tree [1]. The most frequent acquired causes are the rupture of hydatid cysts, hepatic abscesses, trauma or iatrogenesis, being the congenital ones extremely rare [2]. The prevalence estimated in a series of cases is 3.5% [3]. The most frequent symptomatology is bilioptysis, being or not accompanied by cough, fever, jaundice, abdominal and thoracic pain, nausea and vomiting [4,5].

Early diagnosis is important for further treatment due to difficult management. Magnetic resonance cholangiography and CT scan are useful in this pathology although the demonstration of bilirubin in sputum is a cost-effective measure as the first choice [1,6]. There are different treatments for biliobronchial fistula, being invasive procedures the last option in this type of patient [6].

## OPEN ACCESS

### \*Correspondence:

Juan Bellido Luque, Department of Hepatobiliopancreatic Surgery, Riotinto Hospital, Avda. la Esquila nº 6, Minas de Riotinto, 21660, Huelva, Spain, E-mail: j\_bellido\_l@hotmail.com

Received Date: 20 Aug 2018

Accepted Date: 21 Sep 2018

Published Date: 25 Sep 2018

### Citation:

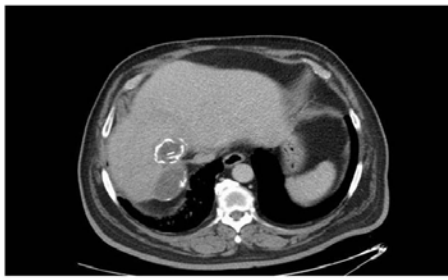
Luque JB, Redondo AR, Sanchez-Matamoros I, Mompeán FO, Muñoz AN. Bilioptysis with Hepatoiliobronchial Fistula: A Rare Hepatic Hydatidosis Complication. *Clin Surg*. 2018; 3: 2126.

**Copyright** © 2018 Juan Bellido Luque. This is an open access article distributed under the Creative Commons Attribution License, which permits unrestricted use, distribution, and reproduction in any medium, provided the original work is properly cited.

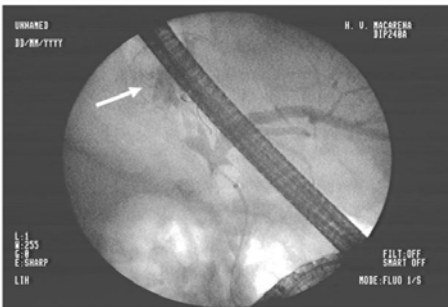
## Case Presentation

A 68-year-old man with history of type II diabetes mellitus, moderate renal insufficiency, hypertension and previous cholecystectomy, was admitted into Emergency Department due to episode of cholangitis caused by *streptococcus anginosus*. During admission in the digestive unit, complementary tests were performed, observing two 4.5 cm and 5.5 mm hydatid cysts in VIII and VII liver segments respectively, with aerobilia and portal thrombosis (Figure 1). An Endoscopic Cholangiopancreatography (ERCP) was performed and a communication with the biliary tract is visualized, proceeding to perform sphincterotomy and biliary lavage with good results (Figure 2). The cholangitis was solved and the patient was discharge after two weeks. The following year the patient was admitted again due to vomiting and fever with initial diagnosis of basal pneumonia due to right pulmonary mass, ruling out malignancy. In the CT scan performed during admission, Pulmonary Thromboembolism (PTE) was observed with a large thrombus in the right pulmonary artery. After anticoagulation, the PTE was solved but he kept presenting vomiting. A bilioptysis was suspected and sputum biochemistry was performed, finding a bilirubin of 2 mg/dl. The diagnosis of biliobronchial fistula was confirmed (Figure 3 and 4).

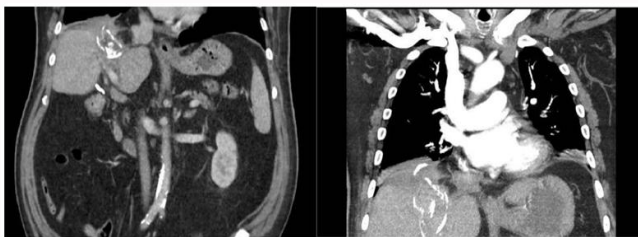
A scheduled surgery is proposed. The patient undergone to right hepatectomy with diaphragmatic gap closure and percutaneous drain placement as well as an inferior vena cava filter. During post-operative course, a persistent bile leak is shown through the drain, and ERCP was performed, identifying the leakage coming from the liver resection margin (Figure 5). The bile leak is solved with a plastic stent placement that was removed at 6 months (Figure 6). After the prosthesis removal, the patient presents episodes of deep venous thrombosis in both legs, so he continues with an inferior vena cava filter. Currently the patient remains with good general condition and favorable evolution after two years follow-up.



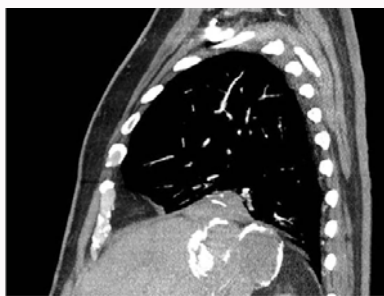**Figure 1:** CT scan. Two partially calcified hydatid cysts in VII and VIII segments.



**Figure 2:** Preoperative ERCP. Cyst-biliary communication. Hydatid cyst is filled with contrast (White arrow).



**Figure 3:** CT scan. Fistula hepato biliobronchial. Coronal view.

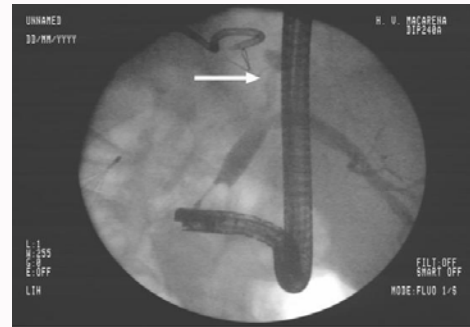


**Figure 4:** CT scan. Cyst-biliobronchial fistula. Sagittal view.

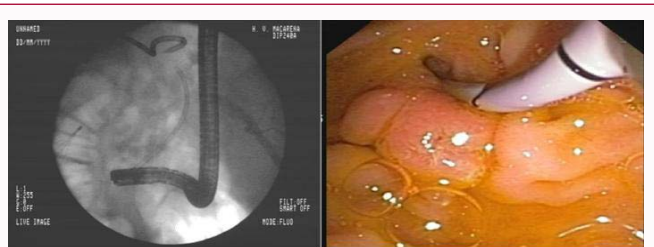
**Discussion**

Biliobronchial fistula is an infrequent pathology that arises as a complication, in our case, of a hydatid cyst that has been asymptomatic for years but is complicated by an episode of cholangitis.

The early diagnosis of this pathology is a fundamental pillar. The clinical diagnosis has vital importance, being the biliopytysis the pathognomonic symptom of this pathology as in the case of our patient. Sputum analysis helps to confirm the diagnosis to proceed to more effective targeted treatment.



**Figure 5:** Postoperative ERCP. Common and left hepatic ducts with contrast. Bile leak identification coming from hepatic resection (White arrow).



**Figure 6:** Postoperative ERCP. Plastic stent is placed in common bile duct to solve the bile leak.

Among the most frequent diagnostic imaging are CT scan and ERCP, both performed in our patient. The ERCP has high relevance in this patient due to the therapeutic attitude with the previous cholangitis and post-operative bile leak.

There isn't a gold standard in BBF treatment due to the few studies carried out and low evidence that is currently available. The treatment should be tailored according to each patient.

Among the non-surgical therapeutic options are the placement of metallic or plastic biliary stent and fistulous tract embolization. However, there is low experience with these methods and some experts recommend only the placement of endoprotheses as exclusive treatment in patients with low life expectancy.

Surgical invasive treatment should always be the last option but must be taken into consideration whenever necessary. In our case, right hepatectomy with diaphragmatic gap closure were performed to solve the thoracic transit. Therapeutic ERCP with biliary stent placement is useful in post-operative bile leak after hepatectomy.

**References**

- Nassar Y, Hida S, Richter S. A biliobronchial fistula in a patient with hepatocellular carcinoma treated with chemoembolization diagnosed by hepatobiliary iminodiacetic acid scan and managed by endoscopic retrograde cholangiopancreatography. *Gastroenterology Res.* 2017;10(6):383-5.
- Chautems R, Buhler LH, Gold B, Giostra E, Poletti P, Chilcott M, et al. Surgical management and long-term outcome of complicated liver hydatid cyst caused by *Echinococcus granulosus*. *Surgery.* 2005;137(3):312-6.
- Uchikov AP, Safev GP, Stefanov CS, Markova DM. Surgical treatment of bronchobiliary fistulas due to complicated echinococcosis of the liver: Case report and literature review. *Folia Med (Plovdiv).* 2005;45(4):22-4.
- Sahin E, Enon S, Cangir AK, Kutlay H, Kavukcu S, Akay H, et al. Single-stage transthoracic approach for right lung and liver hydatid disease. *J Thorac Cardiovasc Surg.* 2003;126(3):769-73.

5. Losada H, Vial M, Manterola C, Pienada V. Bronchobiliary fistula secondary to a hepatic hydatid cyst in transit to the thorax. Report of one case. *Rev. Chilena de Cirugía*. 2006;58:224-7.
6. Liao GQ, Wang H, Zhu GY, Zhu KB, Lv FX, Tai S. Management of acquired bronchobiliary fistula: A systematic literature review of 68 cases published in 30 years. *World J Gastroenterol*. 2011;17(33):3842-9.