



Bilateral Proptosis in Lymphoma

Banafsheh Ghavidel-Parsa^{1*} and Fatemeh Nejatifar²

¹Department of Rheumatology, Guilan University of Medical Sciences, Iran

²Department of Hematology and Oncology, Guilan University of Medical Sciences, Iran

Clinical Image

The case is 39-years old man who presented with 2 months history of bilateral proptosis and enlargement of lacrimal gland (Figure 1), weight loss (14 kg) and sweating. He was well before. On examination, small cervical lymph nodes and splenomegaly were detected. Computed Tomography (CT) of orbits revealed multiple conglomerate nodules in intraconal and extraconal compartments with compressive effect on the orbital components (Figure 2). Abdominal CT scan also showed splenomegaly and multiple paraaortic lymphadenopathies. Blood and serology test, including serum IgG4 level, were normal. An excisional biopsy from cervical lymph node showed small to medium sized atypical lymphocytes with a CD10+/CD20+/BCL2+/CD5-/Cyclin D1 pattern of immunostaining, consistent with grade 2 follicular lymphoma (Figure 3). Combination chemotherapy with (R-CHOP) resulted in complete response and resolution of symptoms after six cycle of treatment. Bilateral proptosis and lacrimal enlargement are rare initial manifestations of follicular lymphoma that should be considered in differential diagnosis.

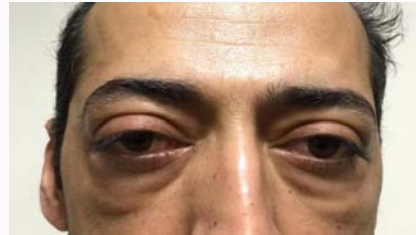

Figure 1: Bilateral proptosis and enlargement of lacrimal gland.

OPEN ACCESS

*Correspondence:

Banafsheh Ghavidel-Parsa,
Department of Rheumatology, Guilan
University of Medical Sciences, Rasht,
Iran,
E-mail: bghavidelparsa@gmail.com

Received Date: 26 Aug 2019

Accepted Date: 18 Sep 2019

Published Date: 23 Sep 2019

Citation:

Ghavidel-Parsa B, Nejatifar F. Bilateral
Proptosis in Lymphoma. *Clin Surg.*
2019; 4: 2587.

Copyright © 2019 Banafsheh
Ghavidel-Parsa. This is an open
access article distributed under the
Creative Commons Attribution License,
which permits unrestricted use,
distribution, and reproduction in any
medium, provided the original work is
properly cited.

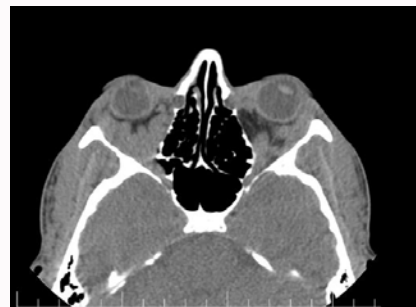

Figure 2: Compressive effect on the orbital components.

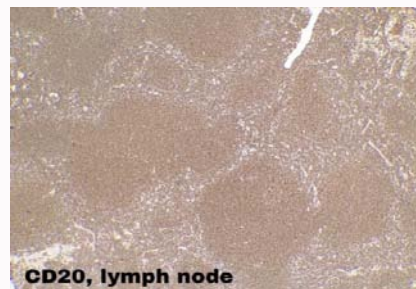


Figure 3: Consistent with grade 2 follicular lymphoma.