



Bilateral Ectopia Lentis in Marfan's Syndrome: a Case Report

Omolase CO^{1*}, Akinwalere AK¹, Omotayo RS¹, Omolase BO², Elekwachi G³ and Majekodunmi MY¹

¹Department of Ophthalmology, Federal Medical Centre, Nigeria

²Department of Radiology, Federal Medical Centre, Nigeria

³Department of Dental Services, Federal Medical Centre, Nigeria

Abstract

This report is of a twelve year old Nigerian girl who presented to the Eye clinic of Federal Medical Centre, Owo, and Ondo State, Nigeria in March, 2010 on account of poor vision of five years duration. Examination of the patient revealed features which were in keeping with Marfan's syndrome and bilateral ectopia lentis. The patient was refracted and recommended glasses which improved her vision were prescribed. The patient was also referred to the cardiologist for further evaluation and management. Multi disciplinary approach should be adopted in the management of Marfan's syndrome so as to prevent complications most especially life threatening ones.

Keywords: Marfan's Syndrome; Ectopia Lentis; Nigeria

Introduction

Marfan's syndrome is a genetic disorder of the connective tissue. It is an autosomal dominant disorder involving the cardiovascular, skeletal and ocular systems [1]. The skin, integument, lung, muscle, adipose tissue and dura can also be affected [2,3]. Marfan's syndrome was first described by Antonie-Bernard Marfan in an 1896 case report of a young girl with unusual musculoskeletal features [3]. It has been reported to occur in 8 to 10 per 100,000 populations per year [4]. In 1991 the fibrillin-1(FBN 1) gene mutation on chromosome 15 was identified as a cause of Marfan's syndrome [5]. Fibrillin, a glycoprotein provides force bearing structural support and elasticity of the ocular connective tissues [5]. It is found in multiple structures in the eye and plays integral role in maintaining the integrity of the healthy eye [6]. The ophthalmic features of Marfan's syndrome were first described in 1914 by Boerger a Peadiatrician [7].

There are no unique signs or symptoms of Marfan's syndrome, the constellation of long limbs, dislocated lenses and aortic root dilation is a pointer to making the diagnosis. There are more than thirty other clinical features that are variably associated with the syndrome, most involving the skeleton, skin and joints. There is a great deal of clinical variability even within families that carry the identical mutation. Many individuals with Marfan's syndrome grow to above average height. Some have long limbs with long fingers and toes (arachnodactyly). This condition of elongated limbs is known as dolichostenomelia. An individual's arms may be disproportionately long with thin weak wrists. In addition to affecting height and limb proportions, it can present with other skeletal abnormalities like scoliosis, pectus exarvatum and pectus carinatum.

The main ocular features of Marfan syndrome all of which can result in poor vision include bilateral ectopia lentis, myopia and retinal detachment [8]. About half of patients with Marfan's syndrome are diagnosed by an Ophthalmologist; some individuals may present with ocular signs suggestive of this syndrome [9]. In view of the importance of the ocular signs of Marfan's syndrome, we decided to report the case of a twelve year old Nigerian girl with Marfan's syndrome who presented with biltateral ectopia lentis. The authors are aware of few reports of similar presentation in Nigeria.

Case Presentation

AO, a twelve year old Nigerian girl was brought by her mother on the 8th of March, 2010 on account of poor vision of five years duration. The attention of the parents was drawn to the poor vision by one of her school teachers. The late presentation was attributed to financial constraint.

OPEN ACCESS

*Correspondence:

Omolase CO, Department of Ophthalmology, Federal Medical Centre, Nigeria,
E-mail: omolash2000@yahoo.com

Received Date: 06 Nov 2018

Accepted Date: 30 Nov 2018

Published Date: 05 Dec 2018

Citation:

Omolase CO, Akinwalere AK, Omotayo RS, Omolase BO, Elekwachi G, Majekodunmi MY. Bilateral Ectopia Lentis in Marfan's Syndrome: a Case Report. *Clin Surg*. 2018; 3: 2244.

Copyright © 2018 Omolase CO. This is an open access article distributed under the Creative Commons Attribution License, which permits unrestricted use, distribution, and reproduction in any medium, provided the original work is properly cited.

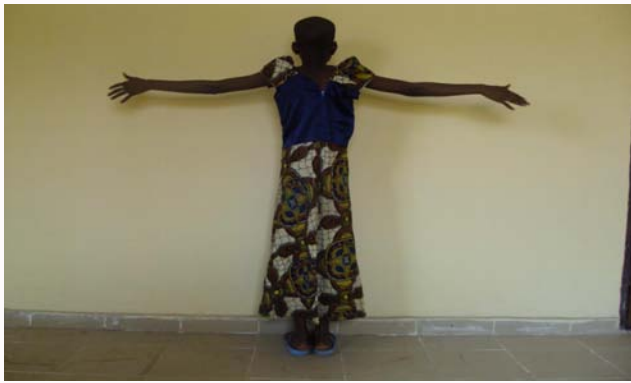

Figure 1: Full view of the patient.

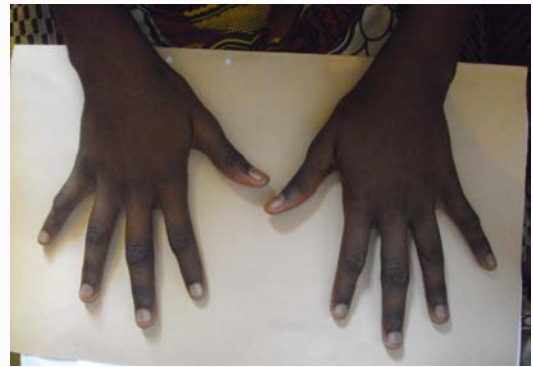

Figure 3: Arachnodactyly (Long Fingers).

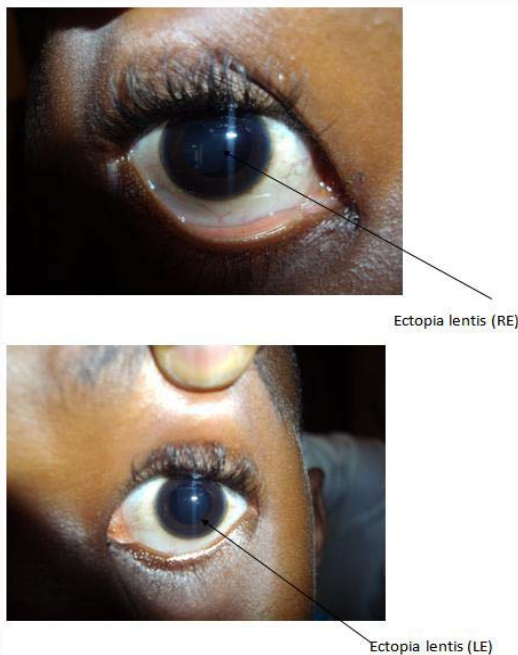


Figure 2: Bilateral ectopia lentis (RE & LE).

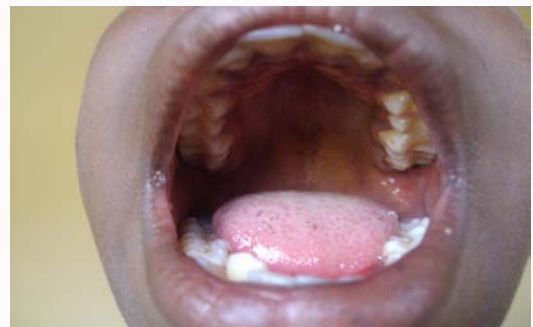

Figure 4: High arched palate.

There is no history of easy fatiguability or breathlessness. She is a product of normal spontaneous vertex delivery. The developmental history was apparently normal. Her intelligence and behaviour were normal. The child is the first born in a monogamous family of two. The father is a welder while the mother is a petty trader. There is no similar occurrence in her family.

Physical examination revealed a tall and thin patient with long extremities as well as elongated face. The patient also had high arched palate, long fingers (arachnodactyly) and fairly long toes. The height of the patient was 1.43 m while the arms' length was 1.48 m.

The examination of the cardiovascular system revealed left parasternal heave, heart sound S1 and S2 with loud P2. The chest was clear and no abnormality was detected in the abdomen. The CNS was grossly intact.

Ocular examination revealed a visual acuity of 6/60 in the right eye which improved to 6/36 with pin hole and a visual acuity of 6/36 in the left eye which improved to 6/24 with pin hole. The anterior segments were quiet in both eyes. The pupils were briskly reactive. The view of the fundus was poor prior to dilation. Further examination

post-dilation of both pupils revealed supero-temporal displacement of the clear crystalline lens of both eyes. Dilated fundus copy revealed flat retina and pink optic disc with cup disc ratio of 0.3 in both eyes. An attempt at carrying out cycloplegic refraction was not successful as the reflexes were very poor. A subjective refraction was done and the patient accepted -2DS in both eyes with a visual acuity of 6/18. The recommended glasses were dispensed and patient was encouraged to utilize it. The patient is to come for periodic ocular review every three months. In view of the findings in the cardiovascular system the patient was referred to the cardiologist for further evaluation and management.

Discussion

Ectopia lentis is a displacement or malposition of the crystalline lens of the eye from its normal position [10]. A partial displacement of the lens is called sub-luxation while a complete displacement of the lens is called luxation.

Ectopia lentis is potentially visually debilitating but visual acuity varies with the degree of mal position of the lens.

The presence of ectopia lentis is a major criterion for the diagnosis of Marfan's syndrome which unequivocally establishes the diagnosis of Marfan's syndrome in 86% of cases [11]. Marfan's syndrome is the most frequent cause of inherited ectopia lentis [12]. The most common ocular abnormality of Marfan's syndrome is ectopia lentis occurring in 50% to 80% of affected individuals [13].

Common non-surgical interventions in ectopia lentis include refractive aid and pharmacological manipulation of the pupil. Indications for lens extraction include lens opacity with poor visual function, anisometropia, refractive error not amenable to optical correction, impending luxation and lens-induced glaucoma or uveitis

[12,14].

In the case highlighted above, the presenting complaint of poor vision was related to the bilateral ectopia lentis. In cases of Marfan's syndrome, it is difficult to detect any displacement of the lens in the presence of poor pupillary dilatation even after instillation of atropine eye drop [15]. There is often amblyopia even with a lens of normal transparency and it is caused by optical changes due to the fact that the equator of the lens occupies the optical centre of the lens [15]. The problem of ectopia lentis is difficult to manage especially in children.

We decided to temporise on the issue of surgical intervention in this case in view of the fact that patient's vision improved with recommended glasses coupled with the fact that the lens in both eyes were clear. There are few reports of cases of Marfan's syndrome with ectopia lentis from this part of the world in the literature. Ekure et al. reported three cases of Marfan's syndrome in a Nigerian nuclear family [16]. Ugwu et al. presented a case of Marfan's syndrome with abdominal aortic aneurysm who had bilateral ectopia lentis in Jos, et al. [17].

Two sisters with established Marfan's syndrome who had bilateral posterior lens dislocation, total rhegmatogenous retinal detachment and secondary glaucoma have been reported by Mema et al. in Albania, USA [18].

The importance of evaluation of the cardiac status of a patient with Marfan's syndrome cannot be overemphasized. This fact explains the rationale behind our decision to send the patient to a cardiologist for further evaluation and management. The need to prevent ocular complication is the justification for our plan to review the patient periodically. The other sibling of the patient and her mother were also examined to rule out other cases of Marfan's syndrome in the family.

Conclusion

Even though this patient presented very late, the case has brought into focus the important role of Ophthalmologists in the management of patients with Marfan's syndrome. There is need to effectively manage the ocular features of Marfan's syndrome so as to prevent amblyopia and loss of vision. There should be a multidisciplinary approach to the management of Marfan's syndrome so as to prevent life threatening situations that can arise.

Acknowledgement

The contribution of the other health workers to this work is hereby acknowledged. We are also grateful to the parents of this patient for their cooperation.

References

1. Stankovic Babic G, Vujanovic M, Dordevic-Jocic J, Cekic S. Ocular features of Marfan's syndrome. *Medicine and Biology*. 2008;15(1):37-40.
2. Ades L. Members of the CSANZ Cardiovascular Genetics Working Group. Guidelines for the Diagnosis and Management of Marfan's syndrome. *Heart Lung Circ*. 2007;16(1):28-30.
3. Ramirez F, Dietz HC. Marfan's syndrome: from molecular pathogenesis to clinical treatment. *Curr Opin Genet Dev*. 2007;17(3):1-7.
4. Harrison's Principles of Internal Medicine. 15th edn. The McGraw-Hill Companies, Inc. New York. 2001:351-5.
5. Nahum Y, Spierer A. Ocular features of Marfan's syndrome: Diagnosis and Management. *Isr Med Assoc J*. 2008;10(3):179-81.
6. Lee SY, Ang CL. Results of retinal detachment surgery in Marfan's syndrome in Asians. *Retina*. 2003;23(1):24-9.
7. Boerger F. Ueber zwei Faelle von Arachnodyctylie. *Z Kindeheilkd*. 1914;12:161-184.
8. Dean JCS, Brashaw NE, Haites NE. The Scottish Clinical Guidelines and Integrated Care Pathways for Marfan syndrome. *Genisys*. 2003.
9. Nemet AY, Assia EI, Apple DJ, Barequet IS. Current concepts of ocular manifestations in Marfan syndrome. *Surv Ophthalmol*. 2006;51(6):561-75.
10. Trivedi HL, Venkatesh R. Ectopia lentis: Weill Marchesani Syndrome. *Bombay Hospital Journal* 2009;51(1):49-54.
11. Dean JC. Marfan's syndrome: Clinical Diagnosis and Management. *Eur J Hum Genet*. 2007;15(7):724-33.
12. Eifrig CW, Eifrig DE. Ectopia lentis. *E Medicine website*.
13. Rubin SE, Nelson LB. Ocular manifestations of autosomal dominant systemic conditions. *Duane's Clinical Ophthalmology on CD -Rom*. Philadelphia: Lippincott Williams and Wilkins. 2006;3(58).
14. Anteby I, Isaac M, BenEzra D. Hereditary sub-luxated lenses: visual performances and long term follow-up after surgery. *Ophthalmology*. 2003;110(7):1344-8.
15. Zaidi ZH. Bilateral ectopia lentis in Marfan's syndrome: Review of features with report of two cases. *Can Med Assoc J*. 1960;82(5):265-8.
16. Ekure EN, Onakoya AO, Oke DA. Marfan's syndrome: a study of a Nigerian family and review of current cardiovascular management. *West Afr J Med*. 2009;28(1):48-53.
17. Ugwu BT, Ardill W, Yiltok SJ, Momoh JT, Lenkop DW, Uba FA. Marfan's syndrome presenting with abdominal aortic aneurysm: a case for vigilance. *West Afr J Med*. 2003;22(1):95-7.
18. Mema V, Qafa N. Ocular complications of Marfan's syndrome. Report of two cases. *Hippokratia*. 2010;14(1):45-7.