



## Axillary Tail Breast Cancer: Report of Two Cases and Review of the Literature

Maha Abdel Hadi\*, Eiman Shammari, Sarah Al Sinan, Rahma Shahbahai, Khadija AL Khwaja, Roa Al Gowejez and Arwa Al Nabhan

Department of Breast Surgery, Breast Imaging and Oncology, Imam Abdulrahman Bin Faisal University, KSA

### Abstract

Axillary Breast cancer is a rare entity accounting for 0.1% to 2% of all breast cancer cases. It is typically composed of poorly differentiated IDC with occasionally areas of squamous or mesenchymal carcinoma. Axillary malignancy is challenging as there are many differential diagnoses that may require careful evaluation process. The reported differential diagnoses are occult breast carcinoma, accessory breast cancer, axillary tail breast cancer, and lymphoma or non-breast metastatic lymphadenopathy. We report two cases with similar clinical and histological presentations despite the age difference. Standard radiological and histopathological evaluations were employed to reach the diagnosis of IDC of the axillary tail.

**Keywords:** Axillary tail; Invasive ductal carcinoma; Breast cancer

### Case Presentation

#### Case 1

A 28 years old female presented with enlarging left axillary swelling noticed 3 months post-partum of her first pregnancy. She was reassured for 9 months attributing it to lactational changes. There was associated progressive pain and limitation of movement of the left shoulder. Menarche at age 14 with regular menstruation and pregnancy with no associated co-morbidities. General examination was unremarkable. Local examination revealed bilateral nodular breasts with no palpable masses. There was a palpable left axillary firm, limited mobility 3 cm × 4 cm mass with no associated tenderness or skin changes. Ultrasound and mammogram revealed normal bilateral breasts with an axillary tail mass extending to the left axilla with multiple matted axillary nodes on imaging. CT scan confirmed the findings. Core biopsy of the lesion revealed Invasive Ductal Carcinoma (IDC) Patient underwent Excision of Axillary tail with axillary node dissection sparing the breast followed by adjuvant chemo- radiotherapy regimens.

#### Case 2

A 69 years old single female, a Known case of schizophrenia and bronchial asthma and both controlled on medication. She presented with a large left axillary mass of one-year duration with progressive increase in size. There was associated hyperpigmentation of the overlying skin otherwise no associated pain or discharge. Menarche at age of 12 year and menopause at age of 50 year. There was no history of hormonal replacement therapy. General examination: obese, anxious female otherwise the examination was unremarkable Local examination: revealed bilateral symmetrical large breasts. The right breast was unremarkable. Left breast: Normal anterior aspect and nipple. There appeared a large breast tail 6 cm × 7 cm firm, non-tender fixed mass, associated with thick purple colored skin with peau d' orange Figure 1. Ultrasound showed a large heterogeneously hypoechoic highly vascular left axillary mass measuring approximately about 10 cm × 5.0 cm with cystic changes and thickened skin. Highly suggestive of malignancy Figure 2. Mammogram was a limited study due to technical reasons demonstrating a Part of the axillary mass with fat stranding and skin thickening Figure 3. Contrast enhanced CT scan both axial and sagittal views of the chest, abdomen and pelvis showing left axillary tail/axilla demonstrated a large irregular heterogeneously enhancing mass with central necrosis measuring 10 cm × 7.7 cm × 10 cm at anteroposterior, transverse and craniocaudal diameters respectively attached to the skin with skin invasion. The mass appeared separable from the breast tissue with fat stranding and subcutaneous edema. Multiple Matted ipsilateral axillary lymph nodes with central necrosis were also noted Figure 4. Using Standard imaging and histopathology performed in both cases aided in the diagnosis of IDC. Considered differential diagnoses in both cases included lymphoma and adnexal skin tumors.

### OPEN ACCESS

#### \*Correspondence:

Maha Abdel Hadi, Department of Breast Surgery, King Fahd Hospital of the University, P.O. Box: 40293 Al-Khobar 31952, Kingdom of Saudi Arabia, Tel: 00966505843710;

E-mail: mhadi@uod.edu.sa

Received Date: 25 Feb 2019

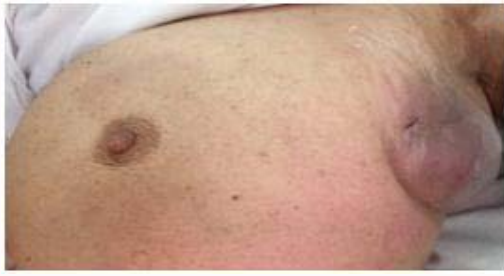Accepted Date: 15 Mar 2019

Published Date: 20 Mar 2019

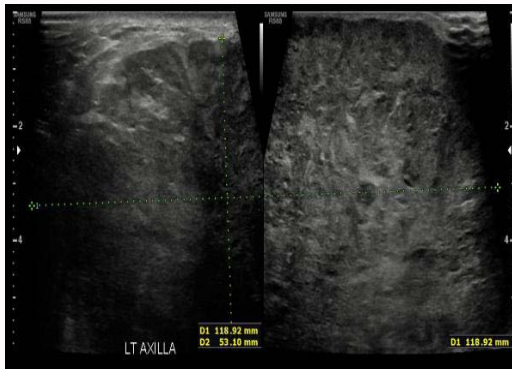#### Citation:

Hadi MA, Shammari E, Al Sinan S, Shahbahai R, Al Khwaja K, Al Gowejez R, et al. Axillary Tail Breast Cancer: Report of Two Cases and Review of the Literature. *Clin Surg*. 2019; 4: 2375.

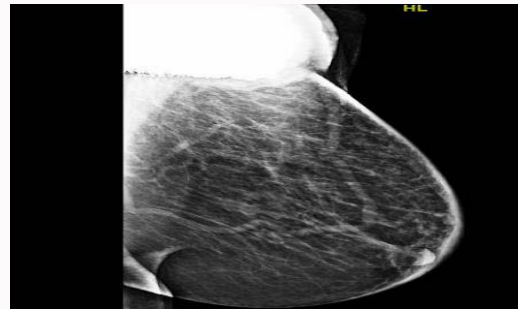
**Copyright** © 2019 Maha Abdel Hadi. This is an open access article distributed under the Creative Commons Attribution License, which permits unrestricted use, distribution, and reproduction in any medium, provided the original work is properly cited.



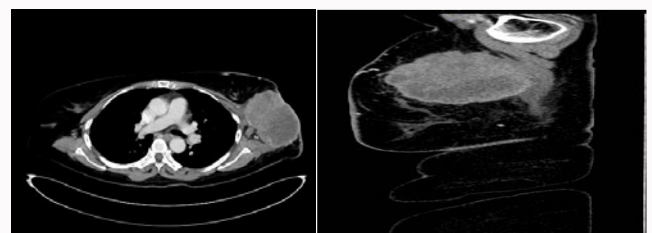
**Figure 1:** Demonstrates the hyperpigmented edematous axillary mass.



**Figure 2:** Ultrasound showed a specious large heterogeneously hypoechoic highly axillary mass with cystic changes and thickened skin.



**Figure 3:** Mammogram demonstrating unremarkable breast with hyperdense partially visualized mass seen at the left axillary tail, associated with increased trabeculation and marked skin thickening.



**Figure 4:** Axial and Sagittal contrast enhanced CT scan of the chest demonstrating the large axillary tail lesion with matted axillary lymph nodes.

## Discussion

Due to the rare occurrence of the carcinoma of the axillary tail it remains an under-recognized entity [1,2]. It possesses atypical clinical, pathological and prognostic features, promoting the likelihood of nodal metastasis which impacts negatively on both disease progression and survival [3]. Patients usually discover the mass on self-examination and seek medical advice. The standard investigations with ultrasound and mammography are useful modalities yet to anatomical nature of the axillae some limitations are encountered. More sophisticated modalities such as MRI and PET-CT provide accurate delineation facilitating the diagnosis especially in challenging cases [4,5]. IDC is the commonest histological diagnosis especially in malignancies arising from the ectopic breast tissue. Occasionally the diagnosis maybe challenging as other diagnoses such as adnexal skin carcinomas may be difficult to differentiate [6]. The treatment is straight forward with no dispute regarding the axillary dissection. However, mastectomy versus Wide Local Excision (WLE) still remains. Despite the fact that recommendations of mastectomy still remain, the majority feel that WLE may be adequate [7,8].

## Conclusion

Axillary tail breast cancer is rare and challenging entity that may need special attention in clinical, imaging and pathological practice.

## References

1. Ampil F, Caldito G, Henderson B, Li B, Kim RH, Burton G, et al. Carcinoma of the axillary tail of Spence: a case series. *Anticancer Res.* 2012;32(9):4057-9.
2. Myint ZW, Raparla S, Kamugisha LK. Metaplastic breast cancer with chondroid differentiation. *J Community Hosp Intern Med Perspect.* 2015;5(4):28935.
3. Gou ZC, Liu XY, Xiao Y. Decreased survival in patients with carcinoma of axillary tail versus upper outer quadrant breast cancers: A SEER population-based study. *Cancer Manag Res.* 2018;10:1133-1141.
4. Okubo M, Tada K, Niwa T, Nishioka K, Tsuji E, Ogawa T, et al. A case of breast cancer in the axillary tail of Spence – enhanced magnetic resonance imaging and positron emission tomography for diagnostic differentiation and preoperative treatment decision. *World J Surg Oncol.* 2013;11:217.
5. Capobianco G, Spaliviero B, Dessole S, Rocca PC, Cherchi PL, Ambrosini G, et al. Lymph node axillary metastasis from occult contralateral infiltrating lobular carcinoma arising in accessory breast: MRI diagnosis. *Breast J.* 2007;13(3):305-7.
6. Amsler E, Sigal-Zafrani B, Marinho E, Aractingi S. [Ectopic breast cancer of the axilla]. *Ann Dermatol Venereol.* 2002;129(12):1389-91.
7. Tjalma WA, Senten LL. The management of ectopic breast cancer--case report. *Eur J Gynaecol Oncol.* 2006;27(4):414-6.
8. Marshall MB, Moynihan JJ, Frost A, Evans SR. Ectopic breast cancer: case report and literature review. *Surg Oncol.* 1994;3(5):295-304.