



Avascular Necrosis as a Sequelae of Tuberculosis of Hip

Jani C^{1*}, Kale A¹, Desouza C¹, Gulati S², Pareek R¹ and Khan U¹

¹Dr. DY Patil Medical Hospital and Research Centre, India

²JJM Medical College, Medical College Road, India

Abstract

Introduction: The occurrence of tuberculosis of Hip joint is next to that of tuberculosis of spine and constitutes 15% of all cases of osteoarticular Tuberculosis. If the hip joint is left untreated after been diagnosed, it can lead to continuous demolition of the joint which may lead up to pathological destruction. Tuberculosis, caused by Mycobacterium tuberculosis, is a common infectious disease in the developing countries. Osteoarticular TB occurs secondary to primary pathology in lungs, lymph nodes or any of the viscera. The bacteria reach either the synovium or the bone tissue *via* hematogenous route. The granulated tissue from the synovium extends over the bone tissue leading to the necrosis of the subchondral bone, sequestra and may be kissing lesion on either side of the joint. In the early stages of TB hip, plain radiographs are unrevealing so, by the time radiological changes are visible on a plain radiograph, the disease has moderately advanced. Variation in the clinical and radiological representation may imitate common osseous and articular conditions seen in children which in turn delay the diagnosis. TB of Hip joint has been rarely reported in the recent literature. In recent times, modern diagnostic procedures such as USG, MRI of hip joint, USG guided aspiration of the synovial fluid, obtaining the material for PCR and tissue diagnosis are incorporated.

Case Report: This case report discusses 14 year old Female with complaints of Right hip pain which was later diagnosed to be tuberculosis of the hip. When she came for further evaluation she was diagnosed with AVN of the same hip with the help of imaging studies.

Conclusion: We conclude from the case reported that although very rare, Tuberculosis of the hip, although a common sequelae in adults, can result into avascular necrosis of the hip even in the pediatric/adolescent age group.

Introduction

Tuberculosis of Hip joint accounts for 15% to 20% of the musculoskeletal system. The occurrence of tuberculosis of hip joint is next to that of tuberculosis of spine and constitutes 15% of all cases of osteoarticular Tuberculosis where, osteoarticular manifestation can be either intra-articular type or an extra-articular one [1]. If the hip joint is left untreated after been diagnosed can lead to continuous demolition of the joint which may lead up to pathological destruction [2]. Tuberculosis, caused by Mycobacterium tuberculosis, is a common infectious disease in the developing countries. Osteoarticular TB occurs secondary to primary pathology in lungs, lymph nodes or any of the viscera. The bacteria reach either the synovium or the bone tissue *via* hematogenous route. When it enters first in synovium, the synovial membrane becomes swollen and congested. The granulated tissue from the synovium extends over the bone tissue leading to the necrosis of the subchondral bone, sequestra and may be kissing lesion on either side of the joint [3]. The bacteria may also first enter in the epiphyseal or metaphyseal area of the adjoining bones like head, neck of femur, greater trochanter or acetabulum to begin the destructive process. It may start as extra-articular or juxta-articular lesion. When the infection starts as intra-articular, it progresses fast and tends to involve the entire joint area [4]. In the early stages of TB hip, plain radiographs are unrevealing so, many cases present in the advanced stages of the disease due to delay in diagnostic procedures. By the time radiological changes are visible on a plain radiograph, the disease has moderately advanced [4]. Variation in the clinical and radiological representation may imitate common osseous and articular conditions seen in children which in turn delay the diagnosis [1]. TB of Hip joint has been rarely reported in the recent literature. In recent times, modern diagnostic procedures such as USG, MRI of hip joint, USG guided aspiration of the synovial fluid, obtaining the material for PCR and tissue diagnosis are incorporated [5].

Case Presentation

A 14 year old female came to the Orthopedics OPD with complaints of pain in the right hip

OPEN ACCESS

*Correspondence:

Chiranjivi Jani, Dr. DY Patil Medical Hospital and Research Centre, India,
E-mail: jani.chiranjeev@gmail.com

Received Date: 21 Apr 2021

Accepted Date: 20 May 2021

Published Date: 26 May 2021

Citation:

Jani C, Kale A, Desouza C, Gulati S, Pareek R, Khan U. Avascular Necrosis as a Sequelae of Tuberculosis of Hip. *Clin Surg*. 2021; 6: 3187.

Copyright © 2021 Jani C. This is an open access article distributed under the Creative Commons Attribution License, which permits unrestricted use, distribution, and reproduction in any medium, provided the original work is properly cited.

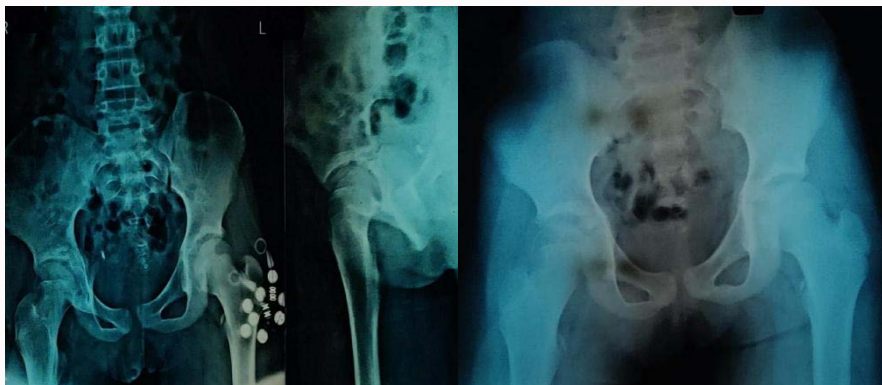

Figure 1: An AP and lateral view of pelvis both hips showing reduced joint space and sclerosing acetabulum and femoral head.

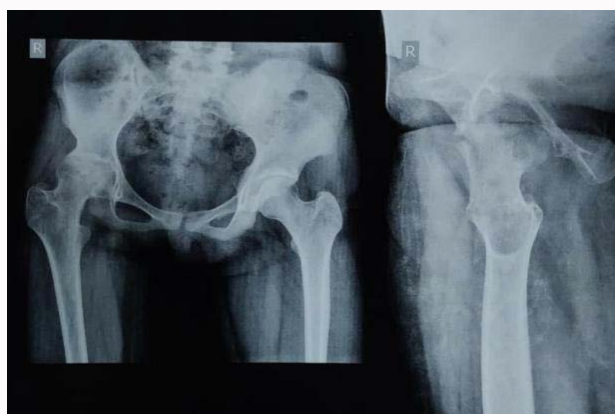

Figure 2: AP and lateral X-ray views of pelvis both hips showing significant joint space narrowing of the right hip and sclerosing acetabulum and femoral head and subchondral cyst.

since six months. The pain intensity was 6/10 on VAS scale. The pain aggravated on walking, partially relieved on rest and analgesics. The patient's complaints were also associated with weight loss, night sweats, and an evening rise in temperature. She had a previous consultation for the same elsewhere and was started on first line anti-tuberculosis treatment. She discontinued the treatment after a course of two months without been advised to do so. On admission, a hip aspiration was performed for the right hip following the X-rays (pelvic-both hips) and was sent for culture-sensitivity, gram staining & RT-PCR for Tuberculosis. Reports revealed Tuberculosis of Right Hip and she was again started on anti-tuberculosis treatment in 2019. Currently she came in again complaining of pain in the right hip which was associated a Trendelenburg gait with reduced stance phase on the affected limb. The range of motion of the right hip was reduced with flexion, and coronal and rotatory movements reduced. There was also a true shortening of the affected limb by about 1 cm. Again, an X-ray was advised following which, this time an MRI (Pelvis both hips) was done, which revealed avascular necrosis of the right Hip.

Discussion

Avascular necrosis of the femoral head is an enfeebling disease that usually leads to demolition of the hip joint in the patients who are in their third, fourth, fifth decade of life. The prevalence remains unknown. The etiological factors and pathogenesis are not completely understood. Furthermore, reports of methods of treatment often based on small numbers of patients with different etiologies, stages of disease progression, varying amount of involvement of femoral

head [6]. A number of risk factors have been identified in previous studies leading to avascular necrosis including excessive alcohol intake, corticosteroid therapy and bony injuries in and around femoral neck [6]. Systemic causes include malignancy, systemic lupus erythematosus, sickle cell Anemia, Gaucher's disease, gout, caissons disease, vasculitis, osteoarthritis, osteoporosis, chemotherapy, renal transplant etc. A rare association with infection such as HIV, meningococemia was reported [7]. There are multiple theories about the pathogenesis of avascular necrosis of femoral head leading to one final common pathway, which is reduction of blood flow to the femoral head that ultimately leads to ischemia and bone death. This occurs as a consequence of extravasation of blood from the damaged blood vessels, and with fat and cellular elements, can cause extrinsic compression of other viable vasculature in the marrow cavity [8]. At first, if there are sufficient collaterals, the bone cells remain viable. Once the ischemic threshold is reached, the affected bone undergoes morphological changes of bone death despite the inciting event [8]. The diagnosis is generally made by history and high index of suspicion since many patient initially do not present with any symptoms. By the time clinical symptoms arise, the disease is already in advanced stage with the patient presenting with pain in the hip joint. When diagnosis is suspected clinically, it can be confirmed by radiologic imaging studies. Conventional X-rays are inadequate in establishing the diagnosis because in early stages of osteonecrosis, they may be completely normal. The earliest radiographic sign of osteonecrosis is the presence of a crescent on the contour of the femoral head. This is the result of structural collapse of a necrotic segment of a subchondral

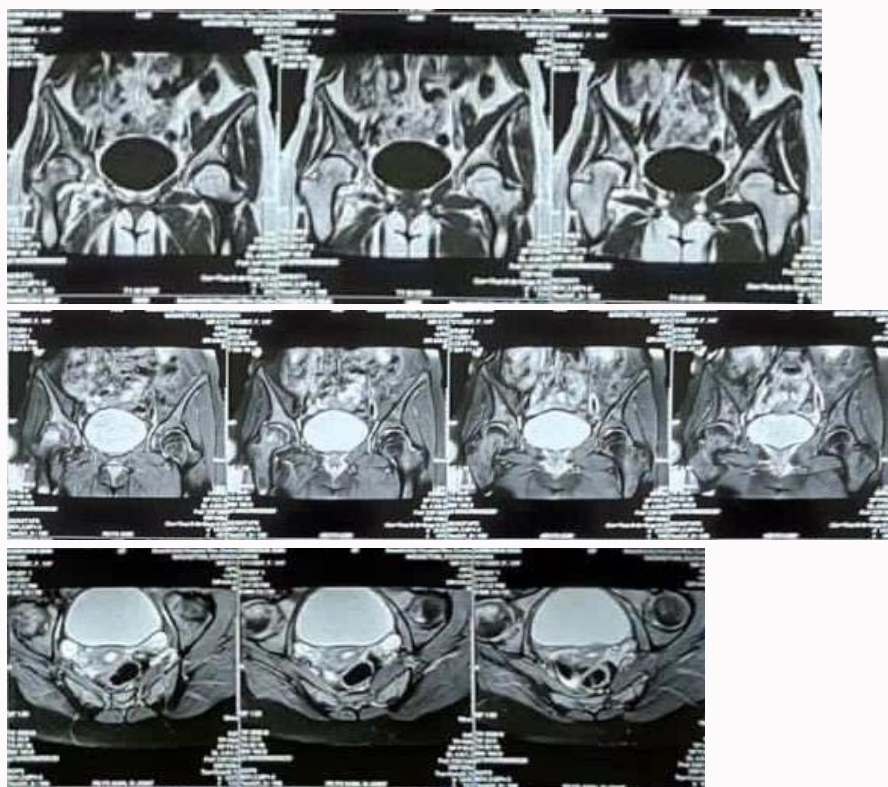


Figure 3: Coronal and Axial MRI images of the patient showing of ill-defined erosions in the right head of femora with moderate perilesional collection over the right hip.

bone. At this stage, the disease is already irreversible. Magnetic Resonance Imaging (MRI) is the “Gold Standard” for the imaging of osteonecrosis [9]. In our patient, X-ray changes characteristic of osteonecrosis were already evident as depicted by the presence of subchondral collapse of the femoral head of the right hip with joint space narrowing. The MRI OF PBH Joints done in the year 2018 revealed -right mild hip joint effusion noted with mild synovial thickening whereas, the MRI of both hip joints done recently showed ill-defined erosions in the right head of femora with moderate perilesional collection on right side suggestive of avascular necrosis of the right femoral head. Most cases of AVN ultimately require surgical intervention. In our patient, she was advised core-decompression and possible joint replacement. However, we opted for treatment with continuation of Anti tubercular drugs along with analgesics. Our clinical case represents avascular necrosis of the femoral head following tuberculosis as an etiological factor causing osteonecrosis of the right hip joint. This has been mentioned in rare case reports in the past. Two cases of AVN of femoral capital epiphysis following intertrochanteric tubercular osteomyelitis have been reported. There is a recent report mentioning association of AVN in a HIV positive patient with polyarticular tuberculosis. However osteonecrosis with TB as the etiological factor has only been mentioned in one case with avascular necrosis of humeral head caused by mycobacterium tuberculosis. To the best of our knowledge, the present case is the first report documenting an association of avascular necrosis of femoral head as a sequelae of tuberculosis of hip joint.

Conclusion

We conclude from the case reported that although very rare, tuberculosis of the hip can result into avascular necrosis of the hip

even in the pediatric/adolescent age group, as there is literature supporting a similar complication following tuberculosis infection in adults, but we see that avascular necrosis can even occur in pediatric age group following a tuberculosis infection of the involved hip.

References

1. Mohideen MA, Rasool MN. Tuberculosis of the hip joint region in children. SA Orthopedic Journal. 2013;12(1):38-43.
2. Moon MS, Kim SS, Lee SR, Moon YW, Moon JL, Moon SI. Tuberculosis of hip in children: A retrospective analysis. Indian J Orthop. 2012;46(2):191-9.
3. Tuli SM. General principles of osteoarticular tuberculosis. Clin Orthop Relat Res. 2002;398:11-9.
4. Saraf SK, Tuli SM. Tuberculosis of hip: A current concept review. Indian J Orthop. 2015;49(1):1-9.
5. Yao DC, Sartoris DJ. Musculoskeletal tuberculosis. Radiol Clin N Am. 1995;33(4):679-89.
6. Mont MA, Jones LC, Hungerford DS. Nontraumatic osteonecrosis of the femoral head: Ten years later. J Bone Joint Surg Am. 2006;88(5):1117-32.
7. Assouline-Dayan Y, Chang C, Greenspan A, Shoenfeld Y, Gershwin ME. Pathogenesis and natural history of osteonecrosis. Semin Arthritis Rheum. 2002;32(2):94-124.
8. Tee KD, Magbitang AT, Tee ML. Challenges in the management of concomitant TB arthritis and AVN in a lupus patient with adverse drug reaction to Anti-Koch's medications. Phillipine J Internal Med. 2014;52(4):1-4.
9. Chang C, Greenspan A, Gershwin ME. Osteonecrosis. Firestein GS, Budd RC, editors. Kelley's Textbook of rheumatology 9th Ed. Elsevier Saunders; 2013;1692-709.