



Application of Extensor Cuff for Pre-Treatment of Abdominal Aortic Aneurysm with Chronic Dissection of Proximal Neck

Yung-Szu Wu and Chung-Lin Tsai*

Department of Cardiovascular Surgery, Veterans General Hospital, 1650 Taiwan Boulevard Sect. 4, Taichung 40705, Taiwan

Abstract

Chronic aortic dissection involving the neck of an abdominal aortic aneurysm is rare. The application of endovascular surgery in the treatment of an aneurysm with neck dissection has rarely been reported. We report two cases with abdominal aortic aneurysm and a history of chronic type B aortic dissection who could not tolerate conventional surgery. The dissection flap in the neck of the aneurysm was unhealthy and thus unsuitable as a landing zone. Extensor cuff is used to augment the true lumen of a dissecting proximal neck of abdominal aortic aneurysm before implantation of a bifurcated trunk device. The radial force of the extensor cuff augments the adhesion of the dissection flap to the aortic wall. The post-operative angiography showed no type I endoleak or migration of stent-graft. The 6-month follow-up was uneventful and no re-intervention was required. The use of an extensor cuff for pre-treatment of an abdominal aortic aneurysm with chronic dissection of the neck may provide an alternative treatment method for selected patients.

Keywords: Abdominal aortic aneurysm; Aneurysm; Dissection; Endovascular therapy; Endovascular aneurysm repair

Introduction

Endovascular aortic repair (EVAR) is now more commonly performed for elective treatment of abdominal aortic aneurysm (AAA) than the open repair approach [1]. However, endovascular treatment is not suitable for cases of abdominal aortic aneurysm with hostile neck anatomy. Technological advances have led to the development of EVAR devices with some of the properties of stent-grafts, such as design and texture, which can be applied in the treatment of AAA with unsuitable anatomy. Abdominal aortic aneurysm with neck dissection is rare and thus the advantages of endovascular surgery have not been clearly established due to limited evidence. We present two cases of AAA with dissection of the proximal neck who could not tolerate conventional operation. An extensor cuff was applied before deployment of a bifurcated endograft in order to augment the adhesion of the dissection flap to the aortic wall. The early outcome was uneventful without type I endoleak, stent migration, or injury of visceral arteries.

Case Presentation

Case 1

An 84-year-old man had a history of chronic obstructive pulmonary disease, peptic ulcer disease, post-partial gastrectomy, and renal insufficiency. He had symptomatic type B aortic dissection at a previous admission. CTA revealed that the primary dissecting inlet was located at the descending thoracic aorta. A 6-cm abdominal aortic aneurysm with dissection involving the aneurysm neck was also disclosed. Thoracic endovascular aneurysm repair (TEVAR) was performed with a Medtronic thoracic stent-graft (VAMC3632C150TE, Valiant Captiva, Minneapolis) to cover the primary tear site for thoracic aneurysm exclusion. We expected that the previous TEVAR would reduce the pressure of the false lumen of the abdominal aortic aneurysm. Eighteen months later, he suffered severe abdominal pain. In the emergency room, blood pressure was 90/63 mmHg before fluid resuscitation. CT orthography revealed a ruptured abdominal aortic aneurysm with the dissecting flap still present in the abdominal aneurysm neck. The operation was performed in a dedicated operating room equipped with fixed C-arm (Artis Zeego, SIEMENS, multi-axis interventional imaging system) under general anesthesia. We performed conventional open repair first, as the dissection

OPEN ACCESS

*Correspondence:

Chung-Lin Tsai, Department of Cardiovascular Surgery, Cardiovascular Center, Veterans General Hospital, 1650 Taiwan Boulevard Sect. 4, Taichung 40705, Taiwan, R.O.C, Tel: 886-4-23592525 #5063; E-mail: sevilla1001@yahoo.com.tw

Received Date: 24 Mar 2017

Accepted Date: 26 Jun 2017

Published Date: 06 Jul 2017

Citation:

Wu Y-S, Tsai C-L. Application of Extensor Cuff for Pre-Treatment of Abdominal Aortic Aneurysm with Chronic Dissection of Proximal Neck. *Clin Surg*. 2017; 2: 1541.

Copyright © 2017 Chung-Lin Tsai. This is an open access article distributed under the Creative Commons Attribution License, which permits unrestricted use, distribution, and reproduction in any medium, provided the original work is properly cited.

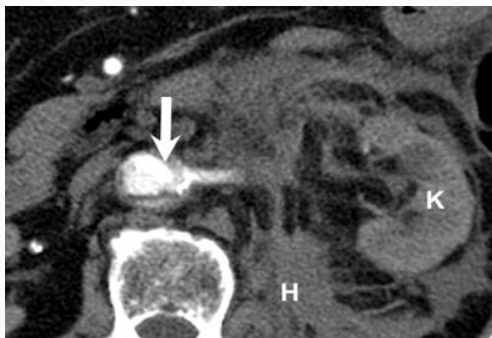


Figure 1: (A) The dissection of aortic aneurysm neck at renal artery level (Arrow); K: kidney; H: hematoma.

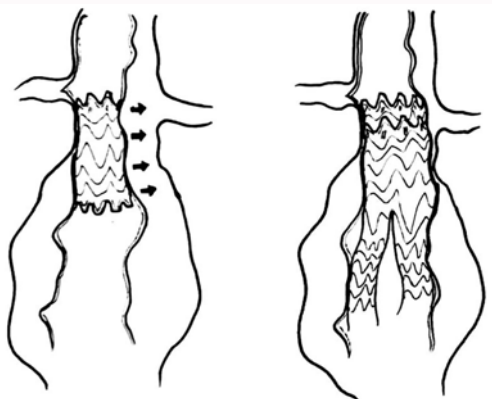


Figure 1: (B) The schematic diagram of extensor cuff as a pre-treatment procedure prior to EVAR.



Figure 1: (C) The extensor cuff (Arrow); Main body of bifurcated endograft (Arrowhead).

neck of aneurysm was not considered to be a healthy landing zone for stent-graft and repair at this site would likely have resulted in a type I endoleak. However, the attempt to approach the abdominal aorta failed because of abdominal tissue adhesion and unstable hemodynamic status. Therefore, the operation was immediately converted to an endovascular procedure. The aneurysm neck was 24 mm at the maximum diameter and 25 mm in length. The extensor cuff oversizing of 20% oversized was applied, which was similar to the recommendation for EVAR. Because the infra-renal abdominal aortic aneurysm neck was chronically dissected (Figure 1A), we implanted an extensor cuff prior to EVAR deployment, which provided a much stronger radial force to strengthen the dissecting aneurysm neck (Figure 1B). After performing bilateral femoral cutdown, an extensor cuff (Medtronic, Minneapolis, Endurant, ENCF2828C45EE) was

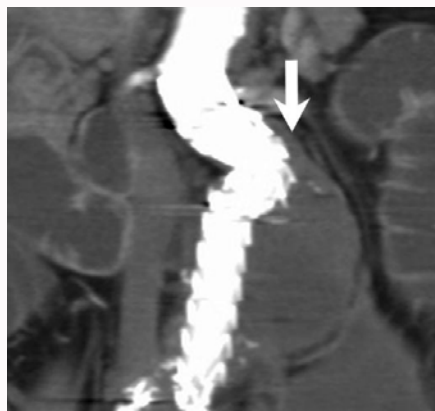


Figure 1: (D) No type I endoleak or stent migration (Arrow).

introduced via the right femoral artery and deployed to the aortic neck under fluoroscopic guidance. The Medtronic Endurant II stent-graft main body (ETBF2816C145EE18) was introduced. The right leg extension was placed (ENLW1613C95EE) subsequently. The contralateral leg (ENEW1313C80EE) was then positioned. The final angiography showed no device-related endoleaks (Figure 1C). The 6-month follow-up CT angiography showed no endoleak (Figure 1D). In addition, the dissection flap in the aneurysm neck had attached to the aortic wall.

Case 2

An 85-year-old man had acute onset of lower abdominal pain with enlargement for one day. CTA showed type B aortic dissection with infra-renal AAA measuring 6.5 cm. The dissection flap also

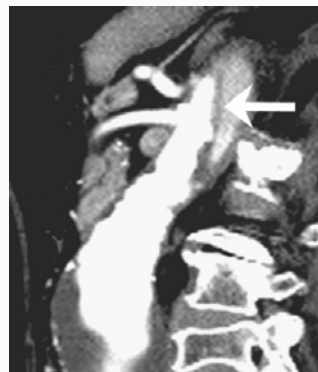

Figure 2: (A) Dissection flap involving the neck of abdominal aortic aneurysm.

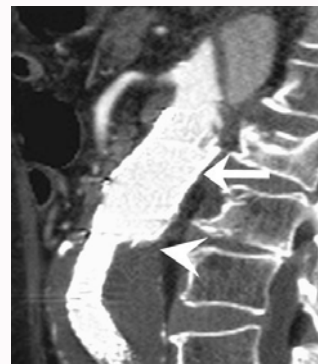


Figure 2: (B) No type IA endoleak or stent migration, the dissection flap attached to aneurysm wall (Arrow).

involved the neck of an abdominal aortic aneurysm (Figure 2A). The endovascular plan was similar to that used to treat case 1 above. We performed TEVAR and EVAR in the same operation, because the patient did not want a two-stage surgery. We used a thoracic endovascular stent (ZDEG-PT-34-26-156-PF, COOK Medical Inc., USA) first. The abdominal aortic aneurysm neck was 29 mm at the maximum diameter. We use an extensor cuff (PLA360400, W. L. Gore & Associates, USA) which covered the dissected neck of the abdominal aortic aneurysm before deployment of a standard bifurcated EVAR device. The follow-up CT scan revealed no endoleak or migration (Figure 2B).

Discussion

In EVAR, an aneurysm with a hostile neck anatomy is defined as the presence of an aneurysm neck diameter >28 mm, angulation >60, circumferential thrombus >50%, and length <10 mm [2]. Moreover, morphology unsuitable for endovascular repair, such as dissecting aneurysm neck, is also considered a type of hostile neck anatomy. The use of EVAR in hostile neck cases is especially challenging because of the increased risk of endoleak or stent migration [3]. Open repair is the standard procedure for treating dissection involving neck aneurysm, but it results in greater morbidity in some complex conditions. However, in EVAR, a structurally diseased landing zone may result in unstable landing of the stent-graft and could even lead to damage to the aortic wall [4]. An adjuvant procedure has been used for pre-treatment in cases of chronic dissection with proximal neck dissection of an abdominal aortic aneurysm [5]. Prophylactic deployment of Palmaz XL stent (Cordis Endovascular, Great Lakes, NJ, USA) in the suprarenal neck prior to the deployment of an end graft in a patient with funnel or reverse tapered neck or severe neck calcification and/or thrombus has been reported [3,6]. This technique was also used to prevent stent-graft migration and type I end leak. However, rigid features and suprarenal fixation of Palmaz XL stent may create an aortic laceration or other related aortic injuries if the landing site is fragile [7]. In our cases, an extensor cuff was considered more suitable because it may lower the risk of creating a new iatrogenic dissection owing to its larger radial force and more extensive coverage capacity. It can also allow aorta-graft apposition and exclude the dissecting false lumen in the aneurysm neck. If an

aneurysm patient with dissecting neck has much comorbidity, this treatment could provide an alternative solution. In summary, the application of an extensor cuff as a pre-treatment approach prior to EVAR in selected cases was shown to be feasible in abdominal aortic aneurysm patients with dissected aneurysm neck. Studies with a larger number of patients and long-term follow-up data are needed in order to confirm the effectiveness of this procedure.

Acknowledgement

I would like to express my appreciation to the staff at the Department of Cardiovascular Surgery's Cardiovascular Center, Taichung Veterans General Hospital, for their support and cooperation.

References

1. United Kingdom EVAR Trial Investigators; Greenhalgh RM, Brown LC, Powell JT, Thompson SG, Epstein D, Sculpher MJ. Endovascular versus Open Repair of Abdominal Aortic Aneurysm. *N Engl J Med*. 2010;362(20):1863-1.
2. Aburahma AF, Campbell JE, Mousa AY, Hass SM, Stone PA, Jain A, et al. Clinical outcomes for hostile versus favorable aortic neck anatomy in endovascular aortic aneurysm repair using modular devices. *J Vasc Surg*. 2011;54(1):13-1.
3. Farley SM, Rigberg D, Jimenez JC, Moore W, Quinones-Baldrich W. A retrospective review of Palmaz stenting of the aortic neck for endovascular aneurysm repair. *Ann Vasc Surg*. 2011;25(6):735-9.
4. Roselli EE. Thoracic endovascular aortic repair versus open surgery for type-B chronic dissection. *J Thorac Cardiovasc Surg*. 2015;149(2):S163-7.
5. Ventoruzzo G, Chisci E, Croce S, Turini F, Michelagnoli S, Bellandi G. Transrenal E-XL stenting prior to EVAR in the case of abdominal aortic aneurysm associated to proximal aortic neck dissection. *J Cardiovasc Surg (Torino)*. 2014;55(6):827-30.
6. Rajani RR, Arthurs ZM, Srivastava SD, Lyden SP, Clair DG, Eagleton MJ. Repairing immediate proximal end leaks during abdominal aortic aneurysm repair. *J Vasc Surg*. 2011;53(5):1174-7.
7. Evans J, Saba Z, Rosenfeld H, Thompson L, Williams R. Aortic laceration secondary to palmaz stent placement for treatment of superior vena cava syndrome. *Catheter Cardiovasc Interv*. 2000;49(2):160-2.