



# Anterior Sensory Myelopathy: A Retrospective Observational Case Series of an Overlooked Neurological Disorder

Jeffrey W Cozzens\* and Alex P Michael

Department of Surgery, Southern Illinois University School of Medicine, USA

## Abstract

**Background:** Individuals with cervical myelopathy can sometimes present with more subtle signs and symptoms of loss of pain and temperature sensation from compression of the anterolateral spinothalamic tract without involvement of other spinal cord tracts. It is necessary to recognize early and subtle forms of myelopathy.

**Objective:** The purpose of this report is to describe a series of patients who present with a mostly sensory cervical myelopathy from a radiographically documented spinal cord compression of the anterolateral spinothalamic tract.

**Methods:** This study is a retrospective case series. Individuals were selected who presented with radiographic documentation of cervical spinal cord compression and loss of pain and/or temperature sensation below the level of the compression. Individuals who exhibited signs of corticospinal tract dysfunction (weakness, hyperreflexia, ataxia and/or pathological spinal reflexes) were excluded.

**Results:** Seven individuals (age range 36 to 52, mean 42.4) were identified as having loss of sensation to pain and/or temperature below and contralateral to the level of anterior spinal cord compression. In all cases, the compression was due to a cervical herniated intervertebral disc. No patient had lower extremity weakness, hyperreflexia, or spasticity. No patient had spinal sensory evoked potential abnormality.

**Conclusion:** Cervical disc compression of the anterior spinal cord can lead to dysfunction of pain and temperature sensation without causing typical signs of myelopathy. Most patients who present with this myelopathy syndrome also present with pain and are likely treated with conservative medical therapy. This series highlights a very subtle form of myelopathy that is not widely recognized.

**Keywords:** Spinothalamic tract; Myelopathy; Cervical spine; Neuroanatomy; Neurophysiology

## Introduction

### Background rationale

The term “myelopathy” generally refers to any neurologic deficit related to the spinal cord. Often, it is caused by a disorder resulting in the loss of function of the long ascending and/or descending tracts of the spinal cord. In general practice, however, many physicians feel that a myelopathy is only evident when an individual has weakness, spasticity, hyperreflexia, clonus, Babinski sign or other pathological spinal reflexes referable to the level of spinal cord compression. It is recognized that a myelopathy can be either acute or chronic and can result from intra-axial disorders including degenerative disease and/or demyelination, inflammation, infection and neoplasm. Myelopathy can also result from spinal vascular disease and from intraspinal, extra-axial disorders, which may exert compressive forces on the spinal cord such as trauma, spondylosis, neoplasm, and abscess and disc disease. Of the disorders mentioned intervertebral disc disease (herniated, extruded or bulging) is the most common in the adult population, yet intervertebral disc disease as the cause of myelopathy is thought to be rare [1-3]. In recent years we have discovered that if one defines “myelopathy” as requiring weakness, spasticity, hyperreflexia, clonus, Babinski sign or other pathological spinal reflexes, 4 then perhaps it is rare in individuals with intervertebral disc disease.

On the other hand, if one recognizes that dysfunction of the spinal cord pathway mediating pain and temperature sensation - the anterolateral spinothalamic tract - is sufficient to meet the definition of “myelopathy”, and then myelopathy from intervertebral disc disease may be underreported.

## OPEN ACCESS

### \*Correspondence:

Jeffrey W Cozzens, Department of Surgery, Southern Illinois University School of Medicine, PO Box: 19680, Springfield, IL, USA, Tel: +1-217-5458863;

E-mail: [jcozzens@siumed.edu](mailto:jcozzens@siumed.edu)

Received Date: 21 Nov 2019

Accepted Date: 23 Dec 2019

Published Date: 01 Jan 2020

### Citation:

Cozzens JW, Michael AP. Anterior Sensory Myelopathy: A Retrospective Observational Case Series of an Overlooked Neurological Disorder. *Clin Surg.* 2020; 5: 2699.

Copyright © 2020 Jeffrey W

Cozzens. This is an open access article distributed under the Creative Commons Attribution License, which permits unrestricted use, distribution, and reproduction in any medium, provided the original work is properly cited.

**Table 1:** Patient Demographics.

Age (years)	Gender	Diagnosis	MRI Spinal Cord Signal Change	Level	Presenting Complaint
40	Male	Herniated Disc and Spondylosis	Myelomalacia	C4-5, C5-6	Neck pain and loss of temperature sensation in foot
36	Female	Herniated Disc	None	C4-5	Neck pain and radiculopathy
52	Female	Herniated Disc and Spondylosis	None	C5-6, C6-7	Radiculopathy
33	Male	Herniated Disc	None	C5-6	Contralateral dysesthesia
36	Female	Herniated Disc	None	C5-6	Neck pain and radiculopathy
51	Female	Herniated Disc	None	C3-4	Neck pain and radiculopathy
49	Female	Herniated Disc	None	C5-6, C6-7	Neck pain and contralateral dysesthesia

## Objectives

In this report we describe several individuals who have developed an "anterior sensory myelopathy" which manifests as a dysfunction of pain and temperature sensation in areas below the level of compression of the anterolateral spinal cord from a displaced intervertebral disc. These anterior sensory myelopathic patients do not have weakness, spasticity, pathological spinal reflexes (e.g. hyperreflexia, clonus, Hoffman's sign, Babinski sign) or abnormality of Spinal-Sensory Evoked Potential (SSEP).

## Materials and Methods

### Study design

Subjects were identified as being candidates for this study as they presented. Nevertheless, study data was collected retrospectively by chart review. Therefore, this is a retrospective observational case series.

### Setting

Individuals selected for this study presented to physicians of the Division of Neurosurgery at the Southern Illinois University School of Medicine in Springfield, Illinois (USA) from 2010 to 2017. Subjects were followed for 2 months to 6 months after presentation. Data collection and analysis was performed in January 2018.

### Participants

Subjects were eligible for this study if they had undergone clinical evaluation by the senior author (JWC) during the study period, had a focal compression of the cervical or thoracic spinal cord from a displaced intervertebral disc, and had loss of sensation to pinprick or temperature contralateral and caudal to the compression. Subjects were not chosen by diagnosis code or any other algorithm. Subjects meeting the inclusion criteria were retrospectively analyzed. Their demographic information, radiographic findings, clinic notes and hospital course were reviewed. The preoperative neurological examination was carefully reviewed and the presence or absence of signs and symptoms of radiculopathy or myelopathy were recorded, including but not limited to neck pain, weakness, paresthesia, hyperreflexia, clonus, Hoffman's sign, Babinski sign, and loss of pain, temperature or light touch sensations. In each case, neuroimaging findings were used to locate the cause of spinal cord compression along with the presence or absence of signal change in the spinal cord. Individuals with weakness in muscles innervated by the spinal cord below the level of compression, hyperreflexia, clonus, Hoffman's sign or Babinski sign were excluded. Individuals were also excluded if the record of the initial neurological exam did not include findings from testing of muscle strength, sensation or reflexes of the lower extremities.

If the patient had surgery, the surgical findings and outcome were recorded. All subjects underwent baseline Spinal Sensory Evoked Potential (SSEP) recording preoperatively and continuous monitoring intraoperatively. A clinical neurologist assessed these recordings and any changes were noted.

### Variables

This was an observational study of a single cohort with the intention of describing a syndrome. Every subject in this study underwent the appropriate intervention as indicated. As it turned out, in each case this was surgery for an anterior cervical discectomy and fusion and therefore there is no variability to report.

### Data sources

Data was obtained from medical records from the outpatient clinic and hospital visits.

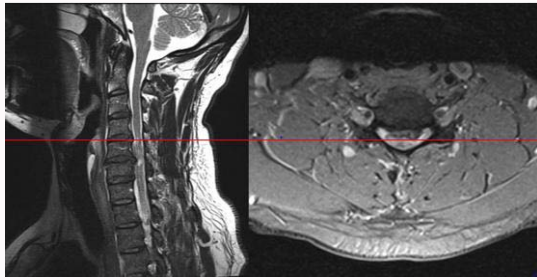
### Bias

Individuals with incomplete medical records regarding initial history and neurological exam were excluded. It is possible that some individuals could have been included if these records were complete.

This study was approved by the Springfield Committee for Research Involving Human Subjects (SCRIHS), study number 16-582, reference number 013186.

## Results/Summary of Cases

Between 2010 and 2017, seven patients at our institution met study criteria for inclusion in this series. There were two males and five females with a mean age of 42.4 years (range 33 to 52 years). The most common pathological diagnosis that was found in all seven patients was a unilateral herniated cervical intervertebral disc compressing the anterior spinal cord. Two of the seven patients were found to have also had spondylosis accompanying herniated intervertebral discs. No patient was found to have ossification of the ligamentum flavum, hypertrophy of the Posterior Longitudinal Ligament (PLL) or ossification of the PLL. The level of spinal cord compression in all patients was found to be in the cervical spine. One patient was found to have cord signal abnormality on T2 weighted MR imaging. On initial clinic consultation, five patients reported cervical pain and four patients reported radicular pain. Two patients had painful numbness in the upper extremity contralateral to a unilateral cervical intervertebral disc herniation. On physical examination, all patients had decreased sensation to pinprick and temperature in the contralateral lower extremity or both lower extremities. No patient reported hand clumsiness. No patient was found to have significant ataxia, spasticity or motor weakness in the lower extremities. No patient had a deficit of position sense, vibratory sense or light touch sensation. No patient had hyperreflexia, clonus, Babinski sign or



**Figure 1:** Cervical MRI of Case 1 revealing significant herniated intervertebral disc and spondylosis at C4-5 and C5-6, worse on the left than the right with compression and distortion of the spinal cord, specifically with compression of the left anterolateral spinal cord in the area of the left lateral spinothalamic tract. Left: Sagittal T2 MRI revealed herniated intervertebral disc and spondylosis at C4-5 and C5-6. Right: Axial T2 MRI view revealing herniated intervertebral disc at C5-6 on the left compressing the anterolateral spinothalamic tract.

Hoffman’s sign. No abnormalities were found in any patients on preoperative or intraoperative SSEP.

All patients in this series underwent surgical intervention receiving an anterior cervical discectomy and fusion with Polyether Ether Ketone (PEEK) intervertebral graft and anterior titanium plates and screws. See Table 1 for further details.

Three patients are described below in detail as typical patients:

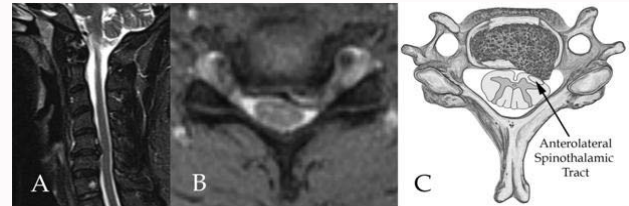
**Case 1**

A 40 year old male with a past medical history significant only for hypertension presented with numbness and dysesthesias in the right foot for the past year that had since progressed to involve the entire right leg, right scrotum, right abdomen and flank. He reportedly first noticed this change while walking barefoot in his garage and found that he could feel the coldness of the floor with his left foot but not with his right foot. He also reported numbness of the fourth and fifth digits of both hands for the past 2 years. He denied weakness or decreased sensation in the left leg. He denied bowel or bladder involvement but reported issues with erectile dysfunction.

He reported occasional neck pain but no radicular arm pain. Neurological examination revealed normal motor strength throughout all muscle groups with intact tone and no muscle atrophy in any extremity. Decreased sensation was exhibited to pin prick and temperature on the right below the T10 dermatome, both posterior and anterior. Proprioception in his toes was intact. Deep tendon reflexes were normal and symmetric in his bilateral upper and lower extremities. No Babinski sign or clonus was noted. His gait was normal. MR imaging revealed chronic myelomalacia spanning the mid C3 through C6 levels, apparently due to chronic spinal cord compression. At C4-5 and C5-6 he had significant herniated intervertebral disc and spondylosis, worse on the left with compression and distortion of the spinal cord, specifically with compression of the left anterolateral spinal cord in the area of the left anterolateral spinothalamic tract (Figure 1). Treatment consisted of an anterior cervical discectomy and fusion of C4-5 and C5-6 with PEEK allograft and titanium plates. At surgery, the intra-operative SSEP was normal before, during and after decompression. At six-month follow-up, the patient continued to have right-sided dysesthesias.

**Case 2**

A 33-year-old male who presented with a burning dysesthesia in



**Figure 2:** Cervical MRI and drawing of Case 2. A) Sagittal T2 MRI revealing herniated intervertebral disc at C5-6 which flattens the CSF signal around the cord and displaces the cord minimally posteriorly. No cord signal abnormality is noted. B) Axial T2 MRI revealing large left paracentral intervertebral disc extrusion at C5-6 on the left compressing the anterolateral spinothalamic tract. C) Drawing demonstrating the anatomy seen in B.

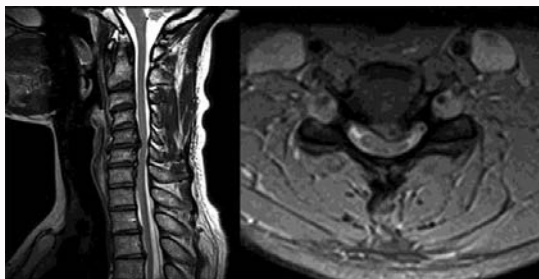
his right arm and right leg. He was wrestling with his 20 kg son on the morning of admission when he struck his head against furniture and immediately developed neck pain and burning dysesthetic pain on his right arm and right leg. He did not lose consciousness. Neurological exam revealed intact mental status and recall. He had good strength in all four extremities. He had no hyperreflexia, no clonus and no pathologic reflexes. Sensory exam of his left leg was normal. Sensory exam of his right leg revealed normal sensation to position and vibration and decreased sensation to pinprick and temperature. CT of his cervical spine showed no evidence of fracture or instability. CT of his head was normal.

MR imaging of the cervical spine revealed a large unilateral herniated intervertebral disc at C5-6 on the left with compression and distortion of the spinal cord, specifically with compression of the left anterolateral spinal cord in the area of the left anterior and lateral spinothalamic tracts (Figure 2). No cord signal abnormality was observed. The patient underwent an anterior cervical discectomy and fusion at C5-6 with PEEK allograft and titanium plates. At surgery, the intra-operative SSEP was normal before, during and after decompression. At six-month follow-up, the patient continued to have right sided dysesthesias but no longer had neck pain. There was some return of pain and temperature sensation, but this recovery was not complete.

**Case 3**

A 49-year-old woman who presented with severe pain in her neck radiating into her right shoulder with tingling and numbness in her right hand. This began in five months prior to her visit to our clinic and started after a motor vehicle accident. She reported that the pain was an unpleasant burning numbness. She did not feel that she had weakness, but she did have some clumsiness in her right hand that she felt was due to her sensory loss. She reported no weakness in her legs.

On neurological examination, she had normal strength in all muscle groups in all four extremities. All deep tendon reflexes were normal. She had no Babinski signs and no clonus. She had loss of sensation to pinprick and temperature in the right hand and right arm which was 50% of normal. She had loss of pinprick sensation and temperature sensation in her right foot which was 80% of normal. She had an MRI of her cervical spine which showed that she had a large herniated intervertebral disc at C5-6 which compressed the anterior lateral spinal cord on the left side (Figure 3). She also had a smaller herniated intervertebral disc at C6-7 which also compressed the anterior lateral spinal cord on the left side. The patient underwent an anterior cervical discectomy and fusion at C5-6 and C6-7 with PEEK allograft and titanium plates. At surgery, the intra-operative SSEP was



**Figure 3:** Cervical MRI of Case 3 revealing significant herniated intervertebral discs at C5-6 and C6-7 worse on the left than the right with compression and distortion of the spinal cord, specifically with compression of the left anterolateral spinal cord in the area of the left lateral spinothalamic tract. Left: Sagittal T2 MRI showing herniated intervertebral discs compressing the anterior spinal cord at C5-6 and C6-7. Right: Axial T2 MRI view revealing herniated intervertebral disc at C5-6 on the left compressing the anterolateral spinothalamic tract.

normal before, during and after decompression.

At three-month follow-up, the patient had complete resolution of her pain and sensory loss.

## Discussion

In our practice, most patients under the age of 55 with a herniated intervertebral cervical disc without significant spondylosis will present with arm pain. A small subset of these patients will present with arm pain and myelopathy and an even smaller subset will present with myelopathy alone. In this paper, we report a series of patients with signs and symptoms of a form of myelopathy that may not be easily recognized. Often, it is the clinician who discovers the patient's myelopathy during a careful and complete neurological exam, but sometimes subtle signs and symptoms can be overlooked.

We have used the term "anterior sensory myelopathy" to report the syndrome described in this study. This is to distinguish it from the typical type of myelopathy (cervical spondylitic myelopathy with weakness below the level of the lesion, spasticity, hyperreflexia, clonus, Babinski sign or other pathological spinal reflexes) that is familiar to most clinicians. Recently, the term "Degenerative Cervical Myelopathy" (DCM) has been proposed to describe cervical myelopathy caused by intervertebral disc disease, spondylosis and ligamentous compression of the cervical spinal cord [4,5].

Extra-axial degenerative causes of myelopathy are estimated to have an incidence and prevalence of 41 and 605 per million in North America and represent the most common cause of spinal cord dysfunction in the world [5]. In the cervical and thoracic spine, a large herniated intervertebral disc or spondylosis can compress both the nerve root and the spinal cord resulting in radiculopathy and myelopathy. The disability associated with cervical spondylitic myelopathy is commonly measured by the modified Japanese Orthopedic Association Assessment Scale (mJOA) or the Nurick Scale [6-8]. The disability associated with the form of anterior sensory myelopathy described in this study is not registered on the mJOA scale and is only a "1" on the Nurick scale (signs of spinal cord disease but no difficulty in walking). The myelopathy that we describe here is a form of anterior cord syndrome-a syndrome that can be attributable to a dysfunction of the ascending anterolateral spinothalamic tracts that transmit pain and temperature sensation. Pain and temperature is transmitted from the skin by neurons in the peripheral nerve that have cell bodies in the dorsal root ganglion. These neurons enter the

spinal cord in the dorsal root entry zone synapse with second order neurons in the substantia gelatinosa in the dorsal grey matter. The secondary neurons then course anteriorly and cross the midline and ascend the spinal cord in the contralateral anterolateral spinothalamic tract. Compression or dysfunction of this tract therefore results in a contralateral loss of pain and temperature sensation below the level of compression [8].

The fibers of the anterolateral spinothalamic tract are layered in such a way that the axons are added sequentially to the inner portion of the tract as the spinal cord ascends in the cephalad direction. Thus, in the cervical anterolateral spinothalamic tract, axons from the sacral level are most superficial followed by axons from the lumbar and then thoracic regions. The deepest layer contains axons from the cervical region. This sequential layering of axons in the anterolateral spinothalamic tract can sometimes lead to a "false localization" of the level of an anterolateral extra-axial compressive lesion when that lesion only affects the more superficial axons. For example, it is not unusual to find patients with a T10 pain sensory level with normal thoracic and lumbar neuroimages and a cervical MRI revealing a contralateral extra-axial compression of the anterolateral spinal cord from a herniated cervical intervertebral disc or metastatic tumor [10].

Reports and discussions of cervical myelopathy from extra-axial degenerative disease of the spinal column almost always focus on cervical spondylosis being the causative pathology and, in these reports; the myelopathic syndrome almost always includes weakness. Crandell and Batzdorf [11] describe five general categories of cervical spondylitic myelopathy, all of which include motor weakness. Ferguson and Caplan [12] described four syndromes of cervical spondylitic myelopathy, all including weakness. Bernhardt et al. [13] described a fifth syndrome of painless weakness in the upper limbs caused by compression of the anterior horns of the gray matter of the spinal cord. They called this syndrome the "anterior syndrome". This is not the syndrome that we describe in this report. Our patients had loss of pain and temperature sensation in the lower extremity contralateral to the spinal cord compression and no weakness.

In our series, no patient had objective finding of motor weakness below the level of compression or pathologic spinal reflexes. The function of the dorsal columns of the spinal cord was objectively tested by examining for fine sensation and vibration and was further assessed with SSEP. No patient had objective changes in fine touch or vibrational sense and no abnormal SSEPs were recorded. It is generally recognized that the SSEP signal is mostly from the rapid conducting sensory pathways in the dorsal columns [14-16]. Many of the patients in this series also presented with arm pain which ultimately was found to be a radiculopathy or contralateral dysesthesia. In general, most patients who have pain as well as myelopathy will focus on the pain and not complain about the symptoms of myelopathy, confounding the diagnosis. In our series, radicular pain and or contralateral dysesthesia was the most common chief complaint that prompted patients to seek medical attention. Only one patient presented with contralateral lower extremity loss of temperature sensation as the main complaint. Two patients presented with arm pain contralateral (but not ipsilateral) to a unilateral cervical intervertebral disc herniation. Both reported that their pain was an unpleasant burning numbness and not a sharp pain. This burning numbness is typical of dysesthesia and is distinct from sharp radicular pain. Dysesthesia has many causes, but one cause is myelopathy.

In clinical practice, cervical radiculopathy may be first managed

medically as it is due to nerve root irritation and thought to resolve over time regardless of surgical intervention [17]. It is important to distinguish myelopathy from radiculopathy because the nerves involved with radicular pain and weakness are more likely to recover following treatment, but those in the spinal cord might not [18]. Myelopathy on the other hand, involves dysfunction of the spinal cord. There are some reports that suggest that milder forms of myelopathy can be treated with non-operative therapies [19]. When these conservative measures fail, surgical intervention is indicated to prevent further damage and symptom progression. Patients with traditional and more severe forms of myelopathy that include weakness, spasticity and pathological reflexes can either deteriorate without surgery, or sometimes stabilize but rarely improve. A recent systematic review reported expert consensus that progression can either be slow with stepwise decline (class III evidence) or a long period of quiescence [20]. There is therefore some urgency to treat myelopathy so as to prevent further unrecoverable damage. Radiographic findings also are an important component in determining surgical candidacy. Cord signal change on T2 MRI indicates edema or myelomalacia and is often helpful in deciding on operative intervention. Cord signal change though has been found to poorly correlate with neurological examination [21,22]. It should be noted that only one patient in this series was found to have myelomalacia.

The cause of myelopathy for all patients in this study included but was not limited to herniated cervical intervertebral disc. Most causes of herniated cervical intervertebral disc are due to degenerative intervertebral disc disease though rarely trauma is the cause [23]. It has been shown that degenerative intervertebral disc disease generally precedes the onset of osteophytosis [24,25]. We can therefore postulate that myelopathy isolated to anterolateral spinothalamic tract compression due to degenerative cervical intervertebral disc disease may progress over time to further degeneration and compression of nearby corticospinal tracts leading to a more common myelopathic signs of weakness, spasticity, hyperreflexia, clonus, Babinski sign or other pathological spinal reflexes. This postulation is further supported by the finding that the age of the patients in our study was relatively young (42.4 years) as compared to previous studies on cervical myelopathy in which spondylitic change is the major pathological entity [1,5,20,24-32].

## Conclusion

It is important that clinicians be aware that cervical myelopathy may present without the typical signs and symptoms of corticospinal tract compression (weakness below the level of the lesion, spasticity, hyperreflexia, clonus, Babinski sign or other pathological spinal reflexes). Individuals can have a myelopathy with anterior spinal symptoms of decreased pain and/or temperature sensation only. The sole finding of sensory myelopathy appears to be a less common manifestation of cervical myelopathy and appears to most commonly result from compression of a herniated cervical intervertebral disc to the anterolateral spinal cord. We emphasize the importance of examination of the lower extremities in patients with cervical intervertebral disc disease and especially a sensory exam of those extremities to assess pain and temperature sensation. This is difficult to perform in the average clinic session, but we feel a full lower extremity sensory exam is important when presented with a patient with a large herniated cervical intervertebral disc.

Recognition of this syndrome is important because of the timing

of surgery. In the United States, third-party payers often insist that patients with cervical radiculopathy from herniated intervertebral disc or spondylosis undergo a trial of conservative or non-operative therapy before they have decompressive surgery. Patients suffering from a myelopathy should not wait for decompressive surgery so as to prevent further damage to the long fiber tracts in the spinal cord. If clinicians require weakness, spasticity, hyperreflexia, clonus and pathological reflexes for the diagnosis of myelopathy, many patients with myelopathy solely involving the anterolateral spinothalamic tract will be missed or have delay in treatment. At this time, more research should be undertaken to examine the natural course of pure anterior sensory myelopathy and progression of myelopathic symptoms.

## References

1. Kim HJ, Tetreault LA, Massicotte EM, Arnold PM, Skelly AC, Brodt ED, et al. Differential diagnosis for cervical spondylotic myelopathy: literature review. *Spine*. 2013;38(22 Suppl 1):S78-88.
2. Nouri A, Martin AR, Tetreault L, Nater A, Kato S, Nakashima H, et al. MRI analysis of the combined prospectively collected AOSpine North America and international data: the prevalence and spectrum of pathologies in a global cohort of patients with degenerative cervical myelopathy. *Spine (Phila Pa 1976)*. 2017;42(14):1058-67.
3. Yamaguchi S, Mitsuhashi T, Abiko M, Takeda M, Kurisu K. Epidemiology and overview of the clinical spectrum of degenerative cervical myelopathy. *Neurosurg Clin N Am*. 2018;29(1):1-12.
4. Akter F, Kotter M. Pathobiology of degenerative cervical myelopathy. *Neurosurg Clin N Am*. 2018;29(1):13-9.
5. Nouri A, Tetreault L, Singh A, Karadimas SK, Fehlings MG. Degenerative cervical myelopathy: Epidemiology, genetics, and pathogenesis. *Spine (Phila Pa 1976)*. 2015;40(12):E675-93.
6. Benzel EC, Lancon J, Kesterson L, Hadden T. Cervical laminectomy and dentate ligament section for cervical spondylotic myelopathy. *J Spinal Disord*. 1991;4(3):286-95.
7. Matz PG, Anderson PA, Holly LT, Groff MW, Heary RF, Kaiser MG, et al. The natural history of cervical spondylotic myelopathy. *J Neurosurg Spine*. 2009;11(2):104-11.
8. Nurick S. The pathogenesis of the spinal cord disorder associated with cervical spondylosis. *Brain*. 1972;95(1):87-100.
9. Snell RS. *Clinical Neuroanatomy*. 7<sup>th</sup> ed. Philadelphia. 2010:132-85.
10. Hellmann MA, Djaldetti R, Luckman J, Dabby R. Thoracic sensory level as a false localizing sign in cervical spinal cord and brain lesions. *Clin Neurol Neurosurg*. 2013;115(1):54-6.
11. Crandall PH, Batzdorf U. Cervical spondylotic myelopathy. *J Neurosurg*. 1966;25(1):57-66.
12. Ferguson RJ, Caplan LR. Cervical spondylotic myelopathy. *Neurol Clin*. 1985;3(2):373-82.
13. Bernhardt M, Hynes RA, Blume HW, White AA. Cervical spondylotic myelopathy. *J Bone Joint Surg Am*. 1993;75(1):119-28.
14. Curt A, Ellaway PH. Clinical neurophysiology in the prognosis and monitoring of traumatic spinal cord injury. *Handb Clin Neurol*. 2012;109:63-75.
15. Hurlbert RJ, Fehlings MG, Moncada MS. Use of sensory-evoked potentials recorded from the human occiput for intraoperative physiologic monitoring of the spinal cord. *Spine (Phila Pa 1976)*. 1995;20(21):2318-27.
16. Lee EK, Seyal M. Generators of short latency human somatosensory-evoked potentials recorded over the spine and scalp. *J Clin Neurophysiol*. 1998;15(3):227-34.
17. Wong JJ, Côté P, Quesnele JJ, Stern PJ, Mior SA. The course and prognostic

- factors of symptomatic cervical disc herniation with radiculopathy: a systematic review of the literature. *Spine J*. 2014;14(8):1781-9.
18. Jurek S, Rao RD, Harry Hz, Garfin S, Frank E, Gordon B, et al. Cervical spondylosis: Pathophysiology, natural history, and clinical syndromes of neck pain, radiculopathy, and myelopathy. Rothman-Simeone the Spine. 6<sup>th</sup> ed. Philadelphia. PA: Elsevier Saunders. 2011:684-96.
  19. Koyanagi I. Options of management of the patient with mild degenerative cervical myelopathy. *Neurosurg Clin N Am*. 2018;29(1):139-44.
  20. Holly LT, Matz PG, Anderson PA, Groff MW, Heary RF, Kaiser MG, et al. Clinical prognostic indicators of surgical outcome in cervical spondylotic myelopathy. *J Neurosurg Spine*. 2009;11(2):112-8.
  21. Martin AR, Tadokoro N, Tetreault L, Arocho-Quinones EV, Budde MD, Kurpad SN, et al. Imaging evaluation of degenerative cervical myelopathy: current state of the art and future directions. *Neurosurg Clin N Am*. 2018;29(1):33-45.
  22. Nemani VM, Kim HJ, Piyaskulkaew C, Nguyen JT, Riew KD. Correlation of cord signal change with physical examination findings in patients with cervical myelopathy. *Spine (Phila Pa 1976)*. 2015;40(1):6-10.
  23. Westrick E, Sowa G, Kang JD, Harry Hz, Garfin S, Frank E, et al. The intervertebral disc: Normal, aging and pathologic. Rothman-Simeone the Spine. 6<sup>th</sup> ed. Philadelphia. Elsevier Saunders. 2011:97-108.
  24. Badhiwala JH, Wilson JR. The natural history of degenerative cervical myelopathy. *Neurosurg Clin N Am*. 2018;29(1):21-32.
  25. Karadimas SK, Erwin WM, Ely CG, Dettori JR, Fehlings MG. Pathophysiology and natural history of cervical spondylotic myelopathy. *Spine*. 2013;38(22 Suppl 1):S21-36.
  26. Behrbalk E, Salame K, Regev GJ, Keynan O, Boszczyk B, Lidar Z. Delayed diagnosis of cervical spondylotic myelopathy by primary care physicians. *Neurosurg Focus*. 2013;35(1):E1.
  27. Dahdaleh NS, Wong AP, Smith ZA, Wong RH, Lam SK, Fessler RG. Microendoscopic decompression for cervical spondylotic myelopathy. *Neurosurg Focus*. 2013;35(1):E8.
  28. Fehlings MG, Arvin B. Surgical management of cervical degenerative disease: the evidence related to indications, impact, and outcome. *J Neurosurg Spine*. 2009;11(2):97-100.
  29. Kalsi-Ryan S, Karadimas SK, Fehlings MG. Cervical spondylotic myelopathy: the clinical phenomenon and the current pathobiology of an increasingly prevalent and devastating disorder. *Neuroscientist*. 2013;19(4):409-21.
  30. Karadimas SK, Gatzounis G, Fehlings MG. Pathobiology of cervical spondylotic myelopathy. *Eur Spine J*. 2015;24(Suppl 2):132-8.
  31. Lukasiewicz AM, Basques BA, Bohl DD, Webb ML, Samuel AM, Grauer JN. Myelopathy is associated with increased all-cause morbidity and mortality following anterior cervical discectomy and fusion: a study of 5256 patients in American College of Surgeons National Surgical Quality Improvement Program (ACS-NSQIP). *Spine (Phila Pa 1976)*. 2015;40(7):443-9.
  32. Sharifi G, Alavi E, Haddadian K, Rezaee O, Aliasgari A, Faramarzi F. Surgical outcome of anterior decompression in cervical spondylotic myelopathy in patients with less cord derangement *J Neurosurg Sci*. 2012;56(4):349-55.