



# Amyloid Goiter in Renal Transplantation and Chronic Systemic Diseases; Literature Review with Six Case Reports

Ayberk Dursun<sup>1\*</sup>, Gizem Kilinc<sup>1</sup>, Emel Ebru Pala<sup>2</sup>, Cem Karaali<sup>1</sup> and Ismail Sert<sup>1</sup>

<sup>1</sup>Department of General Surgery, Izmir Tepecik Education and Research Hospital, Turkey

<sup>2</sup>Department of Pathology, Izmir Tepecik Education and Research Hospital, Turkey

## Abstract

**Purpose:** Amyloid goiter is defined as diffuse enlargement of thyroid gland due to extensive amyloid accumulation. In this study, we aimed to emphasize the features of our patients diagnosed with amyloid goiter, which are different from the classical literature, and to review the general literature.

**Methods:** The cases diagnosed as amyloid goiter between 2005 and 2019 were analyzed retrospectively. The etiological and demographic characteristics of patients diagnosed with amyloid goiter after clinical and pathological examination were investigated. A literature review was conducted and the results were compared. In our hospital, inadequacy in diagnosing preoperative amyloid goiter was detected and the results were discussed in the multidisciplinary endocrinology council to raise awareness.

**Results:** Six patients were included in the study. All of the patients (100%) were male and their average age was 49.5. Compression symptoms occurring in five patients (83.3%) were the most common symptom. Three of six patients (50%) had hyperthyroidism and three (50%) had euthyroid disease. Secondary amyloidosis was detected in all cases. Three patients (50%) had kidney transplants history for various reasons. The current study differs from the literature due to the fact that all patients are male and hyperthyroidism is predominant.

**Conclusion:** Amyloid goiter is defined as diffuse enlargement of thyroid gland due to extensive amyloid accumulation. If possible, diagnosis of amyloid goiter should be made with FNAB, and if the complaints do not improve with symptomatic treatment, surgical treatment is the only option.

**Keywords:** Amyloid goiter; Hypertroidism; Congo red; Renal transplant; Endocrine surgery

## Introduction

Amyloidosis is defined as a heterogeneous group of diseases caused by accumulation of insoluble proteins named amyloid in the extracellular space of tissues. This amorphous protein is formed by improper folding of the fibrillary protein. Thirty-one different types of extracellular fibril proteins have been identified until now [1]. Histologically, amyloid is seen as an eosinophilic, acellular material mimicking fibrous tissues (Figure 1). Diagnosis is based on the appearance of apple-green double refraction (birefringence) under polarized light in Congo red staining (Figure 2). All amyloid types are positively stained with Congo-red and have a similar appearance under polarized light.

Amyloidosis may be systemic (primary, secondary, hemodialysis-associated), hereditary (Familial Mediterranean Fever (FMF), familial amyloidotic neuropathies, systemic senile amyloidosis) or localized (Senile cerebral, endocrine, medullary carcinoma of thyroid, Islets of Langerhans).

AL amyloid fibers accumulate in primary (systemic/generalized) amyloidosis and these amyloid proteins are known as immunoglobulin light chains. AL amyloidosis occurs as a result of Clonal proliferation of plasma cells that synthesize abnormal Ig molecules. In AL amyloidosis, light chain proteins are amorphous and produced in large quantities. They cause dysfunction of organs by accumulation. The heart, kidneys, nerves and gastrointestinal tract are the most common affected organs [2]. AL amyloidosis is usually associated with multiple myeloma, due to excessive production of immunoglobulin light chains chiefly kappa type [3].

## OPEN ACCESS

### \*Correspondence:

Ayberk Dursun, Department of General Surgery, Tepecik Education and Research Hospital, Street Number: 1140/1 Gate Number:1, Postal Code: 35180, Izmir, Turkey, Tel: 05065408006;

E-mail: dursunayberk845@gmail.com

Received Date: 03 Jul 2020

Accepted Date: 05 Aug 2020

Published Date: 24 Aug 2020

### Citation:

Dursun A, Kilinc G, Pala EE, Karaali C, Sert I. Amyloid Goiter in Renal Transplantation and Chronic Systemic Diseases; Literature Review with Six Case Reports. *Clin Surg*. 2020; 5: 2918.

**Copyright** © 2020 Ayberk Dursun. This is an open access article distributed under the Creative Commons Attribution License, which permits unrestricted use, distribution, and reproduction in any medium, provided the original work is properly cited.

In secondary amyloidosis (reactive systemic amyloidosis), Amyloid A protein (AA) accumulates in the tissues. AA is associated with chronic diseases such as, diabetes, tuberculosis, rheumatoid arthritis, inflammatory bowel disease, Chronic Obstructive Pulmonary Diseases (COPD) [2]. It may also be associated with age and may affect the spleen, liver, kidneys, adrenal glands, thyroid and lymph nodes [4]. Endocrine amyloid is the one of the localized forms of amyloidosis. Microscopic deposits of amyloid may be found in some endocrine tumors, chronic inflammatory conditions. The last form of systemic amyloidosis is hemodialysis associated amyloidosis which is characterized by A-beta 2 micro globulin accumulation due to chronic renal failure.

Hereditary type amyloidosis is rarer and has genetic transmission. They are mainly associated with amyloid deposits in the heart and can cause cardiac problems. The most common subtypes are familial forms of amyloidosis caused by transthyretin gene mutations and it is commonly associated with polyneuropathies [2,5].

Amyloid accumulation in endocrine organs is most commonly reported in thyroid, pancreas, adrenal and testicles [6]. Among these organs, the most commonly affected is reported as thyroid gland whereas adrenal gland involvement is seen extremely rare. Although amyloid accumulation in endocrine organs is common, hormone dysfunction is rare.

Amyloid accumulation in the thyroid gland can occur in 50% of primary amyloidosis and 80% of secondary amyloidosis patients [6]. Amyloid Goiter (AG) which is defined as diffuse enlargement of thyroid gland as a result of amyloid deposition and fat infiltration of the thyroid gland is rare.

In clinical practice patients may present with palpable, painless and rapidly enlarged thyroid gland which may cause progressive airway obstruction, dysphagia, and dysphonia [7].

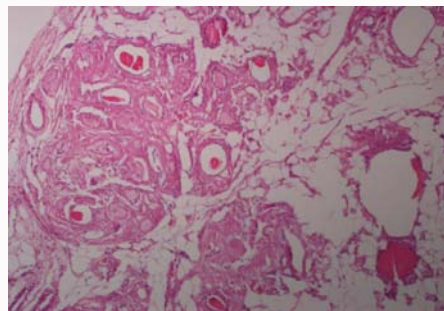
In Computer Tomography (CT) and Ultrasonography (US) images, diffuse and bilateral enlargement of the thyroid gland is often seen [8]. US images show hypoechoic masses in patients with amyloid deposition. Fat infiltration may also observe as increased signal intensity on both T1 and T2 phase images in Magnetic Resonance Imaging (MRI) [9].

Thyroidectomy is often necessary for the definitive diagnosis of amyloid goiter (Figure 3). Surgical procedures may be required either for aesthetic purposes or to relieve compression symptoms.

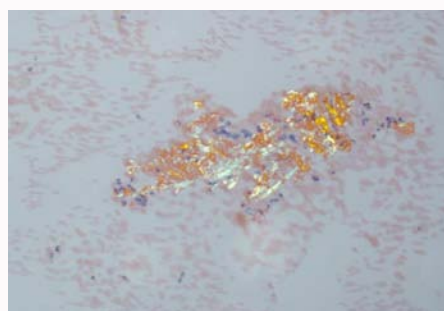
## Material and Method

All cases diagnosed as amyloid goiter between 2005 and 2019 were analyzed retrospectively. And seven patients were determined in medical reports. One case was operated in another hospital and due to lack of imaging findings and follow up data it was excluded. In all patients, amyloid accumulation in thyroid tissue was confirmed by microscopic examination. Thyromegaly was seen in symptomatic patients. Asymptomatic patients were under went radiological examination for goiter.

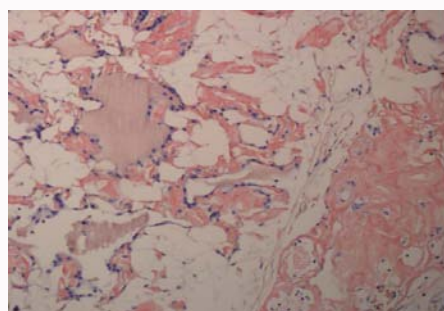
All patients were under went thyroid Fine Needle Aspiration Biopsy (FNAB) before surgery. There was no comment about amyloid deposition in cytology reports in initial evaluation, probably due to insufficient clinical information. Amyloid material can be misinterpreted as degenerated colloidal material in cytology specimens, so the clinical/radiological findings are very important.



**Figure 1:** Homogenous, eosinophilic material deposition and lipomatosis in thyroidectomy specimen (HE, 20x).



**Figure 2:** Amyloid deposition shows apple-green birefringence in polarized light (Congo-red, 20x).



**Figure 3:** Congo-red positive amyloid deposition in thyroidectomy specimen (Congo-red, 20x).

In our hospital, it was aimed to increase the rate of diagnosis without surgery and to decrease the number of operations with symptomatic treatment.

## Results

In our study all of six patients were male. The mean age of the patients was 49.5. Thyroidectomy was performed in three patients due to medically unresponsive hyperthyroidism and two patients with advanced compression symptoms. Mean weight of the thyroidectomy specimens was 151.6 grams. Secondary Amyloidosis (AA) was detected in all cases. Hyperthyroidism was seen in three patients whereas three patients were euthyroid.

Macroscopic evaluation of the thyroidectomy specimens showed yellow-gray colored, colloid poor areas consistent with amyloid and lipid deposition. Amyloid goiter was accompanied with diffuse lipomatosis in four cases. An adenomatoid nodule was also reported in three cases.

**Table 1:** Patients' etiological classifications and characteristic findings.

Patient number	Sex/age	Type of amyloidosis	Ethiology	Transplantation history	Time between transplantation and thyroidectomy (year)
1	32/male	AA	FMF	Renal transplantation	5
2	51/male	AA	Diabetes Mellitus	Renal transplantation	3
3	60/male	AA	Hypertension and Coronary Arter Disease	-	-
4	51/male	AA	Chronic Renal Failure	-	-
5	39/male	AA	FMF	Renal transplantation	12
6	64/male	AA	COPD	-	-

**Table 2:** Pathological and clinical findings of patients.

Patient number	Thyroid size	Thyroid weight	Thyroid function	FNAB result	Indication for thyroidectomy
1	Right lobe: 9 cm x 7 cm x 5 cm	242 gr	Euthyroidism	Benign	Compression symptoms
	Left lobe: 10 cm x 5 cm x 3 cm				
2	Right lobe: 9 cm x 5 cm x 3 cm	310 gr	Hyperthyroidism	Benign	Hyperthyroidism symptoms
	Left lobe: 10 cm x 6 cm x 4 cm				
3	Right lobe: 8 cm x 8 cm x 4 cm	110 gr	Hyperthyroidism	Benign	Hyperthyroidism symptoms
	Left lobe: 7 cm x 5 cm x 4 cm				
4	Right lobe: 6 cm x 5 cm x 2 cm	98 gr	Euthyroidism	Benign	Compression symptoms
	Left lobe: 5 cm x 4 cm x 1 cm				
5	Right lobe: 11 cm x 7 cm x 5 cm	130 gr	Hyperthyroidism	Benign	Compression and hyperthyroidism symptoms
	Left lobe: 10 cm x 7 cm x 4 cm				
6	Right lobe: 4 cm x 3 cm x 1 cm	20gr	Euthyroidism	Benign	Larynx carcinoma invasion

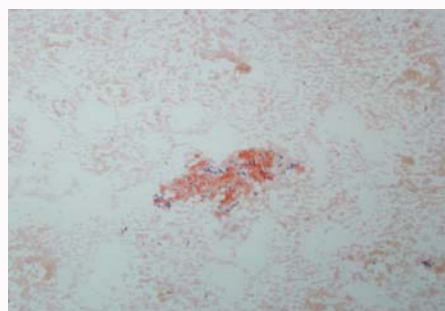
Three of the patients with renal failure had undergone kidney transplantation. All of the transplant patients became symptomatic due to amyloid goiter after transplantation. The median time to thyroidectomy after renal transplantation was 6.6 years. The causes of renal failure were FMF in two patients and diabetes mellitus in one patient.

One of the patients with incidental AG and thyrolipoma findings had been treated for pulmonary tuberculosis and COPD for many years. One patient with a history of hypertension was operated due to goiter and diagnosed as amyloid goiter after pathological examination. This patient was diagnosed as laryngeal carcinoma six years after the total thyroidectomy. In another patient who was operated for compression symptoms, the cause of amyloidosis was chronic kidney failure of unknown origin.

All six patients had the diagnosis of AG after surgery. If these patients were diagnosed with FNBA, symptomatic treatment could be tried. This situation was presented to the members of the thyroid disease's council held regularly in our hospital and attention was drawn to this issue. Samples of the patients taken before surgery with FNBA were re-examined by pathologists. In the second evaluation of the cytology materials by clinical information, we noticed amyloid fragments in three cases (Figure 4).

## Discussion

Amyloid goiter is defined as diffuse enlargement of thyroid gland due to extensive amyloid accumulation. Amyloid deposition in the thyroid gland is accompanied by variable amount of fat accumulation. Fat-containing thyroid lesions are rare because fatty tissue is uncommon within the thyroid gland. In the normal thyroid gland few adipocytes may be found near the capsule and perivascular location. Fat accumulation in amyloid goiter can be explained by metaplastic process secondary to hypoxia caused by the destruction of capillaries

**Figure 4:** Congo-red positive material in thyroid fine needle aspiration cytology (Congo-red, 10x).

and thyroid follicles due to amyloid accumulation. The most common fat-containing lesion of the thyroid gland is thyrolipoma [10]. In our series, diffuse lipomatosis was accompanied with amyloid goiter in four cases. FNAB could be performed to exclude malignant lesions in suspected cases.

In a review of thirty patients, the age of the patients was ranged from 23 to 75 and the mean age was 43.7. Twenty of them were men and ten were women [4]. In a study from Mayo Clinic; Law et al. reported five cases (two males and three females) with a mean age of 57.2 [11]. In our study all of six patients were male and the mean age of the patients was 49.5.

Amyloid goiter is more common in patients with secondary amyloidosis [12]. Autopsy studies showed amyloid deposition in thyroid in 30% to 80% of patients with systemic amyloidosis [13]. AG seen only 0.04% of patients with primary amyloidosis and 0.27% of patients with familial Mediterranean fever [9]. A primary amyloid goiter localized only to the thyroid gland is much rarer. For example, Joung et al. [14] reported a case of localized primary amyloid goiter

presented with subclinical hypothyroidism in a patient without any chronic disease and systemic amyloidosis, causing dysphagia and dyspnea during exercise by rapidly growing and mimicking anaplastic carcinoma.

The most devastating complication of FMF is amyloidosis. In these patients AA-type amyloid can accumulate in any organ or tissue, but especially in the kidneys. Delayed diagnosis or inadequate treatment of colchicine accelerates amyloid deposition [15]. In our study; FMF was the cause of renal failure in two of the patients. Secondary amyloidosis is rare in Ulcerative Colitis (UC) and Crohn's diseases and amyloid goiter is less common in patients with UC. The incidence of secondary amyloidosis in patients with Crohn's disease has been reported between 0.5% to 8% [16]. Systemic amyloidosis may occur in patients with chronic renal failure. Beta-2 microglobulin deposits accumulate in patients receiving hemodialysis or peritoneal dialysis for more than five years. This is called dialysis-associated amyloidosis and is usually seen around the joints. Although this substance is normally filtered by the kidneys, it cannot be removed by dialysis membranes [17]. Although systemic amyloidosis secondary to chronic inflammatory is seen common in the aetiology of amyloid goiter, rheumatoid arthritis is reported much rare as a cause in the literature [18]. Ashby et al. [19] reported the hypertension as a pathogen which increases Amyloid- $\beta$  ( $A\beta$ ) accumulation and causes Alzheimer's disease.

The most common tumoral cause of amyloid deposition in the thyroid gland is medullary thyroid carcinoma [20]. On the other hand, amyloid accumulation is also reported in papillary thyroid cancer cases [12]. In literature; massive amyloid deposition in the parathyroid gland due to amyloidosis has been reported in a patient with multiple myeloma. This histopathological finding should be taken into consideration especially in intraoperative frozen studies due to this histopathologic finding is also common in medullary thyroid cancer [20].

However, in contrast to malignant thyroid tumors, which are usually a unilateral disease, AG affects the thyroid bilaterally and extensively. This feature is important in the differentiation of amyloid accumulation in the thyroid gland secondary to malignancy and AG secondary to systemic amyloidosis [4,20]. Amyloid deposition is a characteristic histopathological feature in Medullary Thyroid Cancer (MTC) and needs to be distinguished from other causes of benign and malignant amyloid deposition.

Erickson et al. [21] found a new mass spectrometer-based proteomic analysis to detect specific amyloid-related proteins in MTC and presented a fast, highly specific and sensitive method for identifying specific amyloid type in these endocrine tumors. This approach can also allow the classification of different endocrine amyloid forms present in neuroendocrine tumors.

In literature; most of the AG patients were euthyroid, but patients with hyperthyroidism and hypothyroidism have also been reported [4,18,22]. Thyroid function should be evaluated regularly in the follow-up of patients with systemic amyloidosis. In a study of patients with secondary amyloidosis, nine (90%) of ten patients with AG diagnosed with amyloid goiter were diagnosed with five hypothyroidisms, one with hyperthyroidism, one with transient hypothyroidism, and two with low T3 syndrome [23]. In another review of 30 cases, euthyroidism in 24 cases, low T3 syndrome in four cases and hyperthyroidism in two cases were reported [4].

Since the amyloid causes dysfunction of the affected organ, the expected outcome in patients with amyloid goiter is primarily hypothyroidism [14]. Tokyol et al. declared that hyperthyroidism may be a secondary response to interstitial infiltration of the thyroid gland with amyloid deposits [22]. In a study of Mayo clinic, three of the five patients were diagnosed as hypothyroidism, one of them developed subclinical hypothyroidism after euthyroidism and one patient had hyperthyroidism [11]. In our study; three of six patients were presented with hyperthyroidism and the others were presented with euthyroidism.

In patients with dysphagia, dyspnea or hoarseness and a rapidly expanding thyroid gland, localized amyloid goiter and malignancy should be suspected, even if there is no evidence of systemic amyloidosis [14]. Priority in treatment is directed to symptoms. In the literature, a patient with AG secondary to primary systemic amyloidosis was treated with medical treatment and did not need surgical treatment due to the decrease in the size of goiter after treatment [4]. In another study, symptoms related to systemic amyloidosis including amyloid goiter and cardiac accumulation declined after transplantation.

In patients with Hereditary Transthyretin Amyloidosis (HTA), thyroid glands are one of the main target tissues. Liver transplantation prolongs these patients' survival. According to the autopsy results in a study of 101 patients with HTA the effects of liver transplantation on thyroid functions were analyzed. The amount of thyroid amyloid deposits in transplanted patients was found significantly lower than those without transplantation. According to these data; liver transplantation may prevent thyroid dysfunction in patients with HTA [24].

Renal transplantation is the recommended treatment for AA type systemic amyloidosis [25]. Studies have been reported that regular medical treatment alleviates the symptoms of AG in FMF patients [4]. Total or subtotal thyroidectomy should be performed as the definitive treatment method when compression symptoms develop or no response to medical treatment is achieved.

## Conclusion

Amyloid goiter should be considered in all patients who develop bilateral diffuse thyromegaly within months or years with a history of chronic inflammatory disease. FNAB is very important in the diagnosis of amyloid goiter. Thyroidectomy is the only definitive treatment modality recommended when compression symptoms develop. All of the patients in our study differ from the literature in terms of being male and the predominance of hyperthyroidism clinical symptoms. From the view of pathology, if there is chronic inflammatory disease, hereditary disease in clinical history and we notice eosinophilic, acellular, amorphous material in thyroid cytology, we should stain Congo-red to exclude amyloid deposition. Also, we must be aware of amyloid deposition due to medullary carcinoma and exclude this entity by cellular morphology.

## References

1. Sipe JD, Benson MD, Buxbaum JN, Ikeda S, Merlini G, Saraiva MJM, et al. Proteine delle fibrille amiloidi e classificazione clinica dell'amiloidosi. *Amiloide*. 2014;21(4):221-4.
2. Cannizzaro MA, Lo Bianco S, Saliba W, D'Errico S, Pennetti Pennella F, Buttafuoco G, et al. A rare case of primary thyroid amyloidosis. *Int J Surg Case Rep*. 2018;53:179-81.
3. Law Jh, Dean Ds, Scheithauer B, Earnest F, Sebo TJ, Fatourech V.

- Symptomatic amyloid goiters: Report of five cases. *Thyroid*. 2013;23:1490-5.
4. Villa F, Dionigi G, Tanda ML, Rovera F, Boni L. Amyloid goiter. *Int J Surg*. 2008;6(Suppl 1):S16-8.
  5. Vanguri VK, Nosé V. Transthyretin amyloid goiter in a renal allograft recipient. *Endocr Pathol*. 2008;19(1):66-73.
  6. Verbeke N, Pirson N, Devresse A, Furnica R, Duprez T, Maiter D. Anterior hypopituitarism in a patient with amyloidosis secondary to Crohn's disease: A case report. *J Med Case Rep*. 2018;12(1):174.
  7. Jacques TA, Stearns MP. Diffuse lipomatosis of the thyroid with amyloid deposition. *J Laryngol Otol*. 2013;127(4):426-8.
  8. Aksu AO, Ozmen MN, Oguz KK, Akinci D, Yasavun U, Firat P. Diffuse fatty infiltration of the thyroid gland in amyloidosis: Sonographic, computed tomographic, and magnetic resonance imaging findings. *J Ultrasound Med*. 29:1251-5.
  9. Bakan S, Kandemirli SG, Akbas S, Cingoz M, Ozcan Guzelbey B, Kantarci F, et al. Amyloid goiter: A diagnosis to consider in diffuse fatty infiltration of the thyroid. *J Ultrasound Med*. 2017;36(5):1045-9.
  10. Ishida M, Kashu I, Morisaki T, Takenobu M, Moritani S, Uemura Y, et al. Thyroliomatosis: A case report with review of the literature. *Mol Clin Oncol*. 2017;6(6):893-5.
  11. Law JH, Dean DS, Scheithauer B, Earnest F, Sebo TJ, Fatourech V. Symptomatic amyloid goiters: Report of five cases. *Thyroid*. 2013;23(11):1490-5.
  12. Pinto A, Nosé V. Localized amyloid in thyroid: Are we missing it? *Adv Anat Pathol*. 2013;20(1):61-7.
  13. Ozdemir D, Dagdelen S, Erbas T. Endocrine involvement in systemic amyloidosis. *Endocr Pract*. 2010;16:1056-63.
  14. Joung KH, Park JY, Kim KS, Koo BS. Primary amyloid goiter mimicking rapid growing thyroid malignancy. *Eur Arch Otorhinolaryngol*. 2014;271(2):417-20.
  15. Emeksiz H, Bakkaloglu S, Camurdan O, Boyraz M, Soylemezoglu O, Hasanoglu E, et al. Acute adrenal crisis mimicking familial Mediterranean fever attack in a renal transplant FMF patient with amyloid goiter. *Rheumatol Int*. 2010;30(12):1647-9.
  16. Basturk T, Ozagari A, Ozturk T, Kusaslan R, Unsal A. Crohn's disease and secondary amyloidosis: Early complication? A case report and review of the literature. *J Ren Care*. 2009;35:147-50.
  17. Stankovic K, Gateau G. Amyloidosis AA. *Nephrologie et Therapeutique*. 2008;4(4):281-7.
  18. Uzum G, Kaya FO, Uzum AK, Kucukyilmaz M, Gunes ME, Duzkoylu Y, et al. Amyloid goiter associated with amyloidosis secondary to rheumatoid arthritis. *Case Rep Med*. 2013;2013:792413.
  19. Ashby EL, Miners JS, Kehoe PG, Love S. Effects of hypertension and anti-hypertensive treatment on Amyloid- $\beta$  (A $\beta$ ) plaque load and A $\beta$ -synthesizing and A $\beta$ -degrading enzymes in frontal cortex. *J Alzheimers Dis*. 2016;50(4):1191-203.
  20. Hill K, Diaz J, Hagemann IS, Chernock RD. Multiple myeloma presenting as massive amyloid deposition in a parathyroid gland associated with Amyloid goiter: A medullary thyroid carcinoma mimic on intra-operative frozen section. *Head Neck Pathol*. 2018;12(2):269-73.
  21. Erickson LA, Vrana JA, Theis J, Rivera M, Lloyd RV, McPhail E, et al. Analysis of Amyloid in medullary thyroid carcinoma by mass spectrometry-based proteomic analysis. *Endocr Pathol*. 2015;26(4):291-5.
  22. Tokyol C, Demir S, Yilmaz S, Topak N, Pasali T, Polat C. Amyloid goiter with hyperthyroidism. *Endocr Pathol*. 2004;15:89-90.
  23. Kimura H, Yamashita S, Ashizawa K, Yokoyama N, Nagataki S. Thyroid dysfunction in patients with amyloid goitre. *Clin Endocrinol (Oxf)*. 1997;46(6):769-74.
  24. Huang G, Ueda M, Tasaki M, Yamashita T, Misumi Y, Masuda T, et al. Clinicopathological and biochemical findings of thyroid amyloid in hereditary transthyretin amyloidosis with and without liver transplantation. *Amyloid*. 2017;24(1):24-29.
  25. Nishikido M, Koga S, Kanetake H, Saito Y, Harada T, Taguchi T, et al. Renal transplantation in systemic amyloidosis. *Clin Transplant*. 1999;(13 Suppl 1):63-6.