



## AMACR ( $\alpha$ -Methylacyl-CoA Racemase) Expression as a Prognostic Tissue Marker in Prostatic Adenocarcinoma Sub-Saharan Experience

Ahmed Ibn Edriss Mohamed<sup>1</sup>, El Jaily Mohamed<sup>2</sup> and Mohamed El Imam Mohamed<sup>2\*</sup>

<sup>1</sup>Department of Medicine, University of El Imam EL Mahdi, Sudan

<sup>2</sup>Department of Medicine, University of Gezira, Sudan

### Abstract

**Background and Objective:** Prostate cancer is the most common cancer. Histologically 95% of prostatic cancers are adenocarcinomas. Numerous studies focused on the role of AMACR immunohistochemical expression as diagnostic marker for prostate cancer, few of them investigate the role of AMACR as prognostic marker. This study aimed to evaluate AMACR immunohistochemical expression patterns as prognostic marker for prostate cancer.

**Method:** A 100 prostate needle biopsies during 2017-2019, confirmed as adenocarcinomas by experienced histopathologist by using Hematoxylin and Eosin (H&E) stain are selected. Prostatic adenocarcinomas were graded according to the 2014 ISUP/WHO Gleason grading. Sections of 5  $\mu$ m thickness were cut, then Immunohistochemistry (IHC) was performed using monoclonal AMACR antibodies and the results were analyzed using SPSS.

**Results:** 89 (89%) of prostatic adenocarcinoma cases showed AMACR proportion score +3 staining (more than 50% cells were stained), 5 (5%) proportion score +2, 1 (1%) proportion score +1 and 5 (5%) proportion score 0. No statistical significant correlation between AMACR positivity and Gleason's score grade group (P value = 0.474). The study concluded that AMACR expression doesn't depend on tumor differentiation.

### OPEN ACCESS

#### \*Correspondence:

Mohamed El Imam Mohamed,  
Department of Medicine, University  
of Gezira, Medani, Sudan, Tel:  
+249912362293;

E-mail: mohammedimam@hotmail.com

Received Date: 30 Mar 2020

Accepted Date: 06 Apr 2020

Published Date: 09 Apr 2020

#### Citation:

Ibn Edriss Mohamed A, Mohamed  
EJ, El Imam Mohamed M. AMACR  
( $\alpha$ -Methylacyl-CoA Racemase)  
Expression as a Prognostic Tissue  
Marker in Prostatic Adenocarcinoma  
Sub-Saharan Experience. *Clin Surg*.  
2020; 5: 2796.

**Copyright** © 2020 Mohamed El Imam  
Mohamed. This is an open access  
article distributed under the Creative  
Commons Attribution License, which  
permits unrestricted use, distribution,  
and reproduction in any medium,  
provided the original work is properly  
cited.

**Keywords:** Prostate Cancer; Gleason's Score; AMACR; Sudan

### Introduction

AMACR (and  $\alpha$ -methylacyl coenzyme A racemase) (also known as p504S), is an enzyme which have in important role in  $\beta$ -oxidation of dietary branched-chain fatty acids and C27-bile acid. It catalyzes the conversion of (R)-methyl-branched-chain fatty acyl-CoA esters to their (S) Stereoisomers. Only the (S) Stereoisomers can serve as substrates for branched-chain acyl-CoA oxidase during their subsequent peroxisomal-oxidation [1]. AMACR is found in prostate tissue and in a wide variety of carcinomas (colorectal, ovarian, breast, bladder, lung, and renal cell), melanomas, and lymphomas it is very useful in prostate needle biopsies, when the differential diagnosis is carcinoma versus benign prostatic tissue, but it is not specific for prostate carcinoma in metastatic sites [2].

AMACR, antibodies have been produced and is currently available commercially for use on routine formalin-fixed, paraffin embedded tissue sections [3]. AMACR has been demonstrated to be highly over-expressed at both protein and mRNA levels in localized prostate cancer but down-regulated in metastatic androgen-independent prostate cancer suggesting a hormone-dependent expression of AMACR [4]. It is often used in combination with basal cell markers to detect invasive prostatic glands. Interestingly, AMACR is negative in benign neuroendocrine cells but positive in malignant neuroendocrine cells [5].

IHC with anti-AMACR/p504S can detect prostatic adenocarcinoma in all types of prostatic specimens be it needle biopsy or TURP or prostatectomy. AMACR is a highly sensitive (100%) marker for prostatic adenocarcinoma. AMACR also shows high specificity for prostatic adenocarcinoma as the benign prostatic tissue adjacent to carcinoma shows negative AMACR staining. Biswas and Talukdar [3] reported that immunohistochemical expression of AMACR has a very high specificity 94.74% and positive predictive value for diagnosis of prostate adenocarcinoma, but its sensitivity is

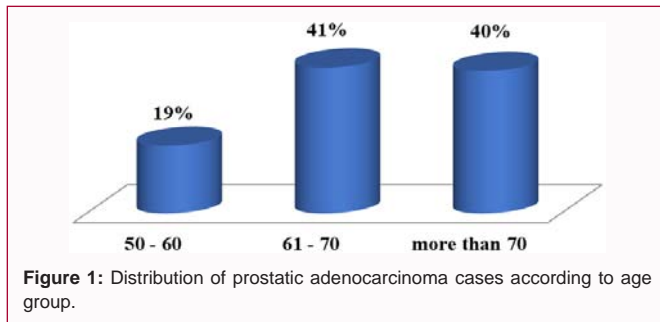


Figure 1: Distribution of prostatic adenocarcinoma cases according to age group.

Table 1: The frequency of prostatic adenocarcinoma (case) according to the Gleason grade group.

Grade group	Frequency	Percent %
1	5	5
2	21	21
3	28	28
4	22	22
5	24	24
Total	100	100

slightly lower 88.24 %.

## Methodology

### Case selection

The prostatic biopsies were done according to the European Association of Urology recommendations in the Departments of Urology by consultant Urologist at different hospitals and Centers in Khartoum State and sent in 10% buffered formalin fixative filled container to Histopathology Department at El-Rahmma Diagnostic Center.

The laboratory diagnosis of prostatic needle biopsy was done by experienced histopathologist using Hematoxylin and Eosin (H&E) stain. By reviewing the medical records, clinical and laboratory information of all cases are collected. 100 prostate needle biopsies were selected for this study, and then graded according to the 2014 ISUP/WHO Gleason grading.

### Immunohistochemistry for AMACR and p63

According to the envision kit (DAKO Corp, Carpinteria, CA) AMACR was stained. Firstly, slides deparaffinized, hydrated and then treated by citrate buffer (pH 6.0) and steamed for 14 min. For blocking of endogenous peroxidase activity, slides incubated with DAKO peroxidase block for 5 min at room temperature then washed, and incubated with primary antibody (1:16,000 dilution of antiserum) overnight at 4°C. Secondary anti-rabbit antibody-coated polymer peroxidase complex was added for 30 min. Substrate/ chromogen (DAB) was added and incubated for 10 min. Slides are counterstained with Mayer’s hematoxylin for 2 min. For double labeling of AMACR and p63, the anti-p63 mouse monoclonal

antibody cocktail (1:100 dilution; Lab Vision Corp., Fremont, CA) was added after the anti-racemese antibody incubation and incubated for 45 min at room temperature. The secondary anti-rabbit and anti-mouse HRP conjugates were sequentially added, and the reaction was developed as above. Finally slides mounted using DPX.

### Evaluation of IHC

Immunostaining for p63 will interpreted as positive/negative. Positive staining was defined as positive staining of nuclei of basal cells. Positive staining was taken as evidence of benignity and negative staining of an entire suspicious focus was taken as presumptive evidence of malignancy. AMACR results were considered positive, in case of circumferential, dark, diffuse or granular, cytoplasmic or luminal staining. IHC results will considered as negative, if there was an absence of staining or if only focal weak non-circumferential fine granular staining was seen with the absence of staining in the adjacent benign glands. The brownish cytoplasmic AMACR stain for different sections will evaluated for intensity of stain and proportion of carcinoma cells stained using intensity score stated by Warrick, et al. [6]. Intensity score was rated 0 (non circumferential staining), 1+ (focal apical granular staining), 2+ (diffuse weak cytoplasmic staining), or 3+ (strong, cytoplasmic and luminal staining). Proportion was rated with respect to percentage of positively stained cells, as follows: 0 (<5% cells stained), 1+ (5% to 25% of cells stained), 2+ (26% to 50% of cell stained), 3+ (51% to 75% of cells stained), and 4+ (76% to 100% of cells stained). The intensity and proportion scores were added to give an overall score, with 7 being the highest possible. All scores >0 was considered AMACR positive [6].

### Data analysis

Data will be analyzed using IBM SPSS advanced statistics version 22 (SPSS Inc., Chicago, IL). Numerical data expressed as mean and standard deviation or median and range as appropriate. Qualitative data expressed as frequency and percentage. Chi-square test is used to examine the relation between qualitative variables. For not normally distributed quantitative data, comparisons between three groups were done using nonparametric ANOVA. The sensitivity and specificity were calculated using Receiver Operating Characteristic (ROC) curve and the Area under the Curve (AUC). P-value <0.05 is considered significant for all tests.

## Discussion

In the current study the age of patients with prostate adenocarcinoma ranged from 50 to 87 years old (Figure 1). This result is supported by study conducted by Epstein and Lotion which concluded that prostate cancer is typically a disease of men older than 50 years of age [7]. However, Huang et al. [8] noted that prostate cancer patients younger than 50 years accounted for only 0.55% of all prostate cancer cases. Recently Emiogun et al. [9] observed that the lowest age of prostate cancer patients at diagnosis was 50 years. In more details the present study clearly demonstrates that 60 % of prostate cancer cases occur at the age of 50 years old and younger than 70 years, the majority of them 41 (41%), are seen between 61

Table 2: AMACR expression in prostatic adenocarcinoma (cases) according to the Gleason score grade group.

AMACR expression	Gleason score grade group					Total	P value
	Gleason 1	Gleason 2	Gleason 3	Gleason 4	Gleason 5		
Positive	5	20	26	20	24	95	0.631
Negative	0	1	2	2	0	5	
Total	5	21	28	22	24	100	

**Table 3:** Distribution of AMACR proportion score.

AMACR proportion score	Number of cases	Percentage (%)
0	5	5%
1	1	1%
2	5	5%
3	89	89%
<b>Total</b>	<b>100</b>	<b>100%</b>

**Table 4:** Correlation of AMACR proportion score with Gleason grade/group.

Grade/group	No	AMACR proportion score				P value
		0	1+	2+	3+	
1	5	0 (0%)	0 (0%)	0 (0%)	5 (100%)	
2	21	1 (4.76%)	0 (0%)	1 (4.76%)	19 (90.48%)	0.474
3	28	2 (7.14%)	0 (0%)	0 (0%)	26 (92.86%)	
4	22	2 (9.09%)	0 (0%)	0 (0%)	20 (90.09%)	
5	24	0 (0%)	1 (4.16%)	4 (16.66%)	19 (79.18%)	

to 70 years old. These findings were in agreement with study in Nigeria by Emiogun et al. [9] in which prostate cancer cases were most commonly seen between 61 to 70 years (42.3%). Also, recent Egyptian study done by Al-Sayed et al. [10] reported that prevalence of prostate cancer is predominant between 60 to 70 years of age and represents (40%).

An important highlight of the present study is the fact that Gleason score grade group 3 is the most commonly diagnosed (28%), followed by grade group 5 and grade group 4 of disease 24% and 22% respectively (Table 1). This finding is in agreement with Okolo et al. [11] and Rathod et al. [12] studies which observed that the commonest Gleason grade was 3, and in contrast to study in Nigeria, by Oluwale et al. [13] which observed that the majority of prostate cancer cases were of Gleason score of 8 (grade group 4). On the other hand, study in Nigeria by Emiogun et al. [9] shows that grade group 5 prostate cancer is the most commonly diagnosed (37.5%). However, a study in the United States at 2003 reported that Gleason grade 3 was the commonest with an overall decline in scores from 8-10 to less than 6 in recent years [14]. A plausible explanation for the higher proportion of high-grade cancers is the socioeconomic challenging in Sudan that includes absence of low-cost screening programs, late presentation to health facilities (usually patients present at advanced stages of the malignancy), lack of follow-up, and inherent social norms and beliefs.

Out of 100 prostate adenocarcinoma cases confirmed by routine H&E, 95 (95%) showed positive AMACR staining. AMACR was significantly expressed in prostate adenocarcinoma ( $P=0.000$ ) as correlated with benign prostatic hyperplasia. The sensitivity of AMACR is 95% and specificity is 98%. This finding was in agreement with [15] who reported that only two out of 19 cases categorized as prostatic carcinoma showed negative cytoplasmic staining of AMACR. Rathod et al. [12] also found that the sensitivity and specificity of AMACR was 90% and 100% respectively with high expression in prostate cancer as compared with benign lesions of prostate ( $P<0.001$ ). AMACR is a highly specific marker for diagnosis of prostate cancer with Positive Predictive Value (PPV) 97.9%, this result agrees with [3] who found that positive predictive value of AMACR was 96.77%. Fatima et al. on 10 cases of prostate adenocarcinoma reported that the sensitivity of AMACR was 100% and specificity was 95.4%.

In present study 5 (5%) cases of prostate adenocarcinoma showed negative AMACR staining, this finding is supported by [3] study which reported that 11.7% of prostate adenocarcinoma cases were negative for AMACR staining using monoclonal anti AMACR antibody thus recommended careful examination of morphologic pattern and combination of AMACR with basal cell marker for exclusion of prostate cancer in prostate needle biopsy specimen. Rashed et al. [16] reported that some variants of prostatic adenocarcinoma can be AMACR negative; these variants include atrophic, foamy gland and pseudo hyperplastic. Shrivastava et al. [17] evaluated AMACR expression in 30 cases of prostatic adenocarcinoma using polyclonal anti AMACR antibody and reported that all the 30 cases showed positive AMACR staining with 100% sensitivity. Difference in AMACR sensitivity can be a result of using different antibodies (polyclonal and monoclonal) for detection of prostate cancer. Other factors like concentration of the primary antibody, staining technique (manual or automated) and antigen retrieval protocol can affect AMACR sensitivity.

In this study, 89 (89%) of prostatic adenocarcinoma cases showed AMACR staining in more than 50% cells this result agreed with [17] who found 26 (86.7%) of prostatic adenocarcinoma showed AMACR proportion score +3 staining (more than 50% cells were stained). No statistically significant correlation between AMACR positivity and Gleason's score grade group indicating that AMACR expression depend on tumor differentiation ( $P$  value =0.474). This finding was in agreement with studies by [17] how reported that expression of AMACR is not affected by the Gleason score of the prostatic adenocarcinoma [17]. Jain et al. 2017 also revealed no statistically significant correlation between AMACR positivity and Gleason's grade ( $P=0.75$ ) and serum PSA levels ( $P=0.856$ ).

## Conclusion

The study concluded that AMACR expression doesn't depend on tumor differentiation.

## References

1. Singh V, Manu V, Malik A, Dutta V, Mani NS, Parrikar S. Diagnostic utility of p63 and  $\alpha$ -methyl acyl Co a racemase in resolving suspicious foci in prostatic needle biopsy and transurethral resection of prostate specimens. *J Can Res Ther.* 2014;10(3):686-92.

2. Dabbs DJ. Diagnostic immunohistochemistry: Theranostic and genomic applications. 4<sup>th</sup> ed. Elsevier. United States of America. 2014. p. 735-65.
3. Biswas S, Talukdar M. Diagnostic utility of AMACR expression to differentiate prostate carcinoma from benign hyperplasia of prostate- a hospital based cross-sectional study. *J Evolution Med Dent Sci.* 2019;8(18):1435-6.
4. Kandasamy S, Pothan L, Letha V, Sankar S, Priya P, Varghese S, et al. Diagnostic utility of AMACR in prostatic carcinoma. *J Evolution Med Dent Sci.* 2017;6(35):2869-73.
5. Omar Aboumarzouk M. Blandy's Urology. 3<sup>rd</sup> ed. Hoboken, NJ: John Wiley & Sons. 2019. p. 576.
6. Warrick JI, Humphrey PA. Foamy gland carcinoma of the prostate in needle biopsy incidence, gleason grade, and comparative a-methyl acyl-coA acemase vs. ERG expression. *Am J Surg Pathol.* 2013;37(11):1709-14.
7. Epstein JI, Loton TL. The lower urinary tract and male genital system. In: Kumar V, Abbas AK, Fausto N, editors. Robbins and Cotran pathologic basis of disease. 9<sup>th</sup> ed. Philadelphia: Saunders Elsevier. 2016.
8. Huang TH, Kuo JY, Huang YH, Huang YH, Chung HJ, Huang WJS, et al. Prostate cancer in young adults seventeen-year clinical experience of a single center. *J Chin Med Assoc.* 2017;80(1):39-43.
9. Emiogun FE, Williams OO, Obafunwa JO. Epidemiology of Prostate Cancer in Nigeria: Observations at Lagos State University Teaching Hospital. *Cancer Health Disparities.* 2019.
10. Al-Sayed M I, Hussein AM, Al-Moatazbellah ME. Immunohistochemical expression of ERG and P63 in some prostatic lesions. *Egypt J Hospital Med.* 2019;74(4):942-8.
11. Okolo CA, Akinosun OM, Shittu OB, Olapade-Olaopa EO, Okeke LI, Akang EE, et al. Correlation of serum PSA and Gleason score in Nigerian Men with prostate Cancer. *Afr J Urol.* 2008;14:15-22.
12. Rathod SG, Jaiswal DG, Bindu RS. Diagnostic utility of triple antibody (AMACR, HMWCK and P63) stain in prostate neoplasm. *J Family Med Prim Care.* 2019;(8):2651-5.
13. Oluwole OP, Rafindadi AH, Shehu MS, Samaila MOA. A ten-year study of prostate cancer specimens at Ahmadu Bello University Teaching Hospital (A.B.U.T.H), Zaria, Nigeria. *Afr J Urol.* 2015;21(1):5-18.
14. Gueye SM, Zeigler-Johnson CM, Friebe T, Spangler E, Jalloh M, MacBride S, et al. Clinical characteristics of prostate cancer in African Americans, American whites, and Senegalese men. *Urology.* 2003;61(5):987-92.
15. Arthi L, Dhanalakshmi A. Expression of AMACR ( $\alpha$ -Methyl acyl CoA racemase) in Prostatic Lesion. *IOSR J Dental Med Sci (IOSR-JDMS).* 2019;18(9):43-7.
16. Rashed HE, Kateb MI, Ragab AA, Shaker SS. Evaluation of minimal prostate cancer in needle biopsy specimens using AMACR (P504S), p63 and Ki67. *Life Sci J.* 2012;9:12-21.
17. Shrivastava H, Patil SB, Rajashekar KS. Diagnostic utility of Alpha Methyl acyl CoA racemase in prostatic adenocarcinoma: An institutional experience. *Indian J Pathol Oncol.* 2019;6(3):368-371.