



Adrenal Cyst Presenting as Asymptomatic Hydatid Cyst

Fadi Rayya^{1*}, Haya Swilem², Ruba Zuhri² and Nour Seilin²

¹Department of General Surgery, Al-Assad University Hospital, Syria

²Department of Medicine, Damascus University, Syria

Abstract

Although it is possible to find hydatid cysts in any organ of the body, especially in the liver and lungs, it rarely exists in the adrenal gland. We present a rare case of left adrenal hydatid cyst in a 48-year old woman with an incidental finding and asymptomatic. Nothing was remarkable on physical examination. Routine laboratory tests showed eosinophils, Bilirubin and alkaline phosphatase in the normal range. In her medical history, she underwent spinal fusion surgery 4 months ago, during the follow up after spinal fusion surgery, a simple abdominal X-ray showed a roughly 12 cm round cyst with peripheral calcification in the left hypochondriac. She underwent surgical resection of the hydatid cyst.

Keywords: Adrenal cyste; Hydatid cyste

Introduction

Hydatid cyst is a parasitic disease caused by *Echinococcus granulosus*, there is no specific gender for the disease. It is common in the Mediterranean region, although it is still rare in the North European and American regions. There are two types of parasites in the infection, which causes different diseases, Cystic Echinococcosis (CE) that causes hydatid cysts, where most infections are usually asymptomatic, and Alveolar Echinococcosis (AE) is usually confined to animals and rare in humans which can be fatal when not treated [1]. AE poses a much greater health threat to people than CE [1]. Symptoms take two ways systemic and local symptoms and this depends on the site and organ on which cyst settles [2]. Mebendazole, Albendazole and Praziquantel may be effective in treating. Although, surgical excision of the cyst remains the treatment of choice. However, attention is still paid to this disease as a result of the direct and indirect economic costs it causes by WHO statistics [3].

OPEN ACCESS

*Correspondence:

Fadi Rayya, Department of General Surgery, University Hospital Damascus, 17-Nissan Street, Damascus, 10769, Syria, Tel: +963112126500, +963930368246;

E-mail: fadirayya@yahoo.com

Received Date: 26 Apr 2018

Accepted Date: 25 May 2018

Published Date: 06 Jun 2018

Citation:

Rayya F, Swilem H, Zuhri R, Seilin N. Adrenal Cyst Presenting as Asymptomatic Hydatid Cyst. *Clin Surg*. 2018; 3: 1978.

Copyright © 2018 Fadi Rayya. This is an open access article distributed under the Creative Commons Attribution License, which permits unrestricted use, distribution, and reproduction in any medium, provided the original work is properly cited.

Case Presentation

A 48-year-old woman with a history of spinal fusion surgery presented to our department for post-operative follow up. A simple abdominal X-ray was performed and showed a roughly 12 cm round cyst with peripheral calcification in the left hypochondriac (Figure 1). Her past medical history was notable for complete thyroidectomy 15 years ago and hemorrhoids surgery 8 years ago.

There was no history of childhood contact with animals. She denied abdominal pain, constipation, diarrhea, vomiting or weight loss. There was nothing remarkable in physical examination. Vital signs were stable.

Laboratory studies including Complete Blood Count (CBC) and biochemical profile were within normal limits.

Multi Slice Computerized Tomography scan (MSCT) of the abdomen revealed a round cyst measuring (8.2 cm × 7 cm × 8 cm) with peripheral calcification and wall thickening. It was located among stomach, pancreas and transverse colon without obvious origin (Figure 2). The cyst appeared inseparable from left adrenal gland which suggested a diagnosis of an adrenal hydatid cyst.

The patient underwent a transabdominal excision of the cyst. She was discharged from hospital 5 days after uneventful postoperative recovery. Histopathologic examination was consistent with hydatid cyst. Cyst fluid analysis showed numerous inflammatory cells without atypia or irregular mitotic activity (Figure 3).

Discussion

Adrenal cysts are uncommon; with an incidence 0.06% to 0.18% at autopsy [4]. The first adrenal hydatid cyst was described in 1670 by Greiseliuss [5]. Echinococcosis hydatid cysts account for 6%

Tables 1: Cases of cystic adrenal echinococcosis in the literature.

Author	Age/ Sex	Side	Size (cm)	Calcified enhancement	Contact with animals	Presentation	Primary or Secondary	Hormonal Studies	Management	Follow-up (months)
Elzein	44/M	R	8.5	Yes	Yes	Flank pain	P	N	Albendazole (4 weeks) then Surg.	N/E
Geramzadeh	49/F	L	8.2	Yes	N/E	Flank pain and HTN	P	N	Surg.	2
Kumar	51/F	L	N/E	No	Yes	Flank pain	P	N/E	Albendazole (4 weeks) then Laparoscopic Surg.	6
Nardi	55/M	L	6.5	No	N/E	Chronic back pain	S	N	Laparoscopic Surg.	N/E
Mohammadi	Elderly/M	L	13	cystic components	N/E	HTN	P	N	Surg. then albendazole (6 months)	10
Ruiz-Rabelo	70/F	L	12	Yes	N/E	Flank pain and fever	P	N/E	Surg.	N/E
Tazi [9]	64/M	L	14.5	cystic components	No	Flank pain, nausea, vomiting and HTN	P	N	Surg. then lbendazole (one month)	24
Akulut	64/M	R	15	Yes	N/E	Flank pain, palpitation, sweating, weight loss and nausea	S	N/E	Albendazole (2 weeks) then Surg. then lbendazole (6 weeks)	24
Aprea	78/F	R	5	No	No	Flank pain	P	N	Laparoscopic Surg.	1
Dionigi	62/F	L	3	No	N/E	Flank pain	P	N/E	Laparoscopic Surg. then lbendazole (4 weeks)	6
Tsaroucha	56/M	L	7	N/E	N/E	HTN, headaches, discomfort and nocturia	P	N/E	Surg.	12
Sallami	38/F	R	7	No	N/E	Flank pain	P	N	Surg.	6
Gurbuz	47/F	L	7.8	N/E	N/E	Flank pain	P	N/E	Surg.	N/E
Akhan	70/M	L	13	N/E	N/E	Incidental finding	S	N/E	Percutaneous treatment	57
Schoretsanitis	48/M	R	9.5	N/E	Yes	Flank Pain	P	N/E	Surg.	N/E
Fitzgerald	48/F	R	18	N/E	Yes	Flank Pain	N/E	N/E	Surg.	N/E
Safioleas	61/F	L	5.8	N/E	N/E	Flank pain, nausea, vomiting and HTN	P	N	Surg. then albendazole (6 months)	N/E
Ozarmag	54/F	R	4.5	N/E	N/E	HTN	P	H	Surg. then albendazole (6 months)	N/E
Akcay [7]	53/F	R	8	N/E	N/E	Moderate pain	P	N/E	Surg.	16
Akcay [7]	80/M	R	10	N/E	N/E	Moderate pain	S	N/E	Surg.	16
Akcay [7]	48/F	R	4.5	N/E	N/E	Incidental finding	S	N/E	Surg.	16
Akcay [7]	61/F	L	6.5	N/E	N/E	Moderate pain	P	N/E	Surg.	16
Akcay [7]	18/F	R	10	N/E	N/E	Incidental finding	S	N/E	Surg.	16
Akcay [7]	15/M	R	12	N/E	N/E	Flank pain	P	N/E	Surg.	16
Akcay [7]	18/M	L	20	N/E	N/E	Flank pain	P	N/E	Surg.	16
Akcay [7]	41/M	R	5	N/E	N/E	Moderate pain	S	N/E	Surg.	16
Akcay [7]	28/F	R	20	N/E	N/E	Incidental finding	P	N/E	Surg.	16
Present Case	48/F	L	8.2	N/E	No	Incidental finding	P	N/E	Surg.	

to 7% of all adrenal cysts [4,6,7]. There is no specific age to adrenal cysts occurrence, but they are most commonly detected in the fifth and sixth decades. They usually appear unilateral in 92% of the cases and do not show a tendency for a particular side [4,6,7]. A review of 27 cases is summed up in Table 1. The cases consisted of 12 males and 15 females (1:1), with age range 15 to 80 years (median: 48.9 years). Furthermore, 13 cases were in left side (48.14%), while 14 cases were in the right side (51.85%). The size of the cysts ranges from 3 cm to 20 cm (median: 9.4 cm). We found only six cases reported a history of

contact with animals, 4 had a history while two denied it.

Parasitic cysts affecting the adrenals are usually secondary or are part of disseminated echinococcosis. The primary hydatid disease of the adrenal gland is rare [6,7]. In our review, we found only 7 cases (26.92%) of secondary origin and 19 cases (73.08%) of primary origin. This is mostly because only the primary cysts are reported.

Abdominal hydatid cysts usually present with non-specific symptoms. Symptoms often vary due to the site, and the size of

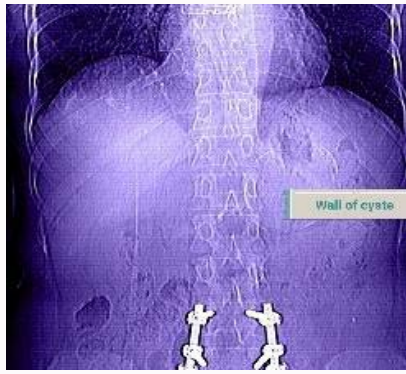


Figure 1: Abdomen X-rays demonstrates cyst with peripheral calcification in the left hypochondriac.

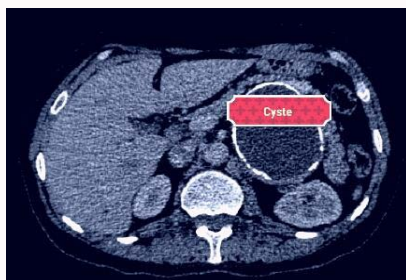

Figure 2: CT shows the adrenal cyste.

the cysts. Most adrenal hydatid cysts are incidentally detected at sonography or computed tomography [8]. Hypertension is an uncommon presentation and may result from external compression of the renal parenchyma, a state known as Page kidney [9]. In our review, 20 patients suffered from pain (74.07%), six patients from hypertension (22.22%), and four patients found incidentally (14.8%).

The diagnosis has become easy with the ultrasound and CT, with the diagnostic sensitivity ranging from 93% to 98% for ultrasonography and approximately 97% for CT [10,11]. Imaging features vary in hydatid cyst, depending on the stage of the growth of the cyst, with/without any complications and the presence of damaged tissue [10]. Based on ultrasonographic appearance, hydatid cysts are classified by WHO into five subtypes: type I is a well-defined, anechoic lesion; type II demonstrates separation of the membrane characterized as the 'water lily' sign; type III contains septa and intraluminal daughter cysts; type IV is a non-specific solid mass; and type V is a solid mass with a calcified capsule [12].

On CT, the cyst walls can range in thickness from 2 mm to 1 cm, authors report that MRI in adrenal hydatid cysts cases is more specific and useful than CT because it shows the contents of the cyst with the surrounding membrane. Calcification is seen at radiography in 20% to 30% of hydatid cysts [12], and here we noticed peripheral calcification around the cyst.

Routine laboratory tests do not show specific results, eosinophilia is present in 25% of all persons who are infected, in our case, before surgery, eosinophils was in normal range, but after the surgery the value of eosinophils decreased significantly. Bilirubin or alkaline phosphatase level may be elevated due to liver involvement. Leukocytosis may suggest infection of the cyst like our case. Laboratory tests may demonstrate anemia if there is substantial intracystic bleeding and leukocytosis if the cyst is infected. In some

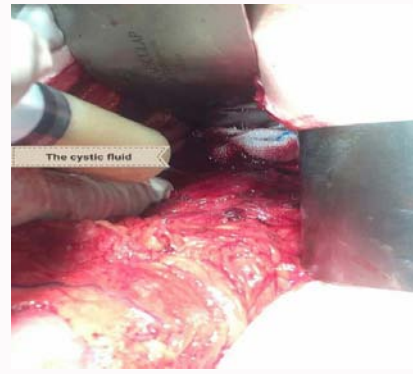


Figure 3: Intraoperative view shows the cystic fluid.

cases of hydatid cyste, eosinophilia and positive echinococcal serology may be present. Their diagnostic value is low, however, and both were negative in our case. The presence of calcification on plain abdominal films is strongly suggestive of hydatid cyste or pseudocyst.

The treatment of choice is pericystectomy of the hydatid cyste, or, if this is not possible, total excision of the adrenal gland.

Management options for hydatid cysts include surgery, percutaneous treatment, anti-infective drug treatment or observation. Normally, we do not resort to Albendazole or Mebendazole, as it is less effective in the single lesion, and can be useful in widespread diseases; on the other hand, the drug can not affect the calcification surrounding the cyst as in our patient. Also Albendazole is significantly more effective than Mebendazole in the treatment of liver cysts. All treatment choices depend on location of cysts, size and existence of calcification. Therefore, the surgery was the treatment of choice in our case, because of single lesion, surrounding calcification, large size and site. In addition, several reports confirmed the effectiveness of laparoscopic hydatid surgery.

During the follow-up after surgery in 6 months, some studies suggest a reduction in the rate of immunoglobulin (total and specific IgE, IgG, IgM, IgA), However, this follow-up is not necessary for all patients.

References

- Centers for disease control and prevention. Parasites - Echinococcosis. 2012.
- Duman K, Girgin M, Hamcan S. Uncomplicated hydatid cysts of the liver: Clinical presentation, diagnosis and treatment. *J Gastrointest Dig Syst*. 2016;6(3):430.
- Benner C, Carabin H, Sánchez-Serrano LP, Budke CM, Carmena D. Analysis of the economic impact of cystic echinococcosis in Spain. *Bull World Health Organ*. 2010;88(1):49-57.
- de Bree E, Schoretsanitis G, Melissas J, Christodoulakis M, Tsiftsis D. Cysts of the adrenal gland: Diagnosis and management. *Int Urol Nephrol*. 1998;30(4):369-76.
- Wedmid A, Palese M. Diagnosis and treatment of the adrenal cyst. *Curr Urol Rep*. 2010;11(1):44-50.
- Abeshouse GA, Goldstein RB, Abeshouse BS. Adrenal cysts; review of the literature and report of three cases. *J Urol*. 1959;81(6):711-9.
- Akçay MN, Akçay G, Balık AA, Büyük A. Hydatid cysts of the adrenal gland: Review of nine patients. *World J Surg*. 2004;28(1):97-9.
- Schoretsanitis G, de Bree E, Melissas J, Tsiftsis D. Primary hydatid cyst of

- the adrenal gland. *Scand J Urol Nephrol*. 1998;32(1):51-3.
9. Tazi F, Ahsaini M, Khalouk A, Mellas S, Stuurman-Wieringa RE, Elfassi, et al. Giant primary adrenal hydatid cyst presenting with arterial hypertension: a case report and review of the literature. *J Med Case Reports*. 2012;6:46.
 10. Turgut AT, Akhan O, Bhatt S, Dogra VS. Sonographic spectrum of hydatid disease. *Ultrasound Q*. 2008;24(1):17-29.
 11. Wegener OH, Chapter 18 in *Whole Body Computed Tomography*. 1993, Boston: Blackwell Scientific Publications.
 12. Group WIW, International classification of ultrasound images in cystic echinococcosis for application in clinical and field epidemiological settings. *Acta Tropica*. 2003;85(2):253-61.